

The background of the cover is a photograph of a heavily damaged building in Gaza. The structure is a multi-story concrete frame, mostly destroyed, with debris scattered around. In the foreground, two young boys are sitting on a pile of rubble. One boy is wearing a green shirt and the other a red and white striped shirt. The scene is lit by a bright sun, creating a hazy, orange glow. A red vertical bar is on the right side of the cover.

**Findings of an
Independent
Medical Fact-
Finding Mission**

Gaza 2014

**Jutta Bachmann
Laurel Baldwin-Ragaven
Hans Petter Hougen
Jennifer Leaning
Karen Kelly
Önder Özkalıpci
Louis Reynolds
Alicia Vacas**

Gaza, 2014
Findings of an independent
medical fact-finding mission

Jutta Bachmann
Laurel Baldwin-Ragaven
Hans Petter Hougen
Jennifer Leaning
Karen Kelly
Önder Özkalıpci
Louis Reynolds
Alicia Vacas



Physicians for Human Rights-Israel



Al Mezan Center for Human Rights-Gaza



Gaza Community Mental Health Programme



Palestinian Center for Human Rights-Gaza

Gaza, 2014

Findings of an independent medical fact-finding mission

Writing, research and images: Jutta Bachmann | Laurel Baldwin-Ragaven | Hans Petter Hougen | Jennifer Leaning | Karen Kelly | Önder Özkalipci | Louis Reynolds | Alicia Vacas

Fieldwork and research coordination: Physicians for Human Rights-Israel, Al Mezan Center for Human Rights-Gaza, Gaza Community Mental Health Programme, Palestinian Center for Human Rights-Gaza.

Editing and coordination: Miri Weingarten

Design: David Moscovitz | Studio David and Yosef

Print: Total Ayalon Graphics

Map of the Gaza Strip sourced from UN OCHA; map of Khuza'a sourced from www.openstreetmap.org.

The pictures on the cover and pages 11, 12, 26, 27, 77, 78, 97, 98, 103, 228, 230 are sourced from Activestills/ Anne Paq.

Physicians for Human Rights-Israel would like to thank the following individuals and organisations for their support, financial and otherwise, of the fact-finding mission and its report:

Marwan Diab and Rafeeq Musallam, ActiveStills/ Anne Paq, American Association for the Advancement of Science (AAAS), Science and Human Rights Program, British Shalom-Salaam Trust (UK), Christian Aid (UK), Comboni Sisters, HEKS-EPER (Switzerland), Manos Unidas (Spain), Medact (UK), Medico International (Germany), Dignity Institute (Denmark), Inge Genefke and Bent Sørensen Anti Torture Support Foundation (Denmark), IRCT (Denmark), Open Society Foundations.

The editor of this report would like to thank the following individuals for their assistance: Melanie De Campos, Indrajit Ghosh, Yosh Kosminsky, Richard Kuper, Georgia Nash, Bård Røtzer, Eddie Thomas and the two Zeinas.

The authors and editor of this report express their deep gratitude to the many witnesses, victims and survivors who shared their stories in the interests of justice.



TABLE OF CONTENTS

6	Executive Summary
11	PART A INTRODUCTION AND METHODOLOGY
13	1. Introduction
15	1.1 An independent fact-finding mission
16	1.2 Composition of the fact-finding mission
18	2. Methodology
18	2.1 Visits to the Gaza Strip, 19 August 2014-12 November 2014
20	2.2 Interviews with injured hospitalised patients, 29 July 2014-11 September 2014
22	2.3 Forensic pathology
24	2.4 Khuza'a - focus and site visit
24	2.5 Interviews with Israeli doctors
24	3. Limitations
26	4. Writing and editing of this report
27	PART B FINDINGS AND KEY CONCERNS
29	1. Types and patterns of injuries
29	1.1 Injuries resulting in death
30	1.2 Injuries in hospitalised patients
31	2. Context and causes of injuries
32	2.1 Multiple casualty events and their causes
37	2.2 'No safe place'
38	2.3 Lack of / Failure of warnings
43	3. Attacks on medical personnel and medical facilities
43	3.1 Attacks on emergency teams
48	3.2 Attacks on medical facilities
51	4. Other causes of death and injury
51	4.1 Attacks on cemeteries
52	4.2 Allegations regarding irregular weapons
54	5. Experiences of evacuation, medical management and referral
54	5.1 Evacuation in Gaza: unsafe routes
55	5.2 Medical management of the injured in Gaza: severe overload on hospitals
57	5.3 Evacuation and referral out of Gaza
62	5.4 Evacuation of Israeli soldiers during the war

63	6. Longer-term impact of the war
63	6.1 Destruction of homes and long-term displacement
66	6.2 Hazardous sites
67	6.3 Psychosocial and mental health impact of the armed conflict, with focus on minors
72	6.4 Rehabilitation in Gaza
79	PART C KHUZA'A - FOCUS AND SITE VISIT
97	PART D CONCLUSIONS AND RECOMMENDATIONS
99	1. Accountability
100	2. Health and its social determinants
103	APPENDIX I PATIENT INTERVIEWS
104	Index of interviews according to sortcode
105	1. Northern Gaza
106	Erez Area
107	Beit Hanoun
111	Beit Lahiya
118	Jabalia Refugee Camp
124	Jabalia
135	2. Gaza City
136	Al Tuffah
142	Al Shati Refugee Camp
147	Shuja'iya
154	Zaitoun
155	Al Naser
156	Gaza Beach and Port
159	Other
165	3. Middle Area (central Gaza)
166	Nusseirat Refugee Camp
167	Bureij Refugee Camp
173	Deir Al Balah
185	4. Khan Younis (southern Gaza)
186	Khan Younis
200	Khuza'a
207	5. Rafah (southern Gaza)
224	Interview questionnaire
228	APPENDIX II FORENSIC PATHOLOGY


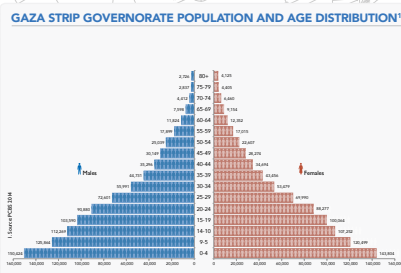


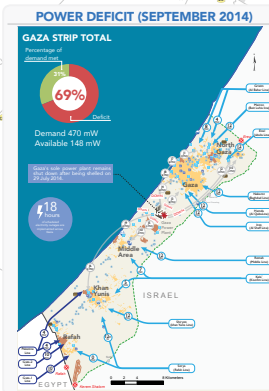
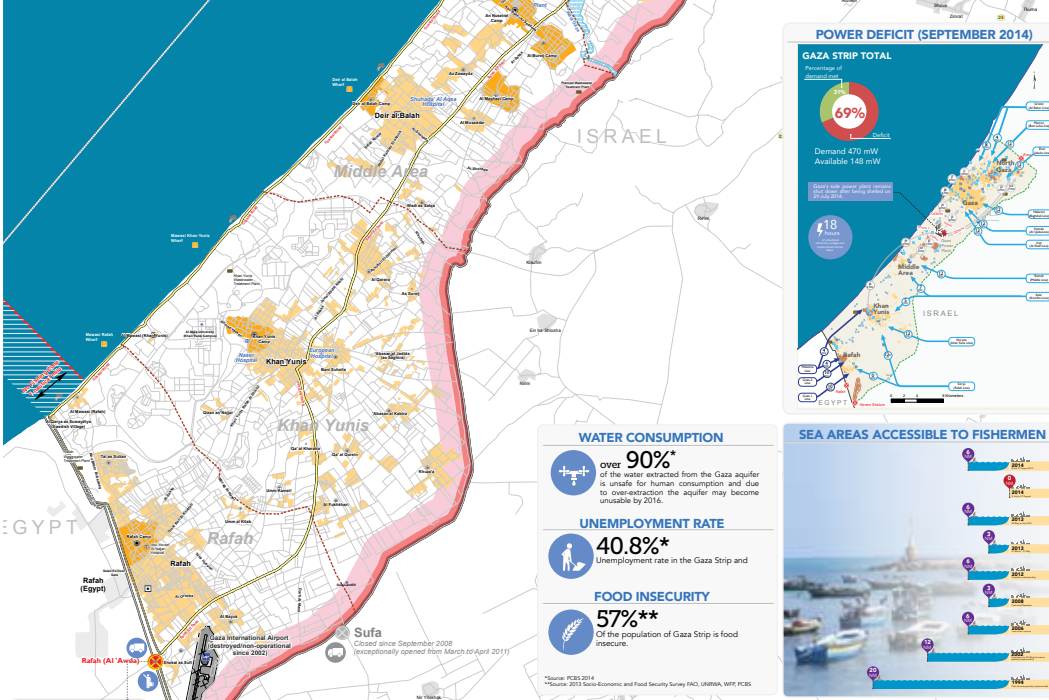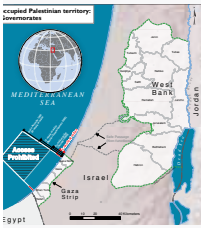

"There was a call for help in a house which had been randomly shelled at Mujama'a St, East Gaza City. It was nearly 01:00 on the last day of Ramadan. The house was in complete chaos when the team arrived. There was dense smoke everywhere and a very bad smell which hardly allowed them to breathe. I got the stretcher and the flashlight and entered the building, where I immediately saw a badly injured woman under the staircase. I took her to the ambulance and went back to the house. We managed to fit 3-6 people into the second ambulance.... What shocked me most about this incident was that I forgot the flashlight in the house and my colleague asked me to go back and get it, since we would need it later for other evacuations. When I went back, I heard the feeble cry of a small baby which I hadn't noticed before. I looked around but couldn't see anyone. Then I felt that the voice was coming from under a heap of rubble in flames. I searched in the rubble, though I felt my hands getting burnt, and finally I found a baby around one month old. I took her and ran back to the ambulance, but before I arrived she stopped breathing. I performed cardio-pulmonary resuscitation (CPR) on her, and she came back to life. I was shocked by the incident, because she could have been one of my children, and I had almost left her behind in the fire to a certain death. I still thank God that I forgot the flashlight, so I was forced to go back to the house and could find her! I found a picture of her in the hospital on the internet, and I saved it, because it is a great encouragement for me. Now I want to look for her and see her grow, to tell her how proud I am that she is alive."

(Yousef Al Kahlout, a PRCS paramedic)



GAZA STRIP

ACCESS AND MOVEMENT (GAZA CRISIS) SEPTEMBER 2014



Executive Summary

On 8 July 2014, Israel initiated a military offensive in the Gaza Strip. Although accounts vary, most estimates put the number of residents of Gaza killed in the 50-day armed conflict at over 2,100, of whom at least 70% were civilians, including over 500 children. Over 11,000 were wounded and over 100,000 made homeless. According to Israeli official accounts, 73 Israelis were killed: 67 soldiers and 6 civilians, including one child and one migrant worker. 469 soldiers and 255 civilians were wounded.

Questions arose regarding violations of international human rights and humanitarian law in the course of the conflict. In July 2014, following discussions with Al Mezan Center for Human Rights, Physicians for Human Rights-Israel (PHR-Israel) commissioned a fact-finding mission (hereafter 'FFM') to Gaza, whose aim was to gather evidence and draw preliminary conclusions regarding types, causes and patterns of injuries and attacks; attacks on medical teams and facilities; evacuation; impact of the conflict on the healthcare system; and longer-term issues including rehabilitation of the wounded, mental health, public health and displacement.

PHR-Israel recruited 8 independent international medical experts, unaffiliated with Israeli or Palestinian parties involved in the conflict: four with special expertise in the fields of forensic medicine and pathology; and four experts in emergency medicine, public health, paediatrics and paediatric intensive care, and health and human rights.

The FFM made three visits to the Gaza Strip between 19 August and 12 November 2014. Access and meetings were facilitated by PHR-Israel in partnership with local Palestinian non-governmental organisations: the Al Mezan Center for Human Rights, the Gaza Community Mental Health Programme (GCMHP) and the Palestinian Center for Human Rights in Gaza (PCHR).

Meetings and site visits were held in medical facilities and in the community, and included interviews with victims, witnesses, healthcare professionals and human rights workers, officials from the Gaza Ministries of Health and Justice, and representatives of international health organisations in Gaza and the West Bank. Wherever possible, forensic, medical and other material evidence was collected to support oral testimonies.

The FFM interviewed 68 hospitalised patients who had been injured in the course of the attacks, in different hospitals, most of them outside Gaza. See Appendix 1 for transcripts.

Findings

- The overwhelming majority of injuries causing death or requiring hospitalisation seen by the FFM were the result of explosion or crush injuries, often multiple complex injuries;
- A majority of hospitalised patients interviewed reported people being injured or killed while in, or very close to, their homes or those of relatives and neighbours;
- Numerous cases in which
 - significant numbers of casualties including members of the same family and rescuers were killed or injured in a single incident;
 - 'double tap' or multiple consecutive strikes on a single location led to multiple civilian casualties and to injuries and deaths among rescuers;
 - heavy explosives were used in residential neighbourhoods, resulting in multiple civilian casualties;
 - emergency medical evacuation was not enabled and/or in which medical teams were killed or injured in the course of evacuation of the injured (notably in Shuja'iya, Gaza City);
- At least one case in which a mine-breaching explosive device (tsefa shirion) was used in a residential street in Khuza'a, Khan Younis, causing massive destruction.
- At least one case, of Shuhada' Al Aqsa Hospital in Deir Al Balah, where several people were killed and injured in what was apparently a deliberate attack on the hospital on 21 July 2014.

An in-depth study of the town of Khuza'a suggests that:

- A convoy of hundreds of civilians came under fire while attempting to flee the town on 23 July 2014;
- A medical clinic in which civilians and injured people were sheltering after this attack was hit by missiles, causing deaths and injuries;
- A seriously injured 6-year-old child was not assisted and his evacuation was obstructed despite eye contact with troops on the ground on 24 July. He later died;
- Civilians in a house occupied by Israeli soldiers suffered abuse and ill-treatment including beatings, denial of food and water, and use as human shields. One was shot dead at close range.

In addition, the FFM examined:

- The strains placed on hospitals in Gaza during the attacks;
- Problems with referral and evacuation of patients from Gaza hospitals to hospitals outside;
- Long-term internal displacement in Gaza as a result of the partial or total destruction of about 18,000 homes;
- Long-term psychosocial and mental health damage caused by this and previous wars;
- An increased need for rehabilitation services and insufficient current resources in Gaza to meet them.

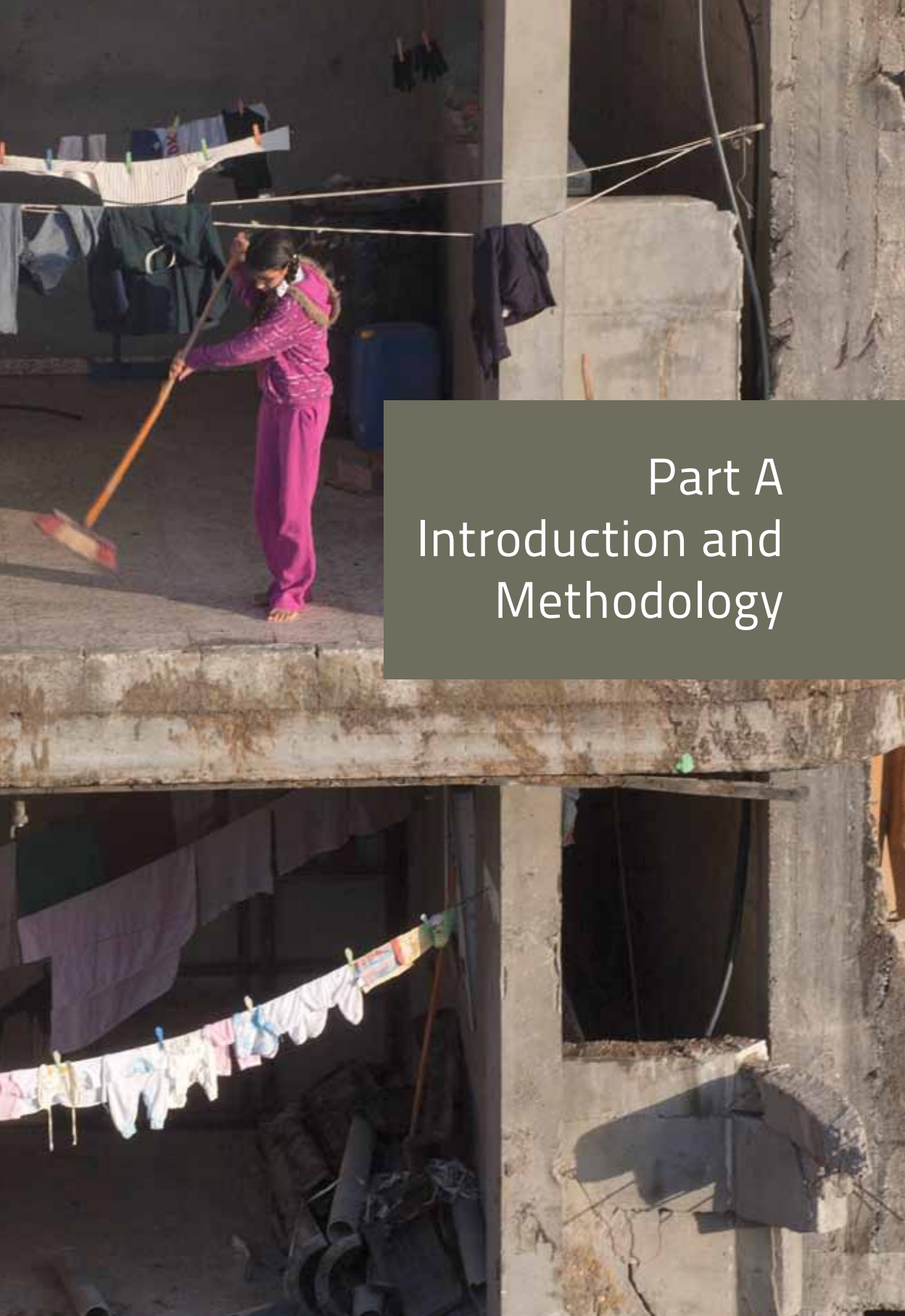
Conclusions

- The attacks were characterised by heavy and unpredictable bombardments of civilian neighbourhoods in a manner that failed to discriminate between legitimate targets and protected populations and caused widespread destruction of homes and civilian property. Such indiscriminate attacks, by aircraft, drones, artillery, tanks and gunships, were unlikely to have been the result of decisions made by individual soldiers or commanders; they must have entailed approval from top-level decision-makers in the Israeli military and/or government.
- The initiators of the attacks, despite giving some prior warnings of these attacks, failed to take the requisite precautions that would effectively enable the safe evacuation of the civilian population, including provision of safe spaces and routes. As a result, there was no guaranteed safe space in the Gaza Strip, nor were there any safe escape routes from it.
- In numerous cases double or multiple consecutive strikes on a single location led to multiple civilian casualties and to injuries and deaths among rescuers.
- Coordination of medical evacuation was often denied and many attacks on medical teams and facilities were reported. It is not clear whether such contravention of medical neutrality was the result of a policy established by senior decision-makers, a general permissive atmosphere leading to the flouting of norms, or the result of individual choices made on the ground during armed clashes.
- In Khuza'a, the reported conduct of specific troops in the area is indicative of additional serious violations of international human rights and humanitarian law.

Recommendations

The FFM

- Calls upon the UN, the EU, the US and other international actors to take steps to ensure that the governments of Israel and Egypt permit and facilitate the entry of investigative teams into Gaza, including experts in international human rights law and arms experts. This has not yet been done, months after the offensive;
- Draws attention to the independence and credibility of the local Palestinian civil society groups (Al Mezan, PCHR and GCMHP), and encourages the international community to support and recognize their efforts to collate evidence in Gaza, in order to proceed with legal and/or other remedies as well as to seek justice and/or reparations;
- Believes that the *prima facie* evidence collected and presented in this Report should be used for the purposes of legal determination of violations of international human rights and humanitarian law, whether through local or international justice mechanisms. It is willing to assist and provide evidence to any credible investigation established for this purpose, and;
- Recommends further urgent and rigorous investigation into the impact of this war, as well as the previous armed conflicts, on public health, mental health and the broader social determinants of health in Gaza. In this assessment, the implacable effects of the on-going occupation itself must be taken into account.



Part A
Introduction and
Methodology



Part A

Introduction and Methodology

1. Introduction

On 8 July 2014, Israel launched a military attack¹ on the Gaza Strip, which it termed Operation Protective Edge; its stated aim was to stop escalating rocket fire from Gaza into southern Israel.² Its broader context was a prior military operation against Hamas infrastructure in the West Bank,³ following the 12 June 2014 abduction of 3 Israeli teenagers in the occupied West Bank (declared dead on 30 June 2014), and Hamas' earlier decision to signal unity with the Fatah-led Palestinian Authority by supporting its new government inaugurated on 2 June 2014 – a decision met with hostility by the Israeli government.⁴ On 17 July 2014 the attack was expanded to a ground invasion whose stated aim was to destroy Gaza's tunnel system. After several short-lived ceasefires and repeated failure of negotiations through external brokers including Egypt and the United States, an open-ended ceasefire was finally declared on 26 August 2014.

Although accounts vary, most estimates put the number of residents of Gaza killed in the Israeli attack at over 2,100, including over 500 children. According to multiple sources at least 70% of those killed were civilians.⁵ Over 11,000 residents of Gaza, out of a total population of 1.8 million, were wounded.⁶

¹ The operation was announced on 7 Jul 2014, with airstrikes commencing shortly after midnight on 8 Jul 2014.

² See e.g., Haaretz, 7 Jul 2014 <http://www.haaretz.com/news/diplomacy-defense/1.603472> accessed 18 Nov 2014.

³ Termed 'Operation Brother's Keeper' by the Israeli army. See e.g., Haaretz, 19 Jun 2014 <http://www.haaretz.com/news/diplomacy-defense/1.599757> accessed 18 Nov 2014

⁴ See e.g. Haaretz Editorial, 2 Jun 2014 <http://www.haaretz.com/opinion/1.596570> accessed 20 Nov 2014

⁵ See e.g. UN OCHA, Gaza Emergency Situation Report as of 4 Sep 2014, available at http://www.ochaopt.org/documents/ocha_opt_sitrep_04_09_2014.pdf, accessed 18 Nov 2014.

⁶ According to a World Health Organisation (WHO)-led Health Impact Assessment published in September 2014 and referred to in this report as the Health Cluster report, as of September 2014, 2,145 deaths and 11,231 injuries were recorded among

According to Israeli official accounts, 73 Israelis were killed: 67 of these were soldiers killed within the context of fighting in Gaza⁷ and 6 were civilians, including one child and one migrant worker, killed by rocket or mortar fire into Israel. 469 Israeli soldiers were wounded. Of the 836 Israeli civilians treated by emergency services, 255 were treated for physical injuries and 581 for anxiety attacks.⁸

According to a World Health Organisation (WHO)-led health impact assessment (referred to throughout this report as 'the Health Cluster Report'), many health facilities in Gaza were damaged or completely destroyed due to either direct or indirect attack. More than 500,000 people were forced to leave their homes in Gaza and find shelter in UNRWA and governmental schools, mosques and health facilities. Thousands of Israelis living in the proximity of Gaza had to relocate as well.⁹ As of September 2014, more than 100,000 residents of Gaza remained displaced following the destruction of their homes.¹⁰

In the course of the armed conflict, allegations were made regarding the use of disproportionate force by the Israeli army, indiscriminate attacks on civilian targets, and a lack or failure of precautionary measures¹¹ Allegations made regarding the indiscriminate nature of Hamas rockets fired into Israel were easily verifiable, since the sites of strikes were immediately accessible to all. However, allegations against Israeli strategy and tactics used in its attack on Gaza have not been so readily assessable. While international journalists and volunteer medical professionals gained access to the Gaza Strip, and although local Palestinian legal experts and fieldworkers collated and analysed large amounts of evidence, external independent experts were not allowed to enter Gaza for purposes of fact-finding and documentation of evidence, either during the fighting or after the ceasefire. Delegations from both Amnesty International and Human Rights Watch were repeatedly denied entry by both the Israeli and the Egyptian administrations, as were other expert delegations. As of mid-November 2014, the Commission of Inquiry appointed by the United Nations Human Rights Council to investigate these allegations also had no access to Gaza.¹²

Palestinians in Gaza. The report is available at http://www.emro.who.int/images/stories/palestine/documents/Joint_Health_Sector_Assessment_Report_Gaza_Sept_2014-final.pdf?ua=1&ua=1&ua=1, accessed 18 Nov 2014.

⁷ See IDF Spokesperson's list of names from 31 Aug 2014, Hebrew, available at <http://www.idf.il/1133-20978-he/Dover.aspx> accessed 23 Nov 2014.

⁸ See 29 Aug 2014 summary of injuries by the Israeli ambulance service, Magen David Adom (MDA): 'During the 50 days of Operation "Protective Edge", MDA teams treated 842 civilians, including 6 who were killed by shrapnel of rockets, and another 36 who were injured by shrapnel in varying degrees, including: 10 casualties in serious condition, 6 in a moderate condition and 20 who were slightly wounded. In addition, MDA teams also treated during Operation "Protective Edge33" people who were injured by shattered glass and building debris, 18 who were injured in road traffic accidents which occurred when the sirens were heard, including 1 person in a serious condition, and the rest lightly or moderately wounded. 159 people were injured as a result of falling and trauma on the way to the shelters and 581 people suffered anxiety attacks.' Available at <http://www.mdais.com/316/7004.htm> accessed 18 Nov 2014.

⁹ Health Cluster Report p6.

¹⁰ See e.g. UN OCHA, Gaza Emergency Situation Report as of 4 Sep 2014, available at http://www.ochaopt.org/documents/ocha_opt_sitrep_04_09_2014.pdf, accessed 18 Nov 2014.

¹¹ See e.g. Amnesty International, Families under the Rubble: Israeli attacks on inhabited homes, 5 Nov 2014, available at <http://www.amnesty.org/en/library/asset/MDE15/032/2014/en/613926df-68c4-47bb-b587-00975f014e4b/mde150322014en.pdf>, accessed 18 Nov 2014.

¹² The Israeli government announced its final decision 'not to cooperate' with the Col or to allow it access via Israel on 12 Nov 2014; it stated it would cooperate with a UNSG-appointed Board of Inquiry into attacks on UN facilities, but did not specify a date for their entry. Haaretz 12 Nov 2014, <http://www.haaretz.com/.premium-1.626155>, accessed 8 Dec 2014.

1.1 An independent medical fact-finding mission

In July 2014, while the attacks were ongoing, Physicians for Human Rights-Israel (PHR-Israel), following consultations with Palestinian NGO Al Mezan Center for Human Rights, made a decision to commission a fact-finding mission (hereafter 'FFM') to Gaza. The aim of this FFM was to collect and document, wherever possible, information regarding patterns of injury and attack from witnesses and victims. In addition, potential material evidence would be documented, recovered and maintained under a strict 'chain of custody'.¹³ enabling the use of this gathered information or materials for legal or other objectives in pursuit of justice. The information and materials would be handled in a credible, objective and independent manner.

The urgency of the mission lay in the necessity of collecting evidence while still relatively undisturbed, and the events still fresh in the minds of the victims and survivors. At the time, PHR-Israel was not aware that other fact-finding teams and experts would be denied access to Gaza, making it the only such team to gain entry as of mid-November 2014. It therefore designed the mission to collect information specifically on the medical and health-related aspects of the attack, aiming to contribute this evidence to a broader range of materials collected by multiple actors on the ground.¹⁴

To this end, PHR-Israel recruited 8 independent international medical experts, who were not affiliated with either Israeli or Palestinian parties involved in the conflict. Experts were recruited in the fields of forensic pathology, emergency medicine, public health, paediatrics and paediatric intensive care, and health and human rights. Participants were chosen because of their professional expertise and their freedom from affiliation to any state or party in Israel and the occupied Palestinian territories (OPT), or to any relevant political body in any other country.

The mandate of these experts was to gather evidence on the following issues:

- Types, causes and patterns of injuries and attacks
- Attacks on medical teams and facilities
- Evacuation of civilians, the wounded and the dead
- Impact of the attack on the healthcare system
- Longer term impact of the attack on civilians, including rehabilitation of the wounded survivors, psychosocial, public health, safety and displacement issues

¹³ A legal / forensic term, referring to chronological documentation showing the seizure, custody, control, transfer, analysis, and disposition of evidence.

¹⁴ International medical professionals have been permitted entry into Gaza, but only for medical and humanitarian purposes; some UN officials whose aim is to assess damage for purposes of reconstruction have also entered Gaza.

1.2 Composition of the fact-finding mission



Jutta Bachmann, Germany (hereafter JB)¹⁵

MD (Gynecologist and Obstetrician), MSc Public Health, MSc Forensic Anthropology.

International experience: Extensive experience (15 years) in emergency contexts, public health assessments and health care provision in conflict and post-conflict contexts in various countries in the Middle

East, Asia, Africa and South America (including Colombia, Palestine, Sudan, Democratic Republic of Congo, Central African Republic, Afghanistan, Pakistan, Bangladesh, Yemen and Libya). Experience in the region includes work with ICRC and MSF.

Role in the FFM: First FFM team member; focus on forensic evidence, rehabilitation and public health.



Laurel Baldwin-Ragaven, South Africa (LBR)

Professor of Family Medicine at the University of the Witwatersrand, Johannesburg, South Africa; Honorary Professor in the School of Public Health and Family Medicine at the University of Cape Town; clinician; health and human rights expert.

International experience: Member, International Advisory Board of Physicians for Human Rights; Former chair, AAAS Committee on Scientific Freedom and Responsibility and Science and Human Rights; co-author, the International Dual Loyalty Report. Writes extensively on dual loyalty of health care workers, medical participation in torture, health sector complicity with apartheid state violence, gender-based violence, feminism and bioethics, migrant health, and training and education in health and human rights.

Role in the FFM: First FFM team member, focus on public health and human rights; psychosocial impact of the attacks; displacement and attacks on medical personnel; assisted in recruitment of experts for the fact finding mission.



Hans Petter Hougen, Denmark (HPH)

Specialist in forensic pathology and clinical forensic medicine, Professor of forensic medicine, University of Copenhagen, Chief Forensic Pathologist (Chief Medical Examiner) of East Denmark.

International experience: Forensic expert assignments for UN, OAS, ICRC and various national authorities as well as several NGOs:

Autopsy and/or exhumation experience from The Philippines, Kenya, Mexico, Kosovo, Thailand and Colombia. Examination of torture survivors in Burma, Mexico, Togo and Denmark (immigrants from several different countries). Teaching experience from Thailand, Nepal, Indonesia, Jordan, Mexico, Bolivia, Argentina, South Africa, USA and several European countries. Expert court witness experience from Denmark, Sweden, Norway, USA, England and Costa Rica.

Role in the FFM: Second FFM team member; focus on forensic evidence, attacks on medical personnel; participated in the investigation of events at Khuza'a.

¹⁵ The experts are referred to using their initials throughout this report.



Karen L. Kelly, USA (KK)

Associate Professor, MD, at East Carolina University, Brody School of Medicine, Department of Pathology and Laboratory Medicine. Over 15 years experience practicing full-time forensic and cardiovascular pathology, and teaching forensic and cardiovascular pathology to medical students, pathology residents and cardiology fellows. Member,

National Association of Medical Examiners, the American Academy of Forensic Sciences and the Society of Cardiovascular Pathology. Special interest in cause of death in pregnant women, sudden cardiac death in the young and paediatric deaths.

International experience: The FFM mission to Gaza, organized and supported by PHR-Israel, was her first exposure to human rights work. It is now her goal to become increasingly more involved in this field.

Role in the FFM: Second FFM team member; focus on forensic evidence, attacks on medical personnel; participated in the investigation of events at Khuza'a.



Jennifer Leaning, USA (JL)

Professor of health and human rights at the Harvard School of Public Health, MD, board-certified emergency physician and internist, trained also in public health, with 30 years of clinical experience and leadership roles in managing large health care delivery systems.

International experience: Human rights investigator for over 25 years in conflict and post-conflict situations in many countries in the Middle East, Asia, Africa, and Eastern and Central Europe. Founding member, Physicians for Human Rights (USA). Steering Group member, Lancet Palestine Health Alliance.

Role in the FFM: Second FFM team member; focus on public health, rehabilitation and human rights issues; participated in formulation of the patient interviews questionnaire.



Önder Özkalıpci, Switzerland (ÖÖ)

MD, forensic physician, with 20 years of experience.

International experience: Forensic expert reports provided by request from the European Court of Human Rights, African Commission for Human Rights, Inter American Commission for Human Rights, UN International Criminal Tribunal for Former Yugoslavia (ICTY) and

National Courts of Cyprus, Georgia, Sweden, Denmark, Turkey. Coordinator and co-editor of the UN *Istanbul Protocol*. Founding member of the International Forensic Expert Group Against Torture (IFEG); former medical director of the International Rehabilitation Council for Victims of Torture (IRCT) and former detention doctor for ICRC. Member of the International Academy of Forensic Medicine; International Editorial Board Member of the Journal of Forensic and Legal Medicine; Member of the Society of Forensic Physicians of Turkey.

Role in the FFM: First FFM team member; focus on forensic evidence; assisted in the planning and terms of reference of the fact-finding mission from an early stage.



Louis Reynolds, South Africa (LR)

Retired Associate Professor, Department of Paediatrics and Child Health at the University of Cape Town. More than 30 years clinical experience in general paediatrics, paediatric intensive care, pulmonology and neuromuscular disorders of childhood.

International experience: Founding member and chair of People's Health Movement, South Africa. Extensive experience of health and human rights violations under apartheid in South Africa. Special interests in child health and survival, health and human rights, and the rights of the child.

Role in the FFM: Second FFM team member; focus on paediatrics, psychosocial impact of the attacks and displacement.



Alicia Vacas, Comboni Sisters (Jerusalem) (AV)

Registered nurse and qualified international health expert.

International experience: Many years of experience as a Comboni Sister in public health settings in Egypt and the occupied Palestinian territories. Participated in a previous PHR-Israel/PMRS fact-finding mission to the Gaza Strip in 2009. Currently lives in Al-'Azariya, East Jerusalem

Role in the FFM: Member of both FFM teams; assisted with interpreting; participated in a majority of the patient interviews; travelled to Jordan to interview injured persons hospitalised there; visited Gaza a third time in November to complete missing data.

2. Methodology

Documentation of experiences and events during the armed conflict between 8 July and 26 August 2014 was collected within a health and human rights framework. In particular, the FFM teams acknowledge the principles of international humanitarian and human rights law, including the duty to protect civilians and medical personnel, vehicles and facilities, and to ensure the safe evacuation of the wounded. Documentation was collected using the following methods:

2.1 Visits to the Gaza Strip, 19 August 2014 – 12 November 2014

Entry of the FFM experts into Gaza was facilitated by PHR-Israel through official request for entry permits submitted to Israeli government ministries and the Israeli military authorities at Erez Crossing. The FFM experts entered the Gaza Strip in two teams:

First FFM team: 19-21 August¹⁶

The first FFM team, comprised of 4 experts, entered Gaza on 19 August, during a ceasefire. The ceasefire broke down several hours after their entry, but the team remained in Gaza under bombardment for two days, returning to Tel Aviv on 21 August.

¹⁶ Participants: Dr. Jutta Bachmann, Sister Alicia Vacas, Dr. Önder Özkalipci, Prof. Laurel Baldwin-Ragaven and PHR-Israel staff



Members of the second FFM team and an interpreter hold an interview with injured paramedic Akram Al Awoor at Al Quds Hospital, Gaza City. Photo by HPH, 10 Sep 2014

Second FFM team: 8-14 September¹⁷

The second FFM team, comprised of 5 experts (one of whom was also a member of the first team), entered Gaza between 8 and 14 September, after the open-ended ceasefire had begun.¹⁸

Additional visit: 11-12 November

Team member Alicia Vacas returned to the Gaza Strip to complete collection of data and interview some of the witnesses and patients a second time. Topics covered included rehabilitation of the injured and events at Khuza'a (see 2.4 below).

The FFM teams exited Gaza via the same route as they entered, at Erez Crossing. Each of the teams was briefed in PHR-Israel's offices in Jaffa before entering Gaza, and debriefed after exit by staff from the organisation.

In Gaza, meetings and access were facilitated by PHR-Israel's staff in cooperation with local Palestinian human rights and medical non-governmental organisations: the Al Mezan Center for Human Rights, the Gaza Community Mental Health Programme (GCMHP), the Palestinian Center for Human Rights in Gaza (PCHR). For interpreting purposes team member Alicia Vacas, a fluent Arabic and English speaker, was available for both FFM teams. In addition, fieldworkers of PHR-Israel, Al Mezan, PCHR, GCMHP and a professional interpreter accompanied the FFM teams to interviews.

¹⁷ Participants: Prof. Louis Reynolds, Prof. Hans Petter Hougen, Dr. Karen Kelly, Dr. Jennifer Leaning, Sister Alicia Vacas

¹⁸ Because of delays in the Israeli military permits procedures, only two members of the team entered on 8 September, and were later joined by other members of the team as their permits were approved.

Meetings and site visits were held in medical facilities and in the community, and included interviews with victims, survivors and witnesses, healthcare professionals and human rights workers. The FFM teams also interviewed officials working with the World Health Organisation (WHO), as well as officials from the Ministry of Health and Ministry of Justice in Gaza. Additional representatives of medical bodies were interviewed in the West Bank, including East Jerusalem. Each FFM team member had a camera to record findings. Notes were taken on site, and wherever possible original medical files and photos were copied.

The forensic experts did not perform autopsies but examined patients and medical files, and reviewed photographic materials from the morgue of Gaza’s main hospital, Shifa Hospital, in Gaza City. Their work is detailed further below, at 2.3 ‘Forensic pathology’; in Part B, 1. ‘Types and patterns of injuries,’ and in Appendix 2 of this report.

Throughout this report the members of the two teams of the Fact-Finding Mission (FFM) who visited Gaza are referred to as the ‘first FFM team’ and the ‘second FFM team’, respectively. When referred to together they are cited as ‘the FFM teams.’

2.2 Interviews with injured hospitalised patients, 29 July 2014 – 11 September 2014

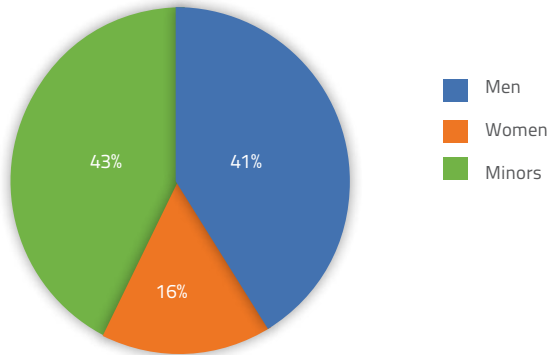
In addition to the two visits to Gaza, members of the FFM teams and of PHR-Israel’s staff developed a questionnaire¹⁹ to document systematically and with uniformity the experience of people who had been injured during the armed conflict. Sixty-eight (68) residents of Gaza who had been injured in the course of the attacks and hospitalised as a result were interviewed in different referral hospitals, summarised in the table below:

Hospital	Location	Patients interviewed
Shifa Hospital	Gaza City, Gaza Strip	3
Al Quds Hospital	Gaza City, Gaza Strip	1
St. Joseph Hospital	East Jerusalem	23
Maqassad Hospital	East Jerusalem	18
Najah Hospital	Nablus, West Bank	7
Abu Raya Rehabilitation Centre	Ramallah, West Bank	2
Bethlehem Arab Society for Rehabilitation	Beit Jala, West Bank	1
Medinat Hussein Al Tibbeya Hospital	Amman, Jordan	11
Other ²⁰		2
Total		68

¹⁹ See Appendix 1 for a copy of the questionnaire.

²⁰ One patient was interviewed at Erez Crossing on his return home, and not at a hospital (interview sortcode Erez1); one medic who had been injured during medical evacuation work was interviewed at his home (interview sortcode MED1).

Interviewees by age and gender



Of the 68 patients interviewed, 29 were minors (under the age of 18) and 11 were adult women. Twenty-one (21) of the interviewees described incidents that had occurred in northern Gaza; 16 in Gaza City; 10 in central Gaza ('Middle Area'); 11 in Khan Younis governorate; and 10 in Rafah governorate. Nine (9) of the incidents involved residents of refugee camps.²¹

With the exception of one person interviewed at Erez Crossing, and two of the injured paramedics who were specifically sought out due to their injuries in the course of medical evacuation work, the patients were approached solely on the basis of hospitalisation because of injuries sustained during the attacks.²² They were interviewed by members of the FFM teams and by PHR-Israel staff on dates between 29 July and 11 Sep 2014. Four (4) patients were interviewed twice, by two different team members on two different dates. Patient interviews included visual examination of wounds and assessment of medical care up to the date of interview. Medical documentation, including file notes, laboratory results, X-rays and other findings, was examined where available. The FFM teams also interviewed medical staff at the above hospitals in order to garner a general impression of cases admitted.

While formal institutional review board (human research ethics committee) clearance was not sought, consent was obtained from all adults and guardians – and assent from children – following full disclosure of the intent and purpose of collecting information by members of the FFM teams. Only after clear permission was given were the interviews conducted and photographs taken of the patients and their injuries. In circumstances where patients were unable to speak because of the nature

²¹ One person, the husband of one of the patients interviewed, who was her companion in the hospital, was interviewed because he had been injured in the same attack his wife described.

²² Meetings were held with the following persons: 20 Aug 2014 and 11 Sep 2014, Shifa Hospital, Gaza City: Hamdy El Kahlawi, Forensic Pathologist; 20 August 2014: Ihab Kaheel, Director General of Ministry of Justice, in charge of access to forensic evidence; 20 Aug 2014, 9 and 14 Sep 2014: Nasser Abu Sha'aban, Shifa Hospital, Gaza City; 11 Sep 2014: Himayah Center for Human Rights.

of their injuries or were either minor or children, a close relative accompanying the patient was interviewed at the patient's bedside and is described as a 'witness' in the report. Where the patients could speak and gave their own testimony, they are referred to as 'patient'. Most of the interviews were held in Arabic with the assistance of an interpreter if the interviewer was not an Arabic-speaker. The interviewers then made English notes of the interview and recorded notes from their medical observations of the patients. For reasons of consistency and clarity these have been paraphrased in the third person. Where additional persons were present during the interview, this is noted. Where patients or witnesses have sought anonymity the name is redacted and the face is obscured; where the patient is a minor, the name is redacted. In all other cases oral and/or written consent for publication of the names and photographs was obtained. **The FFM teams wish to note that the photographs of minors are published with parental consent solely for the purposes of this report and their use for other purposes is not permitted.** The completed questionnaires, medical documents and imaging, additional photographs and contact details of the patients are retained in the offices of PHR-Israel.

Transcripts of all 68 interviews are presented in Appendix 1 of this report, together with photographs wherever available. They are sorted according to the location of the reported incident and classified by governorate. Throughout this report, these interviews are referred to as 'patient interviews', and referenced in the footnotes with a unique sortcode. There is a listing by sortcode at the beginning of Appendix 1.

2.3 Forensic pathology

The FFM teams included 4 forensic experts: two forensic pathologists, one forensic physician and one forensic anthropologist. There were two of these experts on each of the two teams that visited Gaza.²³

In the course of both teams' visits, several meetings were held with the Palestinian doctors and officials in charge of forensic matters in Gaza.²⁰ The aim was to obtain their general clinical impressions regarding the patterns of deaths and injuries during the war, and to gain access to any relevant evidence including recording injuries and possible cause of death on the bodies of the deceased, photographs, documentation and images of the dead, projectiles, shrapnel and tissue samples, where such samples had been retained.

Due to religious and traditional customs prohibiting the practice, autopsies are not performed in Gaza. According to doctors at Gaza's forensic department, during the armed conflict, the dead were brought to Shifa Hospital in Gaza City or to one of two other hospitals where forensic doctors work, for purposes of identification. No

²³ Meetings were held with the following persons: 20 Aug 2014 and 11 Sep 2014, Shifa Hospital, Gaza City: Hamdy El Kahlawi, Forensic Pathologist; 20 August 2014: Ihab Kaheel, Director General of Ministry of Justice, in charge of access to forensic evidence; 20 Aug 2014, 9 and 14 Sep 2014: Nasser Abu Sha'aban, Shifa Hospital, Gaza City; 11 Sep 2014: Himayah Center for Human Rights

autopsies were done and the examination of the bodies was external, including taking 3-4 photographs for each case (digital pictures; copies are kept in the office computers in the doctors' working room); in some cases visible wounds were registered and radiographs taken. In general, the clothes were not completely removed and genitalia were always covered. After the external examination, the body was partially washed and then given back to the families for burial the same day if possible. The injured who had been referred to hospitals outside Gaza and then died were returned by ambulance to the Gaza Strip via Erez Crossing and handed over to vehicles in Gaza after a basic security check by Israeli security authorities, and then underwent the same process of documentation and identification in Gaza hospitals.

There are only 4 forensic doctors in all of the Gaza Strip. The government forensics department has existed since 1995 and has a staff of 4. It is under the authority of the Ministry of Justice, and has been active in the last three or four wars. Authority for access to photographs, X-rays and tissue samples resides with the Ministry of Justice.

The forensics team at Shifa Hospital includes two doctors and two technicians. According to the information received by the FFM teams, of the more than 2000 people killed during the war, about 1500 were examined at Shifa Hospital. The others were examined by two other experts who work at two different hospitals in the south of Gaza. Three of the 1500 deceased seen at Shifa Hospital remained unidentified as of 20 August 2014.

There is one 'autopsy' suite in the morgue at Shifa Hospital, approximately 6x5 meters, with two autopsy tables with water and drainage; one technicians' room attached to the autopsy room, approximately 3x4 meters; one office for forensic doctors, approximately 6x6 meters, with 3 desks and two computers; and a private toilet attached to the room. The FFM teams observed that the morgue's refrigeration was not very effective, possibly due to irregular electric current. There may have been other rooms in the department but these were not seen by the teams. There is no waiting room for families of the deceased. Staff, the dead bodies and families enter the area through the same door.²⁴

Regarding tissue samples, a Ministry of Health official at Shifa Hospital, Dr. Nasser Abu Sha'aban, stated that there was no one specifically dedicated to collecting samples during this armed conflict. He described the collection as haphazard and often unlinked to a particular patient. According to him, the hospitals had encountered difficulty with documentation during previous Israeli attacks, something they tried to address during this latest conflict. He showed the first FFM team tissue samples, some of which he said had been collected during the current armed conflict, which he said are kept in formalin (for tissue samples) or in acetone (for other material samples). The team observed that the sample containers with acetone were not sealed properly.

²⁴ During a visit to the morgue on 11 Sep 2014.

The FFM teams acquired an overview of impressions regarding patterns of injuries and deaths from the Gaza forensics department officials. In addition, 370 photographs of the dead were shared with the team, in some cases together with documentation. This information is summarised later in this report under Part B, 1. 'Types and patterns of injuries'; 4.2 'Allegations regarding irregular weapons'; and in Appendix 2 of this report. The FFM teams were not granted access to examine tissue samples (see 3. 'Limitations' below for further details).

The forensic evidence regarding the dead in this report is limited to descriptions of the official photographs of the dead victims and some associated documentation. Elsewhere, forensic assessments were made via medical observation of patients' injuries, medical documentation of injuries and other evidence provided by witnesses on site.

2.4 Khuza'a – focus and site visit

A focussed site visit was conducted in the town of Khuza'a in the Khan Younis governorate in the south of the Gaza Strip on 10 September 2014, with an additional visit held on 12 November 2014. This site was chosen due to the difficulties reported by rescue organisations and reporters in accessing the site, and the need to collect first-hand evidence regarding various allegations made. Other sites where mass casualties were reported, notably Shuja'iya in Gaza City and Rafah, were better covered and reported by others in real time or shortly after the events. Part C of this report is devoted to the findings from this visit, along with cross references to other interviews held with emergency evacuations services and with a hospitalized patient who was injured at the site.²⁵

2.5 Interviews with Israeli doctors

The principal mandate of the FFM was to investigate the health and human rights impact of events in the Gaza Strip. However, a member of the second FFM team did interview two military reserve doctors from the Israeli army, and a community doctor from the south of Israel, in order to ascertain the procedures for medical evacuation of Israeli soldiers injured during the attacks, and to learn more about the psychosocial impact of the rockets from Gaza on the Israeli communities in the south of Israel. The findings from these interviews can be found in Part B, Chapter 5. 'Evacuation, medical management and referral' and 7.3 'Psychosocial and mental health impact of the attacks.'

3. Limitations

Due to the limited timeframe and resources at the disposal of the FFM teams, no attempt was made to cover the entire territory of the Gaza Strip or to document

²⁵ Interview sortcode EJJ15.

the deaths of each of the persons killed and injured. Instead, the FFM focussed on identifying patterns of injury and attack in order to better understand the health and human rights implications of the war.

The FFM teams did not have access to UNRWA facilities, which provided shelter for many thousands of civilians. They could therefore investigate neither the public health impact of displacement in these facilities, nor the allegations made by the Israeli government regarding the abuse of such facilities for military purposes – an allegation used to justify several attacks on such facilities.

The FFM also had no access to evidence regarding the conduct of Palestinian armed combatants within Gaza, and the teams were not able to examine official Israeli allegations regarding misuse of civilian or medical facilities for military purposes, beyond what its members were told by interviewees.

Because of a lack of military expertise, the FFM was not in a position to provide a comprehensive analysis of the types of weapons used by Israeli forces.

Regarding relations with the Hamas authorities, the FFM teams were granted access to relevant evidence by officials of the Ministry of Health, but encountered difficulties and some lack of transparency regarding the necessary procedures for access to forensic pathology materials, specifically tissue samples and X-rays, which fall under the responsibility of the Ministry of Justice. Despite meeting relevant officials from the Ministry of Health, the Forensics Department, the Ministry of Justice, a Ministry of Justice-led initiative called the Independent Documentation Committee, and an organisation called the Himaya Center for Human Rights, the FFM ultimately was not granted access to tissue samples and X-rays and is therefore not in a position to discuss them.²⁶

²⁶ On 20 Aug 2014, the first FFM team held meetings with Dr. Nasser Abu Sha'aban, a Ministry of Health doctor at Shifa Hospital in Gaza City, and with the 'Independent Documentation Committee', a Ministry of Justice-led initiative dedicated to collecting evidence to determine if war crimes were committed during this armed conflict. Dr. Abu Sha'aban stated that he was a member of this Committee, as a representative of the Ministry of Health. When asked for tissue samples alongside relevant anonymised medical files by the first FFM team, Dr. Abu Sha'aban said he would organise the files and provide a detailed list of samples when the second team arrived in Gaza. However, he deferred for a final decision on this matter to the DG of the Ministry of Justice, Ihab Kahil, who did not wish to share the samples, and stated that it was his intention to send the tissue samples from this conflict abroad (to Turkey) for analysis.

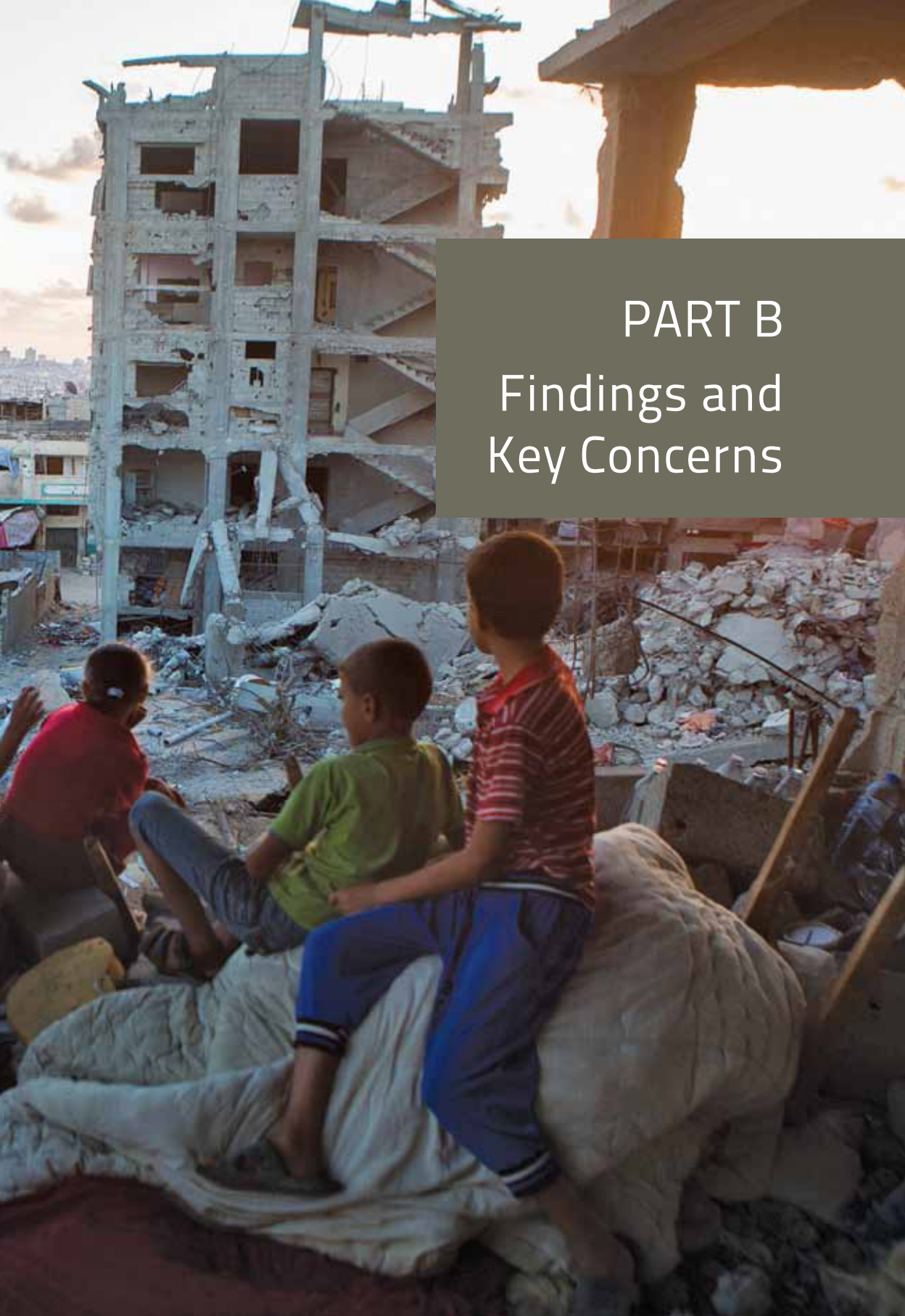
On 9 Sep 2014, the second FFM team met again with Dr. Abu Sha'aban, who granted them access to documentation from several cases at Shifa Hospital. However, although he said that arrangements had been made with the Ministry of Justice for the forensics department to disclose full records, reports, photos and X-rays to the team later that week, when the team reached Shifa hospital on 11 Sep 2014 they were told they needed a permit from the Ministry of Justice and were referred for this purpose to an organization called 'Himaya Center for Human Rights'. Although the director of this organisation described it as 'a non-governmental organization documenting violations of human rights and war crimes regardless of their cause, since 2002,' he also referred to it as an 'inter-ministerial-committee.' It was the impression of the second FFM team that this organisation is closely associated with the (Hamas) government, and that it wished to control the process of forensic evaluation, including sample collection and delivery. Members from the second FFM team believed that, had the team complied with all of the conditions required by this organisation, its independence might have been compromised. The second FFM team engaged in discussions with this organisation around 'best practice' in forensic pathology (eg obtaining samples, collecting evidence, chain of custody, taking adequate photos, obtaining testimonies from witnesses/families of the victims, documentation, etc.), and the importance of objectivity in the current environment. The 'Himaya Center' then gave the second FFM team a form to submit to Dr. Nasser Abu Sha'aban to obtain access to additional materials. A team member submitted the form on 14 Sep 2014, but was then asked to specify names of individual patients. Since this new request could not be met within the timeframe of the visit, permission for access was ultimately not granted to the FFM.

4. Writing and editing of this report

Given the complementary, and at times triangulated,²⁷ nature of evidence collected as well as the broad consensus on the findings within and between the two FFM teams, it was decided to report on their findings in a coordinated manner. An outline of the report structure was agreed upon through Skype meetings and via electronic communication, a division of tasks was set and each of the experts was asked to record his/her findings in detail, and to provide titles and dates for the photos. The notes provided by the teams were then edited according to subject and testimony by the editor of this report, Miri Weingarten of PHR-Israel, with guidance and assistance from the experts. Drafts were sent for approval to the FFM team experts, and then for comments to PHR-Israel and to the partner Palestinian human rights organisations.

The FFM teams wish to express their gratitude to the patients, survivors, witnesses, medical personnel and human rights and community workers from many organizations who helped the teams, provided sensitive and often painful information, and allowed them to develop a sense of patterns of injury and death during this 50-day armed conflict.

²⁷ Triangulation in this context is the collection of evidence regarding one event using more than one method, e.g., interviews, medical observations, examination of records, site visits etc.



PART B
Findings and
Key Concerns



Part B

Findings and Key Concerns

1.Types and patterns of injuries:

1.1 Injuries resulting in death

Three forensic pathologists on the FFM teams¹ independently analysed 370 digital images of the deceased, belonging to a minimum of 75 cases copied from the Shifa Hospital Forensics Department photo archive.² These photographic images were recorded when the dead, and/or injured who later died, arrived at Shifa Hospital in Gaza City. It was the conclusion of the teams that these images are authentic. Within the limitations of evaluating the injuries described in the Introduction,³ the general impression from these photographs is as follows:

The bodies, belonging to men, women and children, have several lacerations of various sizes, some with traumatic limb amputations and others with severe crush injuries. Some bodies also have severe burns. In some cases, the sex and age of the dead were not identifiable (e.g., piled separated body parts). Although the total body surfaces are not shown in any of the cases, all photos sufficient for diagnosis show wounds characteristic of explosion injuries. The patterns of the injuries do not give indications of any specific type of explosive ammunition. There were no obvious gunshot wounds among the injuries seen.

¹ Prof. Hans Petter Hougen, Dr. Karen Kelly and Dr. Önder Özkalipci

² For a detailed description of the photos as observed by the forensic experts on the FFM teams, see Appendix 2, 'Forensic pathology'.

³ See Part A, 3. 'Limitations'.

1.2 Injuries in hospitalised patients

Among the 68 hospitalised patients interviewed by the team, the vast majority required some form of surgical intervention: internal fixation of fractures, debridement of wounds, packing of deep soft tissue craters, decompression of head trauma, etc. Among these hospitalised patients, the following categories of physical injuries were recorded:⁴

Type of injury	Number of patients
Limb fractures	27
Amputations	10
Soft tissue wounds	14
Extensive burns	18
Foreign penetrating objects (mainly shrapnel; 2 bullet wounds)	34
Head trauma / brain damage	16
Spinal injuries	4
More than one category	30

These findings of serious and in many cases multiple injuries are consistent with information received from the Head Nurse of the Emergency Department of Shifa Hospital in Gaza City,⁵ who characterised the pattern of injuries as follows:

Combinations of burns, shrapnel, deep wounds and amputation in the same patient; crush injuries because of houses collapsing over their dwellers; abrasions, lacerations and very high amputations; and serious burns.

An observation of ICU patients made by the first FFM team at Shifa Hospital in Gaza City on 20 August 2014, while the attacks were still taking place, showed similar patterns of injury.⁶ Approximately 50 cases transferred to St Joseph Hospital, East Jerusalem were described by hospital staff as having 'burns, multiple fractures, abdominal wounds, head and brain trauma.'⁷ At Medinat Hussein Al Tibbeya in Amman, Jordan,⁸ injuries were described as 'mainly war injuries because of explosion or crush.' Staff at the Bethlehem Arab Society for Rehabilitation in Beit Jala reported admitting mainly people with amputations and complex lung injuries from shrapnel.⁹

⁴ Orally and by medical observation and/or documentation.

⁵ Interview held on 20 Aug 2014 by AV and LBR.

⁶ Visit held 20 Aug 2014. Three patients, all young males injured in the war: one with trauma to the entire left side of his body with open abdominal wounds; disarticulation of left lower limb at the hip; and perforated sigmoid colon secondary to shrapnel, now with stoma. Second patient with crush syndrome with severe soft tissue injuries and bilateral compartment syndrome of both lower limbs; status post bilateral fasciotomy. Third patient with open chest injury on the right side.

⁷ Interview held on 22 Aug 2014 with Dr. Maher Al Deeb, Director of St Joseph Hospital, an 80-bed hospital in Sheikh Jarrah, East Jerusalem by the first FFM team and PHR-Israel staff. Note this interview was held 4 days before the ceasefire of 26 Aug 2014, and the hospital may have received additional patients after that date.

⁸ Interview with Emad Tawil, Head ICU Nurse held on 30 Aug 2014 by AV.

⁹ Interview held on 4 Aug 2014 with AV and PHR-Israel staff.

It is difficult to estimate the exact number of severely injured among the approximately 11,000 injured survivors of the conflict. According to Dr. Muhammad Al Kashef, General Director of International Cooperation in the Department for the Ministry of Health in Gaza,¹⁰ about 3,000 of the most seriously injured were formally hospitalised and required some form of surgical intervention.¹¹ The teams were not able to verify this figure from hospital documentation or other sources, and were informed that patient documentation overall was incomplete, because of the strain placed on hospital resources during the attacks.¹² The FFM teams were also not able to ascertain whether these numbers, which seem relatively low, were attributable to the limited capacity of the hospitals or to the actual number of severe injuries requiring surgical intervention.

WHO representatives in Gaza and the West Bank said that in their view the pattern of casualties brought to the hospitals, including Shifa Hospital in Gaza City, consisted both of those who had sustained only light injuries and those who were very seriously injured; there were relatively few 'moderate' injuries.¹³

This view is supported by the testimony of a general surgeon who performed plastic surgery at Shifa Hospital during the days of the armed conflict.¹⁴ He confirmed the presence of multiple injuries and added that there were significant numbers of patients with burns involving 1%-3% of body surface area, but also many with 50%-75% bodily involvement.

2. Context and causes of injuries

The hospitalized patients' interviews (referred to hereafter as 'patient interviews') and the additional interviews held with key medical/health professional informants in Gaza indicated the following patterns:

- A consistent picture of people injured or killed while in, or very close to, their homes;
- Numerous cases in which significant numbers of casualties – often members of the same family and rescuers – were killed in a single incident;
- Numerous cases of 'double tap' attacks (see below) and the use of exceptionally powerful and indiscriminate forms of explosives; and
- A lack of precautions to protect civilians, including the absence of effective warnings and non-provision of safe spaces, or safe routes out, for civilians escaping the attacks.

¹⁰ Interview held on 19 Aug 2014 with the first FFM team.

¹¹ Cf the Health Cluster Report, p16, according to which a minimum of 2,663 conflict-related surgeries were performed in Gaza in July and August 2014.

¹² For detail on this see 5.2 below.

¹³ Interviews held on 10 Sep 2014 with Dr. Ambrogio Manenti, Mahmoud Daher and other officials at the WHO in the West Bank; a separate meeting was held in Gaza with Mahmoud Daher on 11 Sep 2014.

¹⁴ Interviewed by the second FFM team on 12 Sep 2014 at Shifa Hospital.



Destruction in Shuja'iya.
Photo by HPH, 9 Sep 2014



Destruction in Khuza'a.
Photo by AV, 12 Nov 2014

These findings are elaborated with supportive evidence from the FFM teams in the sections below.

2.1 Multiple casualty events and their causes

According to UN sources, as of 24 August 2014, at least 142 families had lost at least 3 members of the same family in a single incident.¹⁵

In all the interviews held with health professionals in Gaza, interviewees drew the attention of the teams to the fact that many of those injured or killed were civilians who were attacked in large groups, usually in or near their own homes.

This impression is borne out by the patient interviews:

- 31 reported that other persons had been killed in the same incident in which they had been wounded (ranging from one other person injured to 21 others);
- 41 reported that other persons had been killed in the same incident (ranging from one to 30 others);
- 39 of those interviewed reported that members of their own family were either killed or injured in the same incident;
- One reported the onset of labour in a pregnant woman as a result of the incident.

The following offers an explanation of patterns of attack that are likely to have caused such multiple concurrent casualties:

¹⁵ See UN OCHA, Gaza Initial Rapid Assessment, 27 Aug 2014, available at <http://unispal.un.org/UNISPAL.NSF/0/F5F968C3F38D8D2785257D4F004A26B6> accessed 23 Nov 2014.



Buses destroyed in the attack on Muhammad Deif's family, Sheikh Radwan, Gaza City. Photo by AV, 9 Sep 2014.



Destruction in Shuja'iya. Photo by HPH, 9 Sep 2014.

2.1.1 'Double tap'¹⁶ and multiple consecutive strikes

Many of the FFM interviewees, including both emergency services staff and patients, reported a pattern of attack involving an initial strike, followed by a brief interval during which relatives, bystanders and/or rescuers gathered round the casualties, only to be struck by a second missile, causing multiple additional casualties. In other cases, double or multiple consecutive strikes were reported, often on a multi-story building, in which after the first strike, while residents of the building were on their way down the stairs or exiting the building, additional consecutive strikes caused further multiple casualties. This is a separate phenomenon from that of the so-called 'roof-tap warning' strikes, which are discussed in No 2.3.1 below.

- In the hospitalized patient interviews, 10 patients reported a 'double tap' pattern, in which the second strike caused the incident that injured them: three of these were described as drone strikes;¹⁷ three described strikes from tank shells or missiles;¹⁸ two were from an F16 aircraft;¹⁹ and, in two other cases, the source of the double strike was unknown to the patients.²⁰
- In 5 other cases, patients reported multiple strikes from F16 aircraft with a similar effect. Those running to assist people injured by previous strikes, or running to escape previous strikes, were then injured or killed by repeated subsequent strikes.²¹
- The 30 July 2014 attack on the Shuja'iya marketplace in the east of Gaza City

¹⁶ The term 'double tap' was first coined by the Bureau of Investigative Journalism to describe drone warfare tactics in the Yemen and Pakistan. For a recent example, see BIJ data sheet, Drone Strikes in Pakistan, 1 Aug 2013, at <http://www.thebureauinvestigates.com/2013/08/01/get-the-data-the-return-of-double-tap-drone-strikes/>, accessed 23 Nov 2014.

¹⁷ Interview sortcodes EJJ13, EJM3, J8.

¹⁸ Interview sortcodes EJM1, and, describing a single incident, EJM4 and EJM5.

¹⁹ Interview sortcodes EJJ21, GS2

²⁰ Interview sortcodes WBN2, EJJ11

²¹ Interview sortcodes EJ21, EJJ3, EJM10, J5, EJM7



Mine sweeping device, Khuza'a (*Tsefa Shirion?*).
Photo by HPH, 10 Sep 2014



Mine sweeping device, detail.
Photo by AV, 10 Sep 2014

was characterised by a similar pattern of attack: multiple strikes hit the teams attempting to evacuate those injured by previous attacks.²² Palestine Red Crescent Society (PRCS) staff interviewed by the first FFM team emphasised this pattern as a key cause of injuries and deaths among evacuating medical teams.²³

2.1.2 Heavy explosives and indiscriminate attacks

Many of the deaths in Gaza from this war were reported as being caused by the use of large amounts of powerful explosives in indiscriminate ways, typically destroying large swathes of residential areas and causing mass casualties, not only in targeted houses but also in neighbouring dwellings.

- The second FFM team witnessed the stark results of this policy on their visit to Shuja'iya in Gaza City, which was the site of extensive attacks of this type.²⁴
- The second FFM team also witnessed the results of powerful airstrikes launched on the last 3 days of the offensive, causing devastation to high-rise multi-apartment blocks in Beit Lahiya in northern Gaza and in Gaza City.²⁵
- During the second FFM team's site visit to Khuza'a in the Khan Younis area,²⁶ they were shown a barrel-shaped explosive container described by local residents as an 'explosive barrel', left on the ground in an area of residential destruction.

²² For more detail on this see Chapter 3. 'Attacks on medical personnel and medical facilities' below, and interview sortcodes MED2 and EJM1.

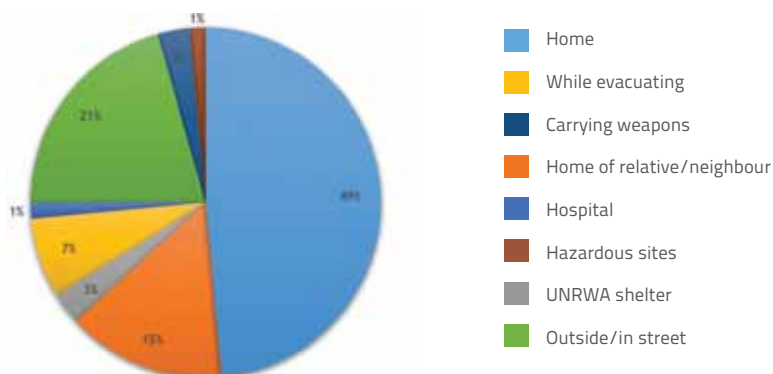
²³ PRCS coordinator, interviewed in Gaza on 19 Aug 2014 by the first FFM team, full name redacted and retained in the offices of PHR-Israel.

²⁴ Visits by members of the second FFM team on 12 and 14 September.

²⁵ For a media account of the destruction of the Al Zafer building, in which 22 people were wounded by a double airstrike, see the Guardian, 24 Aug 2014, at <http://www.theguardian.com/world/2014/aug/24/gaza-strikes-destroy-highrises>, accessed 23 Nov 2014. For descriptions of further strikes on high-rise buildings see Al Jazeera English, 26 Aug 2014, at <http://www.aljazeera.com/news/middleeast/2014/08/gaza-high-rise-hit-israeli-rockets-2014825213929205207.html>, accessed 23 Nov 2014.

²⁶ See Part C. 'Khuza'a - focus and site visit' below.

Location of incident leading to patient's injury



Judging from the Hebrew text on the device, this was the barrel of a *Tzefa Shirion*, an Israeli mine-clearing system whose barrel is launched from a vehicle ahead of the advancing troops and contains a line ('python') of explosives. The line is unrolled from the barrel on its way through the air and its explosive loads are then detonated, clearing landmines and opening a corridor for the troops. *Tzefa Shirion* was used by Israel in residential built-up areas in the 2006 Lebanon War and also on 4 occasions in the 2008-9 attacks on Gaza - causing destruction of entire streets and neighbourhoods.²⁷ It is unclear to the FFM teams how many times this indiscriminate device was used in residential areas during the current attacks, in addition to its apparent use in Khuza'a.

- During the first FFM team's visit to Gaza the term 'explosive barrel' was also used by some witnesses to describe bombs dropped by F16 aircraft.²⁸ The question of 'explosive barrels' dropped from aircraft requires further examination by military experts.
- The second FFM team visited and interviewed the Abu 'Ilba family in Sheikh Radwan Neighbourhood in Gaza City.²⁹ Many houses in this neighbourhood belong to the Abu 'Ilba family, who were neighbours of the Al-Dalou family home, which, according to Israeli media, was targeted on the night between 19 and 20 August 2014 with the intention of assassinating Muhammad Deif, a Hamas militant who was believed to be staying there at the time.³⁰ The attack, which killed Deif's wife and son, targeted the 3-story building, and reportedly involved 5 missiles and additional heavy explosives. The team was shown the devastation caused to the area around the targeted home, including the destruction of 10 buses belonging to a company owned by the Abu 'Ilba family, which were parked

²⁷ For Hebrew-language articles discussing the use of *Tzefa Shirion* during 'Operation Cast Lead' in 2008-9 in Gaza, and in Lebanon in 2006, see Haaretz: <http://www.haaretz.co.il/1.1242449>; Israeli military journal Bamahaneh: <http://www.fresh.co.il/vBulletin/showthread.php?t=209705&highlight=%F6%F4%F2+%F9%F8%E9%E5%EF>, accessed 23 Nov 2014.

²⁸ See also a similar description in interview sortcode J9.

²⁹ On 9 Sep 2014.

³⁰ See e.g., Haaretz news item from 20 Aug 2014, at <http://www.haaretz.com/news/diplomacy-defense/.premium-1.611689>, accessed 23 Nov 2014



Damaged UNRWA shelter, Jabalia Elementary Girls School, north Gaza. Photo by OO, 19 Aug 2014



Damage to wall, UNRWA shelter, Jabalia Elementary Girls School, north Gaza. Photo by LBR, 19 Aug 2014

in the street. The patriarch of the Abu 'Ilba family told the team that 35 other buses had been damaged. According to another member of the Abu 'Ilba family, interviewed by the FFM team in his damaged apartment, which was adjacent to the place of the attack, the impact of the blast was so great inside their apartment that his daughter, a 2-month-old baby girl, was thrown up in the air from a bed she was lying on, her head hitting the ceiling of the room, causing head trauma.³¹ The entire building in which this event had occurred was noted to be damaged and empty on the day of the team's visit. According to the family members, the authorities were still determining whether the building would be habitable with repairs; in the interim, all its residents were displaced.

- In the patient interviews, 3 of the patients reported their injuries within the context of the use of huge amounts of explosives, destroying several structures simultaneously.³²
- The patient interviews suggest that even when precision weapons were used against specific targets, such as individual apartments, these were liable to cause shrapnel, blast or damage to neighbouring homes and passers-by. Five hospitalised patients interviewed by the teams reported being injured as a result of shrapnel, damage or blast from attacks on neighbouring homes.³³

³¹ According to her father she was hospitalised and released after a few days.

³² Interview sortcodes GS1, GS2, J9

³³ Interview sortcodes EJM6, WBN5, WBN, Erez1 and EJJ23. The injury in interview sortcode J12 resulted from an attack on a car outside the patient's house; in interview sortcode EJM18 the injury resulted from an attack on open land near the patient; and in interview EJJ25 the injury was caused by the collapse of a building's roof when a neighbouring apartment was attacked.

2.2 'No safe place'

According to many of those interviewed by the FFM teams, generalised warnings issued by the Israeli military to large parts of the Gaza Strip via leaflets and SMS texts³⁴ resulted in panic and mass displacement, and did not provide effective protection for many civilians. There was a sense of 'no safe place' since many of those killed died either in their own homes³⁵ or while fleeing them.

This sense of 'no safe place' is borne out by the patient interviews. Of the 68 patients interviewed:

- 33 were injured in or around their own homes (2 were at home, 3 were in their back yard and 6 were at the doorway to or just outside their homes);
- 10 were in or just outside the home of a relative or neighbour with whom they were staying for greater safety;
- Two were injured while in an UNRWA shelter;³⁶
- 5 were injured while evacuating other injured people (4 of these were ambulance paramedics and one was injured in his tok-tok on his way home from evacuating injured people³⁷)
- One was a hospital nurse injured on duty when her hospital came under attack;³⁸
- 14 were injured out of doors (of these, most were moving from one place to another for greater safety or to get supplies, one was outside a mosque,³⁹ one was working his field,⁴⁰ and one, a 7-year-old,⁴¹ was in a playground);
- Two patients⁴² were injured on a motorbike while one of them was transporting weapons and
- One⁴³ patient, a 4-year-old, was injured after the ceasefire while playing in the rubble of destroyed homes in his neighbourhood;⁴⁴

According to a coordinator of emergency services at the Palestine Red Crescent Society (PRCS),⁴⁵ the Israeli military used Salah al Din Road, the main highway running the entire length of the Gaza Strip from north to south, to divide the Gaza Strip into east and west segments. Everyone within 3 km of Gaza's eastern border with Israel was advised to evacuate (via leaflets dropped from the sky). PRCS estimates that about 500,000 people were internally displaced, especially alongside the north and east borders, but also from the west, where shelling from Israeli gun-boats took

³⁴ For the wording and location of the warnings see the IDF website <http://www.idfblog.com/blog/2014/07/17/idf-drops-warning-leaflets-gaza/> accessed 18 Nov 2014

³⁵ See Amnesty International, Families under the Rubble, 5 Nov 2014, <http://www.amnesty.org/en/library/asset/MDE15/032/2014/en/613926df-68c4-47bb-b587-00975f014e4b/mde150322014en.pdf>, accessed 23 Nov 2014

³⁶ Both of these incidents were in northern Gaza. See interview sortcodes J10 (Beit Hanoun) and EJM10 (Jabalia).

³⁷ For details on injured medics see Chapter 3 'Attacks on medical personnel and medical facilities' below, and interview sortcodes MED1, MED2, MED3 and MED4. On the tok-tok driver see interview sortcode EJJ9

³⁸ Interview sortcode MED5 / J9.

³⁹ Interview sortcode EJJ8

⁴⁰ It is unclear if this patient's condition was caused by pesticide exposure or by a conflict-related source.

⁴¹ Interview sortcode EJJ24

⁴² Interview sortcodes J2, J11

⁴³ Interview sortcode EJM9

⁴⁴ See 6.2 'Hazardous sites' below.

⁴⁵ Interview held on 19 Aug 2014 by the first FFM team. Name redacted and retained by PHR-Israel at request of the interviewee.

place from the sea, confining many to a narrow area (less than one kilometre wide) between Salah al Din Road and the buffer zone, near the Israeli border. When the IDF later gave instructions to evacuate from the west of Gaza (the coastal side, closing West Beach Road), it meant that residents of Gaza were squeezed into the middle of the Gaza Strip. Even within this middle area, however, many attacks were reported.

The PRSC coordinator said:

There was no clarity about where to go, even though the directions were to leave. No shelters were provided and there were no safe houses. Therefore, there was no solution about where to go.

The FFM thus concludes from its investigation that there was no 'formal' or clearly-defined battlefield, and that, consequently, anywhere within this tiny strip of densely populated built-up urban and peri-urban area was a potential military target.

In addition, the first FFM team, which visited Gaza while the conflict was still ongoing, reported that the sheer numbers of internally displaced persons (IDP) put a strain throughout Gaza on the locations where they attempted to seek refuge. On 19 August 2014, the first FFM team observed hundreds of people – children, adults and the elderly – milling around an UNWRA girls school in Jabalia, north Gaza, which had been bombed and damaged several weeks earlier. The school appeared over-crowded with poor sanitation facilities, and food was difficult to obtain and expensive. In addition, the first FFM team conducted informal interviews with a number of internally displaced people who sought refuge inside the grounds of Shifa Hospital, camping out everywhere in make-shift tents constructed from blankets, rope and tree trunks. Here too, there was little drinking water, people were cooking haphazardly, sanitation facilities in the hospital were overrun and there was an atmosphere of desperation.⁴⁶ In both instances, people did not have the impression that they were really safe in either the school or the hospital, as they believed that at any time they too could become a target. Yet, they reported that they had nowhere else to go.

2.3. Lack of and failure of warnings

Under International Humanitarian Law there is an obligation to take feasible precautions to protect civilian population and objects during armed conflict, including an obligation to give effective advance warning of attacks. In 2009, the United Nations Human Rights Council-appointed Fact Finding Mission on the Gaza Conflict (known as 'the Goldstone Report') examined the issue of warnings and found 'factors in Israeli policy that significantly undermined the effectiveness of the warnings, including the lack of specificity and thus credibility of many pre-recorded phone messages and leaflets. The credibility of instructions to move to city centres for safety was also diminished by the fact that the city centres themselves had been the subject of

⁴⁶ For more on the issue of displacement see 6.1 below.

intense attacks during the air phase of the military operations.⁴⁷ The Mission stressed that 'the fact that a warning was issued does not relieve a commander and his subordinates of taking all other feasible measures to distinguish between civilians and combatants.'⁴⁸

The FFM teams found similar problems in the current attacks. Their general conclusion is that Israeli military warnings were highly inconsistent, which undermined the ability of civilians to respond effectively and thus secure their safety.⁴⁹ In an attempt to construct a reliable picture of such warnings prior to attacks, the teams specifically inquired about experiences with warnings during their interviews. The FFM team members asked patients injured by the attacks whether there had been any warning prior to the incident that had injured them; they posed similar questions to community members who were displaced as a result of the destruction of their homes; and, finally, they queried healthcare personnel who had experienced or heard of warnings in some way. A summary of these findings follows.

2.3.1 No warnings and ineffective warnings

The vast majority of the hospitalised patients interviewed stated that they had received **no prior warning** of the attack in which they were injured. Of the 68 patients interviewed, only 5 reported prior warnings; one of these was a telephone warning and 3 others noted 'warning' strikes preceding a main strike, which were not effective in protecting the inhabitants. These are detailed below:

- One patient⁵⁰ described what might have been a 'roof-knock' warning, i.e., a small explosive strike used by the Israeli military to warn residents of an imminent larger strike on their home. Whatever its intention, the roof-knock strike has been shown to be dangerous in itself, causing damage and injuries, and can easily be misconstrued in ways described below, and therefore ineffective. This type of warning was examined by the Goldstone Report, which concluded that 'this technique is not effective as a warning and constitutes a form of attack against the civilians inhabiting the building.'⁵¹ In this particular case, a missile hit the roof and caused water leakage and other damage. The patient was injured by the second, main explosion while examining the damage, and others were also killed.
- Two other patients,⁵² cousins injured in the same attack, described a strike that may have been either a 'roof-knock' warning or an attack on a neighbouring house (the interviewees were not sure), which led to the family fleeing their home. The strike caused them to flee their home; they were then injured by a

⁴⁷ Report of the UN Fact Finding Mission on the Gaza Conflict (the Goldstone Report), 15 Sep 2009 at Para 5., available at <http://image.guardian.co.uk/sys-files/Guardian/documents/2009/09/15/UNFFMGCReport.pdf> accessed 23 Nov 2014.

⁴⁸ Ibid.

⁴⁹ A separate issue is that warnings do not in themselves justify the massive or wanton destruction of homes and civilian property, a grave violation of International Humanitarian Law under the Fourth Geneva Convention, Arts 33 and 53. See also 6.1 below.

⁵⁰ Interview sortcode EJJ4a/EJJ20

⁵¹ See note 42 above. For another example of a roof-knock strike see 2.3.4 below

⁵² Interview sortcodes EJJ1a/EJJ10; EJJ3/EJJ3a



Damage caused by a 'roof-knock' strike and by the main strike that followed it, Beit Lahiya, north Gaza.

subsequent strike outside their home, which caused several deaths and injuries.

- The fourth patient to describe a warning prior to his injury⁵³ reported receiving a telephone warning. After the family had fled the house they realised they had forgotten a baby inside. After the patient went back to get the baby, the house was attacked and he (the patient) was hit, causing the injuries described during his hospital interview. Three minutes after they had left the house, it was blown up completely.
- Another patient⁵⁴ reported a family member receiving a telephone warning to leave his home; however, this was two weeks *after* the incident that had injured him, in which his home and all the homes of his extended family had been destroyed or rendered uninhabitable.
- Finally, one patient⁵⁵ reported a previous warning telephone call that had led to his leaving his home in northern Gaza. However, *after* the family relocated to an UNRWA shelter, they were attacked there, without warning, leading to his present injury.

More generally, the Information Officer for the Ministry of Health Dr. Abd El Qader Lubad⁵⁶ said that because so many people were hit while in the street fleeing their homes, many people in Gaza eventually decided not to leave home even after a warning had been received. This response is supported by the findings of the team in Khuza'a.⁵⁷

2.3.2 Warnings not followed by an attack

⁵³ Interview sortcode EJJ14

⁵⁴ Interview sortcode GS1

⁵⁵ Interview sortcode J10

⁵⁶ Interview held 20 Aug 2014 by the first FFM team

⁵⁷ See Part C. 'Khuza'a - focus and site visit'.



In two cases the team was told of warnings that were not followed by an attack.

- Mahmoud Daher, head of the WHO sub-office in Gaza,⁵⁸ told the second FFM team of one case in which a health care worker at Shifa Hospital received an anonymous call identified only as 'IDF,' warning of an impending attack on northern Gaza. The evacuation call caused a state of panic until the hospital called the Israeli military for confirmation. About 10 minutes later, the army announced that they were 'not responsible' for this call.⁵⁹
- One other person interviewed by the team⁶⁰ reported that a telephone warning was given after midnight to a neighbour in the same high-rise apartment building where he lived, Susi Tower in Gaza City, to evacuate the entire building within 5 minutes. This caused panic and mayhem among the occupants. The warning came on the night of 25 August 2014, the same night on which two other buildings, Al Basha and the Italian Tower, were completely destroyed. However, their building was not attacked.

2.3.3 Effective warnings leading to destruction of homes

Apart from the patient interviews, the FFM teams heard of 7 cases of 'effective' warnings from other interviewees, which led to the destruction of homes without involving death and injury. All such warnings caused high anxiety and frenzied attempts at exit, with the recipients having no way of knowing whether the attack would follow within 3 minutes or 3 hours, or possibly not at all. The details of these cases are as follows:

⁵⁸ Interview held in Gaza, 11 Sep 2014 by KK and AV.

⁵⁹ According to a WHO Situation Report from 6 Aug 2014 both Shifa and Abu Yussuf Al Najjar Hospitals received telephone warnings on 1 Aug 2014, causing panic. The warning to the latter hospital was followed by an attack, causing significant damage. The outpatient department of Shifa Hospital had been attacked prior to that date, on 28 Jul 2014, injuring several people.

⁶⁰ Interview held 8 Sep 2014 in Tel Al Hawa, Gaza City with Basel Diab, 33, an agricultural engineer who worked for the PA security forces and became unemployed after 2007. He had previously lost his home during the attacks of 2008-2009.

- In one interview with a displaced person from the neighbourhood of Beit Hanoun in northern Gaza,⁶¹ the family received a general evacuation notice to leave the neighbourhood, and did so. Their lives were saved but their home was completely destroyed.⁶²
- In another interview with displaced persons in the north of Gaza,⁶³ the 3-story home of 3 brothers, their families and their father was destroyed by an explosion after two 5 minute warnings. The first warning was by telephone; the second was a 'roof knock' warning, described as 'a small rocket that came through the roof.' This warning was effective and the family narrowly escaped injury, but the destruction caused by the main explosion resulted in the displacement of this very large extended family.
- A case of effective and focused warning, demonstrating the ability of the Israeli military to attack with a very high level of precision as well as issue appropriate warning when it so chooses, was recorded in an interview with Zakariya Mahmoud Muhammad Al Najjar,⁶⁴ who was displaced from Al Shati Refugee Camp on 15 July 2014. Around 150 members of his extended family were living in a 3-story building. His brother received a telephone call around 04:00, but did not answer. Their neighbour was then called with the following message: 'Tell the Al Najjar family to evacuate in 7 minutes. We are going to target their house.' They described chaos in the house as they all fled taking nothing with them. The house was immediately targeted by a drone missile and 45 minutes later by a larger missile from an Apache helicopter. When it was over, the interviewee went back to the house with a cousin, to check if the chickens they kept on the roof were all killed. At that moment the neighbour received a second telephone call saying: 'Tell your neighbours to leave the chickens and leave the house', so they ran away. The house was targeted again from the back with missiles from Apache helicopters and F16 aircraft. The interviewees said they think their house was hit because there was a Qassam launcher in the area; and because a collaborator gave the Israeli military their name as those responsible for the rocket attack. The interviewee said that this collaborator was arrested by Hamas police and was among the 18 who were killed during the war.⁶⁵ During the interviews, several neighbours and family members confirmed his account.
- In one second-hand account received by the team, later corroborated by the victim himself, the Head Nurse of the Emergency Department of Shifa Hospital⁶⁶ told how the house of Dr. Nasser al Tattar, General Director of Shifa Hospital, had been completely destroyed. The General Director had received a warning call on his cell phone while at work in the hospital during Ramadan, in perfect Arabic,

⁶¹ Interview with Fadi Awuda, 42, held 8 Sep 2014 in Tel Al Hawa, by the second FFM team.

⁶² For further detail regarding the impact of destruction of homes see 6.1 'Destruction of homes and long term displacement' below.

⁶³ Interview held 10 Sep 2014, in Beit Lahiya, by the second FFM team.

⁶⁴ Interview held 8 Sep 2014 in Tel Al Hawa, Gaza City, by the second FFM team.

⁶⁵ According to media and human rights reports, Hamas-associated gunmen publicly executed up to 25 people accused of collaboration with the Israeli military during Aug 2014. See e.g Human Rights Watch statement of 25 Aug 2014, available at <http://www.hrw.org/news/2014/08/25/gaza-halt-executions>, accessed 7 Dec 2014.

⁶⁶ Interview with the Head Nurse of Shifa Hospital held 20 Aug 2014 by LBR and AV.

advising him that he had 'five minutes to get out.' He responded that he was not at home, but at work in the hospital, and did not have time to go back and ensure that his family was safe; however, the voice reiterated that he had 5 minutes and hung up. He managed to warn his wife and children; and, a few minutes later, his house was completely destroyed. Fortunately, no one was injured.

- As a further example of the panic caused by warnings, the same Head Nurse recounted the case of the mayor of the Gaza City municipality, Nizar Hijazi, whose extended family lived on A-Shoda Street in Remal, Gaza City. By chance, he was in the area and saw the women of the family 'running for their lives' from their home, after receiving a warning late at night. They were wearing pyjamas, trying to get dressed and cover their heads with hijabs or prayer shawls. The members of the family were coming out of the house 'in total shock, crawling, screaming, and sobbing.' Two or three hours later the house was destroyed.

3. Attacks on medical personnel and medical facilities

In situations of armed conflict, medical personnel, units and transports are afforded specific protection under the provisions of International Humanitarian Law (IHL). Under these provisions, medical personnel, units and transports must be respected and protected, and must never be the object of attack.⁶⁷ All vehicles marked with distinctive medical signs, including ICRC, PRCS, and others, should be protected, with every effort made to secure safe evacuation. During their visits, the FFM teams were informed repeatedly that ambulance insignia, as well as GIS maps of all health care facilities (hospitals, long-term care centres and primary healthcare clinics) were given in advance to the Israeli military to avert any confusion about what constituted medical personnel and facilities, and to secure the respect of medical neutrality. In practice, however, medical units and facilities were not protected and in some instances, as documented, they appear to have been hit as direct targets with patients present.

3.1 Attacks on emergency teams

According to the Health Cluster Report,⁶⁸ 23 health workers died as a direct consequence of the conflict, of whom 16 were killed while on duty. A further 83 were injured, the majority of whom were ambulance drivers for the various pre-hospital emergency service providers (MoH, PRCS, Palestinian Medical Military Services PMMS, Civil Defence and NGOs). According to the Palestinian Ministry of Health, as cited in the same report, an ambulance station and a total of 45 ambulances were damaged or destroyed either as consequence of direct attacks or as collateral

⁶⁷ Additional Protocol I, Art 15; Additional Protocol II, Arts 9, 11.

⁶⁸ Health Cluster Report pp10, 13.

damage.⁶⁹ According to one interviewee,⁷⁰ these deaths occurred despite the fact that the Israeli military had been provided via international organisations with a sample of the uniforms of all the medical/first aid teams from different organizations in Gaza.

The teams met and interviewed a coordinator of evacuation services for the Palestine Red Crescent Society (PRCS),⁷¹ as well as four PRCS paramedics who had been injured in the course of medical evacuation.⁷² An additional doctor from the Ministry of Interior's Medical Military Aid ambulance service, who had accompanied a paramedic who was killed on duty, was also interviewed and his testimony is paraphrased below.⁷³

The interviewees cited two issues which compromised the protection afforded to medical personnel and transports during armed conflict. One was the pattern of 'double tap' attacks,⁷⁴ which led to injuries and deaths among medical evacuating teams, and the other was the failure of the coordination mechanism instituted by the International Committee of the Red Cross (ICRC) and the Israeli military for safe evacuation during military attacks.

3.1.1 'Double tap' attacks on medical evacuation teams

According to the PRCS coordinator interviewed by the team, PRCS headquarters attempted to respond to the air attacks by distributing ambulances to strategic places, hoping to decrease response time and to respond even when injured people were unable to call for help in the event of electricity and communication failures. In practice, the result was that in many cases the ambulances travelled to a location after a first explosion, without knowing its nature, and shortly after they arrived there was a second, larger explosion, causing damage, injuries and sometimes casualties among the medical teams. The Israeli military ground invasion also affected where PRCS could place ambulances. They were restricted to central Gaza, and needed coordination with the Israeli military for each evacuation.

According to one of the paramedics interviewed by the team, Akram Al Awoor:⁷⁵

The 2014 war was by far the most difficult of 3 wars I have experienced as a PRCS medic - a massive burden of injured, and targeting of medics and ambulances; typically a first strike followed by a second strike when people gathered to assist victims of the first.

⁶⁹ In the course of the interview with the PRCS coordinator, at 19:08 on 20 Aug 2014, he received a cell phone call reporting that an ambulance at Bureij Refugee Camp had been targeted.

⁷⁰ Dr. Diab Al Din Muhammad Abu Hussein, medical doctor with the Ministry of Interior Medical Military Aid, interviewed by the second FFM team on 9 Sep 2014 at the offices of Al Mezan Center for Human Rights in Gaza City.

⁷¹ The Palestinian ambulance service, recognized by the International Federation of the Red Cross for emergency medical evacuation in the occupied Palestinian territory. PRCS in Gaza has 5 branches: Gaza City (Al Quds hospital), Khan Younis, Jabalya, Rafah and Deir Al Balah. The two most important are Khan Younis (which includes a rehabilitation center) and Al Quds, a general hospital which also has emergency, psycho-social, PHC, ambulance, and disaster management unit services.

⁷² The full texts of the interviews with the latter are at interview sortcodes MED1, MED2, EJM1 and WBBJ1.

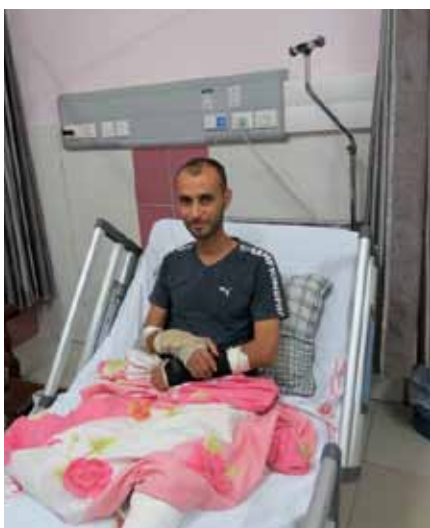⁷³ Dr. Diab Al Din Muhammad Abu Hussein, interviewed by the second FFM team on 9 Sep 2014 at the offices of Al Mezan Center for Human Rights in Gaza City.

⁷⁴ Described above, 2.1.1 'Double tap' and multiple consecutive strikes.'

⁷⁵ Interview sortcode MED2



Injured paramedic Akram Al Awoor, Al Quds Hospital, Gaza City. Photo by LR, 10 Sep 2014



Interview with injured paramedic Akram Al Awoor at Al Quds Hospital, Gaza City. Photo by LR, 10 Sep 2014

Case Study: Shuja'iya 20 July 2014

According to the medical professionals interviewed by the two FFM teams, there were two mass-casualty attacks on the neighbourhood of Shuja'iya in the eastern part of Gaza City, close to the Israeli border. The first was on 20 July 2014. The Ministry of Interior Medical Military Aid ambulance doctor interviewed by the second FFM team reported an extreme case of multiple attacks on rescue personnel, and described the death of his colleague, a paramedic. His testimony also illustrates the typical massive residential destruction, with people still inside their homes, resulting from this form of attack:

The fourth call we answered that shift was from Al Nazzaz Street [in Shuja'iya-Ed.]. Several houses were hit directly while residents were inside. There was severe shelling in the area. Three ambulances went back to Shifa Hospital carrying dead and injured and the fourth ambulance remained in the area, with myself and the paramedic Fouad Jaber, giving first aid to the many people injured on the streets. Around 05:30 or 06:00 the attacks intensified and prevented us from reaching the ambulance. We were moving from house to house, treating people as we could. Our colleagues from the other three ambulances called us telling that it was impossible to enter the place. I told them not to come, it was too dangerous. A man called us from the end of the street crying that many of his children were injured. We tried to reach the place on foot. When we were around 30 meters from the house, there was heavy gunfire in our direction despite our uniforms. The shooting came from nearby houses, but I couldn't see the shooters. We had to go back to the ambulance, where the driver and the photographer were waiting for us, ready to leave. The driver and myself in the front seats and Fouad and the photographer in the cabin.

At 06:15 the ambulance moved some 50 meters when we were surprised by a shell which landed just in front of the vehicle. We were going very fast. We had to brake. Suddenly I felt a shock like an earthquake, and I knew that the ambulance was hit. When I looked around the driver was unconscious and I myself was very dizzy from a head injury.

Thirty (30) seconds later a second missile hit the ambulance directly. The driver was thrown out from the vehicle. I heard Fouad and the photographer calling me: 'Are you ok?' I told them: 'Get out and run. They are aiming at us!!!' I tried to get out myself but my door was stuck and I couldn't open it. I got ready for a sure death and said a prayer. Then a drone (maybe, I am not sure about it) struck close by and the door opened by itself, so I could run away.

Fouad and the photographer were protected by a wall: there were trees close to the road. I ran away from the ambulance towards them. Fouad asked: 'Where can we go?' Bombs were literally 'raining' all around us. The photographer said: 'Keep squatting, to avoid shrapnel.' He was still talking when a missile hit him on his shoulder (I saw it, it was like fire flying towards him). I was thrown back by the blast. Drones and artillery were shelling at the same time. I was semi-conscious, with several injuries. I tried hard not to lose consciousness and called out for help. Close to me there was an old man, covered with blood, calling me. There was dense black smoke all around. Bombs kept falling for a long time. I knew that Fouad and the photographer could not have survived the attack.

I woke up three hours later at Shifa Hospital and learned that Fouad and the photographer had been martyred [description given to anyone killed in attacks by Israel-Ed.]. The driver was injured.⁷⁶

Case study: Shuja'iya, 30 July 2014

Ten days later, a second mass-casualty attack on Shuja'iya took place on 30 July 2014 between 16:00 and 17:00, just when a ceasefire had been declared and people were going out to the market with their families. Because roads had been destroyed or were covered with rubble and debris, ambulances could not access the injured.⁷⁷ According to PRCS, two paramedics died in this rescue operation, 3 PRCS staff were wounded and an ambulance was damaged.

Three of the medical professionals interviewed by the FFM teams were injured while evacuating the wounded during this second round of attacks on Shuja'iya, in the marketplace, on 30 July 2014. Their testimonies are reproduced in full in Appendix 1.⁷⁸

⁷⁶ Dr. Diab Al Din Muhammad Abu Hussein, interviewed by the second FFM team on 9 Sep 2014 at the offices of Al Mezan Center for Human Rights in Gaza City. The photojournalist with Fouad Jaber was Khaled Reyadh Hamad: see CPJ news item, available at <http://cpj.org/killed/2014/khaled-reyadh-hamad.php>, accessed 7 Dec 2014. For another paramedic's testimony regarding the same event see Btselem testimony at http://www.btselem.org/testimonies/20140722_gaza_paramedic_ahmad_sabah, accessed 7 Dec 2014.

⁷⁷ According to the PRCS coordinator, more than 250 people were injured in this incident; more than 23 people died immediately; 30-35 patients came to Al Quds Hospital, mostly with amputations and four of these people died. For media coverage of the incident see, inter alia, BBC news item from 30 July 2014, at <http://www.bbc.co.uk/news/world-middle-east-28571785>, accessed 23 Nov 2014.

⁷⁸ Interview sortcodes MED1, MED2, EJM1.

These cases are a clear example of rescuers, in this instance formally trained and clearly demarcated health professionals in uniform, killed or injured while trying to evacuate casualties from an attack. A 30 July 2014 video showing 11 strikes in quick succession, in the course of which ambulance teams and a photojournalist are hit, was shown to the team.⁷⁹ This footage, as well the interview with injured paramedic Akram Al Awoor,⁸⁰ describe a case that is very similar in details to the case described above, of the death of Fouad Jaber with a photojournalist on 20 July 2014. They are, however, two separate incidents, which affected two different evacuation services (Medical Military Aid in the first case, and PRCS in the second).

3.1.2 Failure of coordination mechanisms

PRCS staff reported that, before the war, coordination for evacuation of injured people from an Israeli attack to hospitals in Gaza typically took 10-20 minutes, using the International Committee of the Red Cross (ICRC) as an intermediary. During this armed conflict, however, evacuation coordination took up to 10 hours on average. In extreme cases it took 7-8 days, as in the attacks on Khuza'a,⁸¹ or failed completely. On many occasions, ambulances were attacked despite coordination having been approved in advance through the ICRC.

A paramedic interviewed by the team, Yousef Al Kahlout,⁸² added:

The risks and the attacks we were subjected to during this war were much more serious than any previous one. Normally we follow strictly the rule: 'protect yourself, protect the place.' We wouldn't go out without coordination. But this time too often coordination took ages or failed to arrive, so we were going out in any case, even if we were aware that we were putting our lives at risk. We would wait for long minutes, sometimes hours, awaiting coordination, and people kept calling and pleading for evacuation, we could hear them crying for help. We knew they were bleeding, dying... so very often we couldn't wait and just went off [to assist them].

According to PRCS staff, in the first attack with multiple casualties at Shuja'iya in eastern Gaza on 20 July 2014,⁸³ PRCS requests for access to evacuate the wounded were denied and ambulances became targets. The Ministry of Interior ambulance doctor interviewed by the team reported similar difficulties:⁸⁴

On Sunday 20 July 2014 at 12:30 we received the first call from Shuja'iya, to Ben Taji Street, where there were reported casualties and injured people in the streets and in the houses. We called ICRC for coordination but the answer was negative.

⁷⁹ Available at <https://www.youtube.com/watch?v=HqBZ-JoxhQY> (warning: graphic). Accessed 30 Nov 2014. During the first two minutes of the video, 11 consecutive explosions can be heard, at intervals of 10-15 seconds.

⁸⁰ Interview sortcode MED2, reported in full in Appendix 1

⁸¹ For detail on this see Part C. 'Khuza'a - focus and site visit'

⁸² Interviewed by the second FFM team in his home. Full testimony at interview sortcode MED1.

⁸³ PRCS coordinator in Gaza City, 19 Aug 2014, interviewed by the first FFM team.

⁸⁴ Dr. Diab Al Din Muhammad Abu Hussein, interviewed by the second FFM team on 9 Sep 2014 at the offices of Al Mezan Center for Human Rights in Gaza City.

They said that the Israeli army were not granting coordination for evacuation of the area. Four (4) ambulances from our service went off anyway and tried to reach the place without coordination.

PRCS office staff related the details of additional cases in which, despite prior coordination with the Israeli army via the ICRC, ambulance teams were attacked and killed. One of these cases involved evacuation from Beit Hanoun in northern Gaza on 25 July 2014:⁸⁵

A PRCS ambulance was stationed at Beit Hanoun Hospital, a governmental hospital, during the days of the attack. On the day of the incident the emergency team was called by civilians to a nearby house where they reported four people with injuries. The distance between the house and the hospital was around 200 meters. The team received a 'green light' from ICRC to evacuate, had coordinated the evacuation with the Israeli military, and were with the ICRC on the phone when the team reached the place and began to open the doors of the ambulance. They were hit by a drone missile that set the ambulance on fire. The two injured paramedics managed to go back to the hospital through back roads but one paramedic, Aed Al Burai, was left behind. They then tried to evacuate him, sending a convoy of three ambulances to the site, but as soon as they reached it, there was heavy shooting. The first ambulance was hit by ten bullets and the driver was injured and left the area. The next day there was a humanitarian cease fire from 08:00, and PRCS teams went back and finally recovered the charred corpse of the paramedic, who had been burnt to death. Thereafter the PRCS withdrew its station at Beit Hanoun.

3.2 Attacks on medical facilities

According to the Health Cluster Report⁸⁶ 17 hospitals and 56 Primary Healthcare Centres were either destroyed or damaged during the attack. Full details regarding the impact of this damage are provided in that report.

Mahmoud Daher, head of the local WHO sub-office in Gaza,⁸⁷ described the atmosphere of threat and panic in the hospitals in Gaza during this war. According to Mr. Daher the Israeli military had been given the GIS coordinates of all hospitals specifically to prevent targeting. 'Wiki maps'⁸⁸ had been used to determine exact locations of health-care facilities. More than 50 facilities were on the list of coordinates; nonetheless, many of these marked public clinics, NGOs, and primary healthcare centres were damaged by shelling. An additional problem was the safety of staff trying to reach hospitals to relieve others who were working extended shifts.

⁸⁵ PRCS coordinator in Gaza City, 19 Aug 2014, interviewed by the first FFM team. See also ICRC statement on the event, dated 25 July 2014: <https://www.icrc.org/eng/resources/documents/news-release/2014/07-25-gaza-volunteer-killed.htm> accessed 24 Nov 2014.

⁸⁶ Health Cluster Report, p10.

⁸⁷ Interviewed by the second FFM team on 10 and 11 Sep 2014.

⁸⁸ Probably this is a reference to www.openstreetmap.org, also known as 'the free wiki world map.'



Damage to Shuhada' Al Aqsa Hospital, Deir Al Balah. Photo by Anne Paq, 26 Jul 2014

As an example of a direct attack on a medical facility, Mr Daher mentioned the Al Wafa Rehabilitation Hospital, destroyed by air strikes on 23 July 2014. Al Wafa Hospital was the only rehabilitation hospital in Gaza. In the course of this war, according to Mr. Daher, he believed there was an actual rocket launching site in the vicinity, but it was more than 200 meters away from the hospital.

3.2.1 The attack on Shuhada' Al Aqsa Hospital

Mahmoud Daher of the WHO office in Gaza reported that Shuhada' Al Aqsa Hospital in Deir Al Balah in Central Gaza came under attack while he was inside it, along with other international workers including local UN staff.⁸⁹ According to Mr Daher, this hospital could not have been a launching-site for rockets, judging from its structure and location. He stated that shelling started at approximately 14:30 [*on 21 July 2014-Ed.*]. The northeast parts of the 3rd and 4th floors were destroyed and 'tens of people' were injured, including a nurse on duty. Additional testimony regarding this attack was offered by MOH Information Officer Dr Abd Al Qader Lubbad, who told the team that the Israeli army attacked two refugee camps nearby, on the 'right side' of Salah al Din, the main road. Residents of the camp moved to the left side of the street where the hospital was, and entered the hospital thinking it would be safe. The hospital was then bombed in an attack that killed and injured 'several' people.⁹⁰

The FFM teams obtained separate first-hand testimony on this attack on Shuhada' al Aqsa Hospital, from the above-mentioned nurse who had been on duty and was injured

⁸⁹ See ICRC statement on the attack at <https://www.icrc.org/eng/resources/documents/news-release/2014/07-21-gaza-al-aqsa-hospital.htm> accessed 24 Nov 2014.

⁹⁰ Interview held 20 Aug 2014 Shifa Hospital by the first FFM Team. According to media and human rights reports 3 people were killed (inside the hospital itself), and about 40 people were injured in the incident. See e.g., AlHaq report of 25 Jul 2014, available at <http://www.alhaq.org/advocacy/topics/gaza/831-targeting-of-health-facilities-in-the-gaza-strip-may-amount-to-war-crimes> accessed 7 Dec 2014.

in the course of the attack.⁹¹ Her testimony regarding the attack is reproduced here:

Testimony of Iman Hassan Hashem Al Katrawi, 32, nurse injured in the attack on Shuhada' Al Aqsa Hospital on 21 July 2014

The 'patient' was on duty during her regular shift as a nurse. On the day of the incident, she went to work as usual by public transport to Shuhada' Al Aqsa Hospital. Shortly after her arrival at 14:00, heavy shooting started around the hospital. From the balcony she saw some cars belonging to the _____ family,⁹² who were carrying a 'martyr' [description given to anyone killed in attacks by Israel-Ed.] to the hospital. Two cars were shelled just in front of the hospital and four people were killed in this incident. The hospital was then hit 15 times in quick succession by tank strikes. The first missile hit the male surgery ward. Staff and visitors started immediately evacuating the patients, as the shooting (sic) continued. Four other people were killed: two patients and two visitors. The patient [nurse-Ed.] felt a sharp pain in her right arm and saw fire coming out from it. She supported this arm with her left hand and ran for her life. Some colleagues helped her down the stairs and a doctor put out the fire. Only then did she see a big piece of shrapnel stuck to her arm.⁹³ She was taken to ER and doctors decided to amputate her arm. Because of the attacks, all patients admitted to the hospital, together with their families and staff members took refuge in the Emergency Room, on the ground floor, while the injured from the attacks were referred to Nasser Hospital in Khan Younis. The journey to the referral hospital was difficult and dangerous because of heavy shooting on the streets around them. She arrived in shock at the Emergency Room of Nasser Hospital. A foreign doctor from the European Hospital who was there at the time (she can't remember his name) performed an arterioplasty [arterial reconstruction] using the saphenous vein from her right leg. The operation was successful and saved her arm from amputation, but a good amount of bone, nerve and muscle tissue was missing, so she was put in external fixation and sent back to Al Aqsa hospital on 22 July 2014. During the return trip, the ambulance, carrying 7 patients, came under fire twice, while passing by a biscuit factory, which was completely destroyed in the course of the attack. According to this nurse's testimony, at least eight people were killed in the course of the attack on the hospital.

The FFM teams were unable to visit the Shuhada' Al Aqsa Hospital and thus examine evidence on site. Whilst the precise number of casualties would be important to corroborate, what is important here is that a hospital was attacked by the Israeli military while patients were admitted, health professionals were at work and civilians were seeking refuge from attacks in the surrounding area. Unfortunately, the hospital was no safe haven.

⁹¹ Interviewed by AV while hospitalised in Amman, Jordan, on 30 Aug 2014. Her full interview including details regarding her evacuation out of Gaza, can be found in Appendix 1 at interview sortcode J6.

⁹² Name of family redacted as the team did not secure their consent for publication.

⁹³ During the interview the interviewer was shown the piece of shrapnel, which weighed about 1kg. The injury of the patient was consistent with shrapnel of this size and mass. For relevant photographs see interview sortcode J6.



Casualties arrive at Shifa Hospital, Gaza City, after an attack on people digging graves for their relatives in the cemetery. Photo by AV, 20 Aug 2014

4. Other causes of death and injury


4.1 Attacks on cemeteries

The first FFM team were witness to the results of an attack on a cemetery during their visit. They were present at the time the casualties from this attack were brought to the Emergency Department of Shifa Hospital in Gaza City:

On the morning of 21 August 2014, at about 09:15, the Emergency Department at Shifa Hospital received notification that several men who were digging the graves for relatives who had just been killed were themselves attacked and were being evacuated to the Emergency Department. The scene that followed, although stressful, was orderly and well-organized with paramedic teams, some youth from an Eagle Scout troop as well as others who were volunteers from Jordan, receiving the dead and wounded from the ambulances as they arrived. In total, there were six incoming ambulances—each bearing a different insignia—some carrying two people. The paramedics were wearing gloves but the stretchers were ‘recycled’ without being cleaned in between, still bearing the blood of the wounded who had been transported before them. The team later witnessed several of those who were killed being wheeled on stretchers from the Emergency Department, wrapped in white shrouds, their bodies to be handed over to their families for immediate burial.⁹⁴

The consequences of another attack on a cemetery were observed by FFM team member AV when she visited Gaza for the third time, on 11–12 November 2014. On

⁹⁴ For a media item describing the incident see Maan News, 21 Aug 2014, at <http://www.maannews.net/eng/ViewDetails.aspx?ID=722250> accessed 24 Nov 2014.



Flechette dart shown to first FFM team at Shifa Hospital. Photo by Ö Ö, 20 Aug 2014.



Flechette found in Khuza'a, shown to AV by Dr. Kamal Qdeih in his clinic. Photo by AV, 12 Nov 2014.



Bomb fragment with Motorola logo visible, shown to first FFM team at Shifa Hospital. Photo by Ö Ö, 20 Aug 2014.

her journey from Abasan al Kabir⁹⁵ to Khuza'a she was taken by a resident of Abasan Al Kabir, Safwat Abu Daka,⁹⁶ to the site of a cemetery that had been attacked and badly damaged. Part of the cemetery, a private burial ground belonging to the Abu Daka family, was severely damaged, first by bombs and later by bulldozers. Some of the graves were destroyed and, according to the witness, human remains were exposed for several days. Since the Abu Daka family were displaced from their homes during the attacks in this area, they were not sure exactly when the cemetery attack had happened, but they were certain it was between 24-27 July 2014. Only after the war was over could they return, and, on 28 August 2014, they discovered the damage and reburied the remains of family members in new graves. The witness also reported second-hand information he had received regarding the context of this attack, according to which an abandoned building close by the cemetery,⁹⁷ which was completely destroyed during this war, was said to have been full of explosives; fifteen (15) Israeli soldiers were rumoured to have been killed inside this building as a result. This statement could not be verified by the FFM teams.

4.2 Allegations regarding irregular weapons

In meetings with the FFM teams, members of the Forensic Department at Shifa Hospital in Gaza City and the General Administrative Director of Shifa Hospital in

⁹⁵ The home of Samia Abu Daka, a key witness to the events in Khuza'a between 21-25 July 2014, see Part C below, and interview sortcode EJJ15.

⁹⁶ The husband of Samia Abu Daka, see previous note above.

⁹⁷ According to the witness, the building had been designated by donation from the Abu Daka family for use as a clinic branch of Maqassad Hospital in East Jerusalem, prior to the Hamas takeover of the Gaza Strip in 2007. The project was discontinued and the building was abandoned.



Bomb fragment shown to first FFM team at Shifa Hospital. Photo by HPH, 9 Sep 2014.



Bomb fragment shown to first FFM team at Shifa Hospital. Photo by HPH, 9 Sep 2014.

Gaza City, Dr. Subhi A-Skeek and Dr. Hamdi Kahlawi⁹⁹ stated that, although there was no evidence for the use of white phosphorus⁹⁹ in this attack, they reported several phenomena they saw as strange or inexplicable. These were recorded by the team and ranged from the use of flechettes to other, less clearly identifiable weapons. The team could not independently verify any of these reports, but they are detailed here verbatim as described to the team:

1. Dr. Nasser Abu Sha'aban,¹⁰⁰ interviewed at Shifa Hospital in Gaza City, reported that anti-personnel munitions – flechettes – were used during this attack and showed the teams examples of the munitions to support this allegation. A separate allegation regarding their use was made by a doctor during a patient interview at Shifa Hospital,¹⁰¹ when the treating doctor, Awad Shedar, a 4th year medical student at the Islamic University, told the interviewers that he had evidence of three patients who presented to the emergency department with flechette wounds at Shifa Hospital. He showed the interviewers photographs as well as X-ray images on his iPad. In one case, the flechette had entered the male patient's left inferior orbit at an angle that also perforated his maxillary sinus and palate on the same side. Surgery was performed on the patient and the flechette removed from inside his mouth – it had entered back to front – without loss of his eye or permanent disability. He stated that the two other patients

⁹⁸ Interview held on 20 Aug 2014 by the first FFM team.

⁹⁹ Used in the previous attack of 2008-2009. See PHR-Israel and PMRS 2009 fact finding report, April 2009, at <http://www.pmr.ps/userfiles/20100531171612.pdf>, accessed 23 Nov 2014.

¹⁰⁰ Interview held on 20 Aug 2014 by the first FFM team.

¹⁰¹ Interview held at Shifa Hospital on 20 Aug 2014 by AV and LBR. See interview sortcode GS3.

did not survive. The student was not willing to share these images, since he hopes to publish that particular case with his professor. One other allegation regarding use of flechettes was made at Khuza'a, where the second FFM team were shown flechette darts by Dr. Kamal Qdeih, a local private doctor, in his clinic. However, these were not embedded in walls but lying on the floor.¹⁰²

2. Unusual burns. Patients arriving 'charred' with blackened exposed surface area of their bodies but skin intact. Unusually, the bodies did not smell of burnt flesh.
3. Unusual amputations. Black 'tattooing' around the stumps of amputees (both unilateral and bilateral) in a spray-like fashion; and 'clean' amputations, almost like cauterization, with the vital signs of patients surprisingly stable. There were no foreign bodies in the wounds, leading to a suspicion of the use of Dense Inert Metal Explosives (DIME).¹⁰³
4. 'Computer chips' with Sony markings embedded as shrapnel in people's bodies.¹⁰⁴
5. The possibility of a gas of unknown type being used, particularly in Khan Younis, southern Gaza. At Nasser Hospital, at least 50 people were admitted for respiratory symptoms and shortness of breath because of gas exposure: 'The whole of Gaza was smelling. A sewage-like smell was described along with burning sensations of exposed skin. The gas was white-colored. Even 500 meters from Shifa Hospital, there were fumes and smells.'¹⁰⁵ During their site visit to Khuza'a in southern Gaza, the second FFM team heard of extensive use of teargas causing a 'thick fog' and similar respiratory symptoms. However, this was regular, odourless teargas, spread by teargas canisters.¹⁰⁶

The forensic experts from the two FFM teams can make no further comment on the above observations because none of the tissue samples taken in the possession of the forensic experts of the Ministry of Justice of Gaza were taken out of Gaza for further toxicological, biological or chemical examinations to confirm or refute these allegations, e.g., the existence of chemical burns or of heavy metal (tungsten alloys or others) associated with DIME.

5. Experiences of evacuation, medical management and referral

5.1 Evacuation in Gaza: unsafe routes

In the patient interviews, 27 of the patients interviewed described arrival of evacuation or help at the place of injury as 'prompt' or under 15 minutes; in 8 cases

¹⁰² For full details of events at Khuza'a see below, Part C.

¹⁰³ Similar 'clean' amputations were reported regarding victims of drone attacks in 2008-2009. The evidence regarding this is reported in the PHR-I/PMRS fact-finding mission report of 2009 at p75. Report available at <http://www.pmr.ps/userfiles/20100531171612.pdf> accessed 23 Nov 2014.

¹⁰⁴ Although Sony was cited, the team was shown remains of explosives with the Motorola logo embossed in them. It is unclear what these remains are and which patients they were associated with, and the team could not ascertain their source.

¹⁰⁵ The team received a separate testimony from a paramedic who evacuated injured from an attack in Mujama'a Street, Gaza City, on 'the last day of Ramadan'. He reported 'smelly smoke' which people feared. See interview sortcode MED1 for the full interview. A chemical smell following a strike was also mentioned by a patient, at interview sortcode EJM4.

¹⁰⁶ Visit to Khuza'a, second FFM team 10 Sep 2014.

evacuation took 15-30 minutes; in 12 cases evacuation took more than 30 minutes; in other cases the evacuation time is unknown. However, 15 patients reported that the ambulances evacuating them were delayed or obstructed by coming under fire (details regarding the specific context were not provided) during their journey from the place of injury to the nearest hospital. In 3 cases ambulances were obstructed for other reasons such as damage to the roads or rubble and debris from fallen buildings. The reason for the frequently reported rapid arrival of evacuating teams may be partly related to the information provided to the team by a PRCS coordinator, who explained that the emergency services attempted to prepare for the attacks by distributing ambulances to strategic places, hoping to decrease response time and be present even when injured people were unable to call for help because of electricity and communication failures.¹⁰⁷

Among the hospitalised patients interviewed, 3 reported that their ambulances came under fire¹⁰⁸ while transporting them from Gaza hospitals to Erez Crossing for referral to external hospitals.

5.2 Medical management of the injured in Gaza: severe overload on hospitals

According to medical professionals interviewed by the FFM teams,¹⁰⁹ all hospitals cancelled elective surgery and stock-piled supplies in anticipation of possible mass casualties in the period leading up to the war.¹¹⁰ Despite this preparatory work, the flood of injuries from the beginning of the war proved overwhelming and the hospitals simply could not cope. As an illustration of this, Mahmoud Daher of the WHO described one day early in the war when he was at Shifa Hospital in Gaza City: he witnessed 240 injured patients being delivered to emergency within 30 minutes. This occurred one evening between 18:30 and 19:30 during 'the short ceasefire,' when the [30 July 2014] marketplace attack in the Shuja'iya neighbourhood in eastern Gaza City occurred.¹¹¹ Bedlam ensued. All hospital staff were called to the emergency area to help but the triage system was inadequate because of the limited number of staff and the limited space. Attempts at triage were rough and performed outside on mattresses on the ground; people were lying on the floor in the hallway between the emergency department and the ICU. Moreover, Mr Daher commented, physicians' training and clinical judgment were variable and there was considerable interference

¹⁰⁷ See Chapter 3, 'Attacks on medical personnel and medical facilities'. Unfortunately, as stated there, although this preparation did shorten response times, it also exposed health care workers to the dangers of the 'double tap' pattern of attack.

¹⁰⁸ No details were provided regarding the context of these attacks, whether they were aimed at the ambulances or crossfire.

¹⁰⁹ Interviews with Dr. Muhammad Al Kashef FRCSI - General Director International Cooperation Department, Ministry of Health, Gaza, 19 Aug 2014 (first FFM team); Dr. Ambrogio Manenti and other WHO staff at East Jerusalem office, 10 Sep 2014 (JL); Mahmoud Daher, head of WHO office in Gaza (telephone interview 10 Sep 2014, JL; meeting and interview 11 Sep 2014, second FFM team).

¹¹⁰ This is probably because the Israeli operation in the West Bank, which preceded the attacks on Gaza, focused on Hamas infrastructure. An escalation in Gaza was therefore predictable.

¹¹¹ The ceasefire and attack were on 30 July 2014. See Chapter 3 above, and interviews referred to there.

from patients' families and friends, although he did not observe 'political' interference or special treatment being provided.¹¹² The armed blue uniformed police tried to maintain order outside in the triage area but it was very difficult and not terribly successful. In addition, there were a number of displaced people in the area¹¹³ making the scene very difficult to control. In sum, the volume of patients in this mass attack was simply too great for adequate care to be administered in a timely fashion. Thus he surmised that people may have died because of imperfect triage and/or improper or delayed care. He mentioned examples of people brought to the morgue after which it turned out that they were alive and they had to be resuscitated.¹¹⁴

In addition, casualties and injuries were not well documented in patient files because of the stress and rapidity of the influx of wounded persons into the hospitals.

When treating patients during mass casualty events, Mr Daher reported that surgeons were working under a burden of heavy casualties and with insufficient supplies. In his opinion at particular moments of overload they took medically unsatisfactory shortcuts: they stopped using sterile gloves and resorted to non-sterile ones; they had to use suture material unsuitable for the types of wounds; and there was not enough sterile gauze.

Corroboration by the FFM teams of the events described above was not possible. Other problems were reported by WHO staff¹¹⁵ regarding the European Hospital in Khan Younis in southern Gaza, the second most advanced tertiary centre after Shifa Hospital. All patients injured in Rafah were referred there. There were very heavy casualties in this area, and the hospital was not prepared for the volume of patients. For many reasons, including being short staffed (as many staff could not safely travel to work), and concern for their families at home, staff morale was low. Other concerns included damage to the hospital, supply shortage and lack of water and electricity because of damage to infrastructure. The hospital went at least one day without food. Hospital staff were 'really overwhelmed' as they attempted to cope with large numbers of patients who had complex injuries. According WHO staff, when they went back to check on patients at this hospital after one week they found that some of their wounds had not been re-dressed. Maggots were swarming in the wounds.

This report from local WHO staff is partly corroborated by one interview held by the FFM teams with a hospitalised patient who had been treated at the European Hospital and who testified to maggots in her wound and neglect of her dressings.¹¹⁶ Another hospitalised patient was observed by the interviewer to have maggots in

¹¹² The first FFM team did not witness overt preferential treatment being given to patients who belonged to one political party or faction over another. However, the following observations are caveats. During one visit of the first FFM team to Shifa Hospital, they were introduced to a senior Hamas official who was hospitalised alone in a room in a unit that was intended for more patients; and, several patients who were interviewed in East Jerusalem hospitals had close personal or family ties to Fatah and were successfully evacuated out of Gaza for treatment.

¹¹³ See 6.1 below.

¹¹⁴ The FFM encountered one such case in the patient interviews, described at interview sortcode J11.

¹¹⁵ Interview on 11 Sep 2014, by JL.

¹¹⁶ Interview sortcode J9, interviewed by AV in a hospital in Amman on 30 Aug 2014.

her wound after arrival at Maqassad Hospital in East Jerusalem.¹¹⁷ She had been treated at Nasser Hospital in Khan Younis.

Among the hospitalised patients interviewed by the FFM, the vast majority of patients were taken first to the nearest local hospital and then referred to a more specialised centre in the area or to Gaza's largest tertiary centre, Shifa Hospital in Gaza City, before being referred out of Gaza. This pattern of multiple referral is consistent with the sample of patients interviewed, who were ultimately referred to external medical care. In most cases however, according to the medical personnel interviewed by the teams, local hospitals discharged patients to unknown premises or to their homes after addressing their injuries. According to Mr Daher of the WHO, people were discharged from the emergency departments whenever possible because the hospitals were all overcrowded, and premature discharges from the hospital took place to make room for the acutely injured; only the most critically injured were hospitalized.¹¹⁸ Many people were discharged after external fixation of limb fractures and given no adequate instruction about when to return. Some, having nowhere to go or, fearing to return to their homes, remained displaced on Shifa Hospital grounds with their family members.

According to the medical personnel interviewed by the FFM there may have been patients who were discharged as stable but then deteriorated and died of their wounds; but the extent of this is unknown. Generally, the staff from WHO believe that people in Gaza are sophisticated about seeking medical help and would go to the public hospitals if they were having problems. The FFM teams could not verify this claim, and heard from PHR-Israel staff that, based on their experience, this pattern would not apply uniformly, especially among poorer and uninsured parts of the population in Gaza.

5.3 Evacuation and referral out of Gaza

5.3.1 Number of referrals to external hospitals

According to data from the joint operation room of the Palestinian MoH on 31 August 2014, as cited in the Health Cluster Report, 11,231 Palestinians were injured in the conflict. Of these, a total of 514 war casualties were referred outside the Gaza strip between July 10 and August 31 to the following destinations: Egypt: 245,¹¹⁹ East Jerusalem and West Bank hospitals: 149, Turkey: 83, Jordan: 34 and Germany: 3.¹²⁰

¹¹⁷ Interview sortcode EJM13.

¹¹⁸ In the patient interviews, one 10-month old child, a sibling of an interviewed patient, was discharged after preliminary care with no admission, and another patient who had a condition that was not an injury was discharged after 10 days and told this was to make way for injured patients (interview sortcodes J4 and WBN3, respectively).

¹¹⁹ According to unpublished materials collected in Egypt, patients were referred to the following hospitals in Egypt: Ahmad Maher Teaching Hospital; Dar Al Shifaa' Hospital; Al Bank Al Ahali Hospital; Palestine Hospital; Al Zaytoun Hospital; Nasser Institute Hospital; Al Zagazig University Hospital; Red Crescent Hospital; The Coast (Al Sahel) Hospital; Al Salam Hospital; Al Haram Hospital and Al Isma'iliya Hospital.

¹²⁰ Health Cluster Report p38. Mahmoud Daher of WHO, in a telephone interview on 10 Sep 2014, gave slightly different figures as follows: Patients to Jordan:32. Patients to Egypt: 264. Patients to Germany: 43. Patients to Turkey: 64. A total of approximately 600 to 640 patients sent out.

West Bank hospitals included: St Joseph Hospital in East Jerusalem, Maqassad Hospital in East Jerusalem, Najah Hospital in Nablus, a hospital in Hebron and rehabilitation centres in Ramallah and Beit Jallah. An unknown but small number of patients were referred to Israeli hospitals in Tel Aviv, Tel Hashomer and Nazareth, apparently through personal contacts rather than formal arrangements.

Compared to the 2008-2009 Gaza conflict, there was a marked difference in the ratio of referrals to total injuries. In that earlier conflict, approximately 5,000 injuries were reported, with more than 1,100 of these referred to external hospitals (a majority to Egypt and a smaller number to Israeli hospitals and to East Jerusalem). In the current conflict, referrals made up a much lower proportion of the injured.

According to Dr. Muhammad Al Kashef of the Palestinian Ministry of Health in Gaza, only 3000 of the most severely injured and in need of surgical procedures were admitted to health facilities in Gaza altogether. Since all referrals out from Gaza came through the Gaza hospitals, this figure, if accurate, could partly explain the gap in the number of referrals.

Some of the gap can also be attributed to the political changes in Egypt and the policy of disengagement from Gaza that the current Egyptian government has taken. This decision influenced other aspects of the referral process: a WHO official interviewed by the team said that at the Rafah Crossing into Egypt, even those few patients who had been allowed to cross sometimes had to wait there in ambulances for over 8 hours.¹²¹ Some patients complained to the FFM teams of grudging treatment at Egyptian hospitals.

Other explanations that limited outside referrals were related to the policies of Israeli authorities, who were strict regarding documentation and imposed stringent security checks on those family members wishing to accompany the patients. Further explanations include the lack of referrals by both Hamas authorities and the Palestinian Authority to Israeli hospitals, a policy developed after the 2008-2009 war, and possibly the wish of Hamas authorities to demonstrate independence and self-sufficiency, a sentiment that was shared by officials with members of the first FFM team.

5.3.2 Process of referral to external hospitals

In order to be referred to an external hospital the local health authorities in Gaza and Shifa Hospital liaised with the Fatah-led Palestinian Authority in Ramallah, via employees of the Palestinian Authority's Ministry of Health based in Gaza – Messrs Rifaat Mohaisen and Fathi Abu Warda in Gaza. The referral process included both medical and financial approval, and security coordination of exit permits with the Israeli authorities for transit via Erez Crossing.¹²²

¹²¹ Rafah Crossing into Egypt has been closed to all but humanitarian cases since July 2013, for political reasons. According to the Health Cluster report, the Palestinian side of Rafah terminal reported that 143 war casualties crossed to Egypt for treatment during July 2014 while 96 crossed during August for a total of 239.

¹²² All patients interviewed for this report exited via the Israeli Crossing; the mechanism for patients referred to Egypt via the

According to several patient interviews, the process for coordination was prolonged and even when approved could be delayed by several days. Each patient was accompanied by one family member who also needed security approval by the Israeli authorities.

5.3.3 Erez Crossing

Among hospitalised patients interviewed by the FFM, 23 had to wait in their ambulances between 30 minutes and 3 hours on the Gaza side of the Erez Crossing before being allowed into the security check area. One patient waited for less than 30 minutes and two patients waited for more than 3 hours. Others provided no details regarding waiting times.

Regarding security procedures at Erez Crossing

- 10 patients described the procedure as 'normal' or 'smooth'. Irrespective of this assessment, many patients reported undergoing a manual body search with gloves, collecting and testing residue (presumably for explosive residue), and a body scan with a hand-held scanner. In some cases scanners were inserted underneath the wound dressings of the patients.
- 7 patients described a body search that was extremely painful, and carried out in a way that did not take into account their severe injuries, including fractures and burns. In one case a person with bilateral leg amputations and severe injuries to his upper limbs as well as burns on the back, who was transported without clothes and only a bed-sheet to cover him, underwent a 17-minute body check that he described as painful and humiliating.¹²³
- Several patients described long waits for their exit permits to be produced at the crossing. According to two patients who travelled in the same group of ambulances bound for Jordan, an ICU ambulance in their group was refused passage at Erez Crossing and sent back to Gaza with its patient on board. The other patients in the group heard from the paramedics in their ambulances that this patient died shortly after returning to Shifa Hospital in Gaza City.¹²⁴

As regards ambulance transportation to Israel, Gaza ambulances were not permitted to exit Gaza and therefore had to transfer patients at Erez Crossing to approved ambulances with Israeli number plates.¹²⁵ These designated ambulances were either from private companies or from PRCS in East Jerusalem and had direct contact with the Palestinian Authority's Ministry of Health. The procedure for transporting patients at night was a 'back-to-back' transfer (direct transfer from ambulance to ambulance) using the same crossing. During the day, however, a 300 meter gap was imposed: Palestinian paramedics 'handed over' the patient to the waiting ambulance at the other end of the gap by wheeling them via stretcher. During all transfers,

Egyptian crossing at Rafah is not described here.

¹²³ Interview sortcode J8.

¹²⁴ Interview sortcodes J7, J8.

¹²⁵ This is standard procedure dictated by the Israeli military, despite agreements to the contrary between PRCS and the Israeli emergency evacuation services, MDA. For details see PHR-Israel reports on these procedures from 2010 and 2007, available at <http://www.phr.org.il/uploaded/Phr-israel-ambulances-jerusalem-eng-nov10.pdf> and <http://www.phr.org.il/uploaded/Entry%20of%20Palestinian%20Ambulances%20into%20East%20Jerusalem.pdf>, respectively. Accessed 23 Nov 2014.

patients would always be accompanied by a paramedic and security personnel. At no time were patients unaccompanied by paramedics, except when they were in the field hospital which was accessed via a 'special gate' (see below). This additional step in the process of transfer was lengthy and painful for patients.

5.3.4 Field hospital at Erez Crossing

Four of the hospitalised patients interviewed by the FFM teams described being asked to attend an Israeli military field hospital set up at Erez Crossing. These patients reported being asked to go to the field hospital, but only two actually attended it. One agreed to go and gave a positive report on the efforts of staff there.¹²⁶ The other was delayed for two hours at the field hospital where she was examined and encouraged to go Hadassah Hospital (an Israeli hospital in West Jerusalem) instead of to East Jerusalem, but she refused.¹²⁷ She was then questioned at the field hospital regarding the circumstances of the missile that injured her, what her opinion was regarding the attacks and why they had not evacuated their house.¹²⁸ Of the two patients who refused to attend the hospital,¹²⁹ one was allowed to continue to East Jerusalem without any problems, but the other was only allowed to continue after intervention by the ambulance driver.

WHO officials mentioned the field hospital as a 'problem' early in the war, and said it was discontinued after a few weeks. According to them, patients transferred out of Gaza were required to go through it. They could not exit until they had passed through the clinic, a fact that made patients afraid to be transferred. Some patients were asked to sign a form with unclear content in Hebrew and said that they had just signed without knowing the implications in order to get through the checkpoint. WHO officials provided an example of an 82-year-old female with multiple shrapnel injuries who was stopped for 6 hours at the checkpoint. The ambulance which transported her was forced to go to the field hospital before being allowed through. Medically, the WHO officials called the field hospital 'a joke', with no equipment for advanced care, a waste of time whose sole purpose was to implement a process for control.

Drivers from a private ambulance company that transported 70 patients from Gaza to external hospitals in East Jerusalem and the West Bank during this war also reported information about the field hospital.¹³⁰ They said they were 'forced to take patients there and leave them there against our will,' on 3 or 4 occasions. Twice, it took more than 2 hours for the patients to come out of the hospital. Their experience was that Israeli officials would check the patients for at least one hour, sometimes 2-3 hours.

¹²⁶ Interview sortcode EJM12/EJM16.

¹²⁷ The ambulance driver who was with the patient at the interview explained to the team that there was no financial coverage from the Palestinian MoH for hospitals other than the one she had been referred to.

¹²⁸ Interview sortcode EJM17.

¹²⁹ Interview sortcodes WBNG, EJM19.

¹³⁰ Interview held 22 Aug 2014 with 'Qalb al Medina'/'Lev Ha'ir' ambulance company in East Jerusalem, at their offices in Al Shayyah St, Al Tur. Interviewees included the owners, Sami and his two brothers, Muhammad, who is an EMT level 2 qualified paramedic/ambulance driver, and a second brother who is a medical doctor from Beersheba, and an additional ambulance driver. Interviewed by the first FFM team and PHR-Israel staff.

According to the ambulance drivers, patients reported there was no treatment, medical procedure or dressing change administered, and the health professionals of the hospital were in military uniform. The drivers could not stay with their patients. The drivers said they thought it was a 'kind of interrogation.' According to the drivers, some patients also reported that they had been asked about where the rockets had come from during an attack, and the location of the resistance. An ambulance driver from East Jerusalem contracted to transport in-coming patients from Gaza complained on one occasion to Israeli soldiers because he had waited 5-6 hours and then 2 hours more until the patient came out of the field hospital, and this was a 'burnt, fractured and ambu-bagged [*manually resuscitated-Ed.*]' patient. The next day someone from the Israeli army replied that he should not complain since they could 'make him receive no more referrals from Erez in the future'. However, possibly as a result of this complaint, this field hospital was then discontinued. It was early in the war.

Three patients interviewed by the FFM teams reported that photos were taken of them at the crossing. In one case a photo was taken despite the patient's objection; the other two cases were of minors (both girls, aged 7 and 15).

On 14 August 2014, PHR-Israel wrote to the Israeli coordinator of operations in the Occupied Territories requesting information about allegations regarding the field hospital, and details about its function. On 21 October 2014 Captain Elad Rahamim from the office of the Coordinator of Government Operations in the [occupied] Territories in the Israeli Ministry of Defence responded. The following are translated extracts from his letter:

- '...A total of 51 residents of the Gaza Strip arrived at the temporary [field] hospital; of these, 34 were then referred to continued care in Israeli hospitals (including East Jerusalem and the West Bank [*sic*]). [*The letter does not specify whether the remaining 17 patients were required to return to Gaza-Ed.*]
- The main purpose of the treatment offered at the hospital was provision of preliminary medical response, such as changing of dressings and certain medications, because of the length of the journey from Gaza to Israel or to the West Bank;
- [*Regarding the nature of the form patients were required to sign-Ed.*], the form mentioned in your letter is an informed consent form for treatment [*language not specified-Ed.*], whose aim was to ascertain consent of all patients to receiving treatment. Signing the form was part of the admittance procedure for all patients at the hospital;
- [*Regarding whether photographs were taken of patients, and for what purpose-Ed.*], most of the photographs taken at the hospital were taken for internal documentation purposes (*sic*). In all cases in which any use was made of the photographs, such as distribution by the IDF, their faces [*misspelt as 'sons' in Hebrew-Ed.*] were blurred...'¹³¹

¹³¹ Original letter in Hebrew retained at PHR-Israel's office.



IDPs against backdrop of destroyed building, Beit Lahiya, north Gaza. Photo by LR, 10 Sep 2014.



IDP tents on the site of residential destruction, Gaza City. Photo by HPH, 8 Sep 2014.

5.4 Evacuation of Israeli soldiers during the war

The team interviewed two doctors in the Israeli army,¹³² who served together in a reserve unit on the Israeli side of the border, responsible for evacuation of wounded Israeli soldiers to hospitals in Israel.

They explained that there are 4-6 medical doctors in units of 3000-4000 men. Since 2006, the IDF implemented a policy of 'scoop and carry' rather than treat in the field, if the hospital option was close and if the patient's airway and breathing were secure. They connect by radio or phone with the field and with hospitals and transport; the soldiers are evacuated to the border and then the doctors and their units move them into different ambulances for transport into Israel by the fastest route.¹³³ Helicopter rescue is also possible; the field unit usually decides about evacuation plans and interacts with different hospitals.

There were 5-6 mass casualty incidents in this war; twice they had more than 15 wounded soldiers at the same time having to be moved very quickly.

They explained that another set of units and physicians evacuated hundreds of prisoners of war (POWs) from this conflict, who were first treated in military field hospitals if needed, but they stated that most were not wounded; they were then sent to Israel by vehicle and helicopter. Occasionally, a wounded Palestinian civilian would come to the border where the Israeli doctors would take treat and evacuate him out if possible, but this was very rare.

According to these reservists, when interviewed some weeks after the ceasefire,

¹³² Interview held on 7 Sep 2014 by JL, with M, a Lt Colonel in Reserves; and F, officer in IDF reserves.

¹³³ Although all land crossings into Gaza except Erez Crossing have been closed to Palestinians for several years, they are available to the Israeli military.

the level of violence and threat in this recent conflict was 'five times worse' than Operation Cast Lead, and even the Second Lebanon War (2006-Ed.). One of them said he would have to go back to the First Lebanon War in the 1980s to find this level of intensity, casualties and weapons use. The war had been very intense for them and for the border units in general; it was extremely noisy all the time with fear of rockets and shells; and, they experienced severe fatigue from the strain and had great difficulty sleeping. They reported feeling that there was no really safe place to be and imagined that there would be a lot of mental health issues subsequently among the soldiers. They were still feeling the stress many days after their assignment in the field of operations was over.

In their view, the situation is getting worse: the Palestinian level of discontent higher and the Israeli military personnel they interacted with more frustrated. The general sentiment they described is that this conflict cannot be won militarily.

6. Longer term impact of the war

6.1 Destruction of homes and long-term displacement

According to UN sources, an estimated 18,000 homes were completely or partially destroyed, and more than 500,000 people were displaced during the armed conflict.¹³⁴ According to the Health Cluster Report, as of the end of September 2014, 60,000

¹³⁴ UN OCHA Gaza Initial Rapid Assessment 27 Aug 2014, available at <http://unispal.un.org/UNISPAL.NSF/0/F5F968C3F38D8D2785257D4F004A26B6#sthash.yRtK9Qvd.dpuf> accessed 24 Nov 2014



IDP tents in Shifa Hospital grounds, Gaza City. Photo by ÖÖ, 20 Aug 2014

people were still living in UNRWA facilities, defined as temporary shelters. An estimated 40,000 others were displaced elsewhere - living with relatives, in rented accommodation or in the ruins of their homes. These people can expect to remain displaced for the long-term because of the destruction of their homes or the loss of a livelihood in their neighbourhoods.¹³⁵

Of the 68 patients interviewed, many had been displaced as a result of the attacks. Twenty-eight (28) reported the total or partial destruction of their homes as a result of the incident that had injured them. Four others reported the destruction of their homes in an incident separate from that which had injured them.

The FFM teams visited sites of mass destruction in residential neighbourhoods. On an 8 September 2014 visit, the second FFM team witnessed residential areas in Beit Lahiya, Beit Hanoun and Jabalia that have suffered irreparable damage. In Beit Lahiya, a densely populated area, Al Nada Towers is now only an empty shell with most walls demolished and mountains of debris. At the sites of the Italian Tower, Al Basha Tower, Zofer Tower and Salam Tower, similar scenes of devastation were recorded.

The two Gaza visits by the FFM teams provided an opportunity to monitor the situation of internally displaced persons (IDPs) over time. During the first FFM team's visit to Gaza on 20 August 2014, while the attacks were on-going, team members witnessed large families living in improvised dwellings in the Shifa Hospital grounds in Gaza City. They discussed the situation with Dr. Subhi A-Skeek, who corroborated significant numbers of displaced people living there, in conditions he described as catastrophic and a serious strain on the hospital infrastructure. These displaced people were using toilets and showers inside the hospital, while sleeping/eating

¹³⁵ Ibid

outside on the grounds; other IDPs also tried to make beds inside hospital corridors and stairwells. The first FFM team observed very harsh living conditions among these displaced people, and noted that several of them seemed injured or ill, in conditions that would have otherwise merited hospitalisation.

By the time of the second FFM team's visit in early September, most of these displaced people had vanished, presumably having returned to their homes or to the sites of their destruction, or having found other solutions.

The second team interviewed internally displaced persons (IDPs) in the community, in Tel Al Hawa neighbourhood in Gaza City.

One of the IDPs, Fadi Abu Awuda,¹³⁶ age 42, was displaced from Beit Hanoun in northern Gaza to a rented house at Tel Al Hawa, where the interview took place. His testimony, summarised below, illustrates the difficulties of displaced people in areas that suffered widespread destruction, who often could not remain in their neighbourhoods even with relatives, because of the destruction of several adjacent buildings at a time:

The interviewee is a private accountant working mainly with private businesses and companies. His work was completely interrupted during and after the war, as there was no possible economic activity under the attacks.

He comes from a poor, traditional, extended family, and worked very hard all his life to build a beautiful house and to be able to offer his two children the kind of life he never had during his childhood. His house cost around \$90,000; one third of its mortgage remains.

He underlines several times during the interview that his house was far from any military front and far from the border with Israel. There were no rocket launchers and no known militant residents in the area, therefore there was no reason for an attack on this area. Personally, too, he does not have any political activity or affiliation. His only interest in life has been securing the future of his family.

His house was attacked on 10 July 2014 during severe random neighbourhood shooting from [Israeli] tanks and planes. They were warned by phone (a recorded message) to evacuate the area and so they did. When they could finally return to evaluate the damage, they found that their home had been completely levelled in the attack.

There were 4 family members living in the house: himself, his wife, a daughter (aged 7) and a son (aged 4). After their displacement, he rented a house for his family in Tal al Hawa because he thought it was for a short period and he could afford the high rents of the neighbourhood (one of the fanciest in the city). He pays \$400 per month for the rental. Seven houses belonging to his siblings were also destroyed. However, his brothers could not afford to pay rent, so they are all displaced and living in UNRWA schools.

He is planning to move back to the same neighbourhood (Beit Hanoun) now that the danger is over. He wants his children to continue to attend the same school.

¹³⁶ Interview held 8 Sep 2014, by HPH, AV and Marwan Diab of the local NGO GCMHP.



Hazardous destruction sites in Beit Lahiya, north Gaza. Photos by HPH, 8 Sep 2014

Beit Hanoun is also a cheaper area, despite the fact that the housing and rental prices have doubled since the devastation of vast neighbourhood areas.

Access to adequate housing and healthy environmental conditions are key underlying social determinants of health.¹³⁷ The conditions described above can be expected to adversely impact the health of IDPs and their broader communities, as well as that of people living near the sites of destruction over the long term.

6.2 Hazardous sites

In response to the destruction of their homes, some families have returned to the site of these destroyed buildings for lack of better alternatives, or because they cannot afford substitute housing due to the cost of rent, which has been inflated since the conflict. Some families are living in temporary on-site tents. Others are living in the remains of their homes. Adults were observed roaming and children playing among the rubble. One of the patients interviewed by the team¹³⁸ was a four-year-old child who had been injured while playing in the rubble after houses in his neighbourhood in Jabalia, northern Gaza, were destroyed in attacks.

The FFM teams observed people who were still living in the higher flats of partially destroyed structures, with obvious risk to their safety.

The team visited Dr. Hamdi Kahlawi, of the Forensic Department at the morgue of Shifa Hospital in Gaza City on 11 September 2014.¹³⁹ The body of a child wrapped

¹³⁷ UN CESCR General Comment No. 14, 2000, available at <http://www.refworld.org/publisher/CESCR/GENERAL/4538838d00.html>, accessed 24 Nov 2014.

¹³⁸ Interview sortcode EJM9.

¹³⁹ Interview held by the second FFM team.



Body of small child killed playing in rubble, in morgue of Shifa Hospital. Photo by LR, 11 Sep 2014

in white cloth was lying on one of the two autopsy tables when they entered the morgue. When asked if it was an accident since the cloth was soaked with blood at the back of the child's head, he responded that the deceased was a 2.5-year-old girl who had been playing in the remains of a shelled house when a door suddenly fell onto her and she died. He did not explain whether she had died immediately or in the hospital. He showed the team a part of the child's head and face and they observed a bandaged laceration with surrounding bruise on the top of the head.

According to UN sources, there are thousands of Explosive Remnants of War (ERWs) throughout the Gaza Strip following the conflict of July-August 2014, representing a daily safety risk as well as an obstacle to the return of IDPs.

An IDP interviewed by the second FFM team said that his family found 10 shells among the rubble of their destroyed home in Tel Al Hawa, Gaza City, as well as one unexploded F16 bomb.¹⁴⁰ They notified the relevant bomb squad unit, but it took one month for them to come and defuse it.

6.3 Psychosocial and mental health impact of the armed conflict, with focus on minors

The majority of the 68 hospitalized patients interviewed by the team exhibited emotional symptoms of post-traumatic stress disorder (PTSD) to varying degrees, including insomnia, flashbacks, nightmares, screaming, loss of appetite, weight loss, depression and labile emotional states.

¹⁴⁰ Fadi Abu Awuda, interviewed 8 Sep 2014 by the second FFM team.

In an interview, the Head Nurse of the Emergency Department at Shifa Hospital in Gaza City¹⁴¹ expressed fear of the long-term psychological effects of the attacks on the population—not only because of the loss of their homes and displacement but also because of threats to their jobs, businesses, ability to work and study and generally have a ‘normal’ life or raise their families in a safe and secure atmosphere. He stressed that this current war takes place within the context of the closure of Gaza and is aggravated by the impression that the whole world is looking at Gaza and ‘doing nothing.’ In an interview with the first FFM team, the director of the Palestinian Center for Human Rights, Raji Sourani echoed this last sentiment, saying, ‘They [the Israeli army] are immune. Europe is collaborating in this regard by letting them do this.’

Feeling cut off from the rest of the world during this latest war was psychologically challenging for many people the FFM encountered. The teams were questioned repeatedly about what they were doing to stop the war in the context of anger, frustration and demoralization. Many felt that ‘another report’ documenting their pain and suffering would be ineffective in addressing the root causes of the morbidity and mortality they experience daily.

The Head Nurse stated that on a personal level his main concern coming to work every day, as well as that of his staff, is leaving their wives and children at home:

While [we] spend most of our time here in the hospital, we leave our families at home, unprotected. I don’t know how to secure them, how to take them to a safe place.

According to the same interviewee, these mental health issues have gendered aspects:

In this traditional society, where men are the providers of support and protection for their families, their inability to do so is creating a significant amount of stress and depression among men in Gaza. It also causes secondary problems, such as violence and a serious sense of insecurity in children when they cannot turn to their fathers as protectors, providers and heads of the family. Everyone feels powerless as they cannot provide financial or emotional security in the usual ways. As these feelings break a very deep bond between fathers and children and destabilize the ‘natural order,’ the attacks can be characterized as ‘psychological warfare.’ We don’t know the long-term consequences of these attacks on our younger generations. A study on this issue, regarding the humiliation of the fathers in front of their children at checkpoints in the West Bank after the second intifada showed that this ‘broken bond’ with fathers often leads to the proliferation of gangs, violence and drugs.

The conflict results in mental health problems not only for men, but also for some young women, who are now finding it difficult to get married. They don’t want to have children in this situation; they are frightened of not being able to protect them or provide for them.

¹⁴¹ Interview held 20 Aug 2014 by the first FFM team.

Dr. Kamal Qdeih, of Khuza'a in Khan Younis,¹⁴² echoed this sense of helplessness in parents, saying:

I feel the attacks have caused a loss of trust from my children. During the attacks my 8-year-old son kept saying 'Don't throw me away on the street, even if they kill me'. I feel this loss of trust is because I lied to my children, telling them that they were safe, when they felt that they were not, and were terrified. I feel that the children resent the fact that I, their father, cannot protect them.

The second FFM team also visited a private pre-school, housing 150 children and 20 teachers. The director of the school¹⁴³ said that all of the children had been exposed to the bombs and the panic in one way or another. Several children were directly affected, being displaced in UNRWA schools for days or weeks. Some have lost their family members and/or homes in the conflict. Three teachers from the school also lost their houses, and many of them have had family members killed or injured. The staff have asked the director to plan psycho-social rehabilitation activities during the year to overcome trauma.

Some members of the first FFM team, walking between the various buildings in the hospital complex, noted rather aggressive behaviour—physical tapping, pulling and verbal heckling—from some of the internally displaced children living on the grounds of Shifa Hospital, several who looked to be as young as 6. The children appeared to be on 'high alert' and it was difficult for them to engage with the team, who were obviously not Palestinian. One of the team members managed to interact with several children, who after some time smiled for a photograph on the grounds of their 'tent.' Young boys and teenagers observed by a member of the second FFM team in Shuja'yia¹⁴⁴ were initially accommodating to requests for a photograph and posed in front of an extensive terrain of demolished buildings, but then switched to aggressive requests for payment.

Another interviewee in Tel Al Hawa in Gaza City,¹⁴⁵ spoke of the problems faced by people who were already mentally and physically challenged before the attacks. The interviewee, a mechanic who is married with five adult children, 2 of whom are healthy and 3 of whom are mentally and physically challenged (aged 28, 22 and 17 years old), used to seek treatment for their condition in Ichilov, a hospital in Tel Aviv, Israel, before the border was closed. He also took them to Egypt and Jordan for treatment, but the closure has made access to qualified care very difficult for them in recent years. During this war they could hear severe shelling in their area day and night. Ten buildings were destroyed in their neighbourhood, and Al Basha tower toppled in front of their house. These disabled children are now suffering from PTSD. During and after the attacks they became very irritable and aggressive; and, their mother is having difficulties dealing with their behaviour. They only manage to sleep by taking medication, which was never a problem before. Providing these medications

¹⁴² Interviewed in Khuza'a on 10 Sep 2014 by the second FFM team.

¹⁴³ Wegdan Diab, owner of Mira KG, a private pre-school in Gaza City, interviewed on 8 Sep 2014 by the second FFM team.

¹⁴⁴ Visit by JL, 14 Sep 2014

¹⁴⁵ Ibrahim Zakkur, interviewed 8 Sep 2014 by the second FFM team.

is difficult for him; he has to use 'connections' to get them. The interviewee seeks professional mental healthcare for them but there are no remaining services in Gaza to deal with disabilities of this sort. The only centre he has found so far is Palestine Mustakbal, but they have no programmes for adults.

Dr. Yasser Abu Jame'i, the Director of the Gaza Community Mental Health Programme (GCMHP), who lost 25 members of his family in the attack,¹⁴⁶ was also interviewed by the second FFM team and explained that PTSD following these events is extremely common but is moreover compounded by the fact that this attack is obviously not a single exceptional event from which to recover. The underlying problem is the perpetual nature of the conflict coupled with tremendous uncertainty, so that even if people do survive their injuries, they are continually brutalized in other ways.

The baseline before this attack was never 'normal': the residents of Gaza have experienced 3 wars in the past 6 years. They must face the challenge of on-going rehabilitation of those previously injured while attempting to attend to people with new injuries. More broadly, Gaza has been under various forms of closure¹⁴⁷ and movement restrictions since the early 1990s, with drastic additional sanctions since 2007, which results in a sense of imprisonment and strangulation.

Other issues that impact on the ability of communities to recover psychologically or that impede resilience include widespread social mistrust and challenges to personal safety stemming from the knowledge that there are local 'informants' who provide the Israeli authorities with targets. If identified, the informants are killed or otherwise penalized by the Hamas authorities. The continuous and intrusive surveillance by Israeli drones, which also have missile capacity, adds further to the perception of threat and on-going suspicion.

Despite the existence of civil society groups like the Gaza Community Mental Health Programme, the residents of Gaza have poor overall access to mental health care; furthermore, seeking this type of treatment elicits societal taboos even in 'peace' time.

Finally, children and the youth under 18 years of age, who are especially vulnerable, comprise 70% of the population of the Gaza Strip. This war and its aftermath will have a lasting impact on future generations and communities. Dr. Abu Jame'i, Director of GCMHP, summarised this point, saying:

The children of the first intifada were the fighters of the second and are the leaders today. The consequences of that do not leave much hope for any peaceful solution of anything. Children grow to believe that power comes from strong parents carrying a gun.

¹⁴⁶ Interviewed 11 Sep 2014 by the second FFM team. Regarding the attack on his family see Amnesty International, Families Under the Rubble, 5 Nov 2014, pp17-19, at <http://www.amnesty.org/en/library/asset/MDE15/032/2014/en/613926df-68c4-47bb-b587-00975f014e4b/mde150322014en.pdf>, accessed 23 Nov 2014.

¹⁴⁷ The term 'closure' is used here as opposed to 'blockade' for various reasons. For detail see e.g Gisha Position Paper, 2008, available at <http://www.gisha.org/UserFiles/File/publications/GazaClosureDefinedEng.pdf>, accessed 8 Dec 2014.

6.3.1 Mental health impact of the attacks in the south of Israel

On 12 September 2014 a member of the second FFM team held an interview with a family doctor in the south of Israel,¹⁴⁸ who cares for people from the local kibbutzim as well as Palestinians and Bedouins living nearby, at distances of 3-40 km from the Gaza Strip.

He is the only doctor for 100 square kilometres in a very rural practice. The population consists of agricultural workers on small farms or working subsistence, poor people without much financial or psychosocial support. The doctor reported an increase in significant physical and mental health issues in almost direct correlation with the intensity of rocket warnings and attacks. His assessment is that people are becoming traumatized to a greater degree.

The population lives with the constant worry of 'Where could I be protected?'; they run from one area to another trying to stay in designated protected areas. Due to the risks, they are reluctant to leave their homes or protected areas throughout the day. Children are advised to use the toilet before leaving home and not use the facilities when at school or kindergarten because the toilets are outside the main protected buildings. This physician sees changes in children's behaviours as they feel no sense of safety at home. While there is no lack of basic necessities, there is definitely a constant fear and sense of randomness about life. Because of the continuous shelling of these communities - their yards, gardens, homes - even 'very strong' people become fearful and traumatized. Children are having difficulty sleeping and experiencing nightmares and bedwetting. They also exhibit anxiety, Attention Deficit Disorder (ADD) and compulsive behaviours (e.g., one child now closes and opens his bedroom door three times every night, believing that this ritual will stave off bombardment). This doctor remarks that he has never before prescribed so much anti-anxiety medication for parents and children as he did in the 50-60 days of the war and even now, weeks after the ceasefire.

As the violence of the conflict intensified, there had been increased [temporary] displacement within Israel as people fled the border areas. According to the doctor interviewed, there were at the time about 300,000 temporarily internally displaced people, who had left to go up north to live with family or friends. The children's summer-camps and schools opened up and families went there to stay. Most people in his community had been away for the last month or more due to fear and uncertainty about the ongoing crisis.

The doctor reported that communities that are close to the border have about 60 seconds from the sounding of the alarm to find safety; those living almost on the border, where the danger is mainly from mortar shells, have only 15 seconds. The siren and Iron Dome system is good for high-flying rockets but mortars shot from 800 meters within Gaza take a mere 4 seconds to hit targets close to the border. 'Every day', he said, 'you hear mortars falling all over', becoming a daily occurrence since early 2014 onwards. One hundred twenty (120) mm. mortars shot from a 3-4 km distance will give some warning by their sound.

¹⁴⁸ Telephone interview held on 11 Sep 2014 by JL with Dr. A, who wished to remain anonymous.

6.4 Rehabilitation facilities in Gaza

6.4.1 Assessment of needs

As stated above, the FFM teams were informed that of the more than 11,000 people injured, about 3,000 had been admitted to a hospital for complex surgical procedures, and just over 500 had been referred to receive medical care outside Gaza.¹⁴⁹ It is unclear, however, how many of those injured during this war will require rehabilitation and/or suffer long term disabilities necessitating therapy and accommodations. The FFM's assessments indicate that many of the hospitalized patients experienced amputations and compound limb fractures, which will require prostheses and intense rehabilitation to recover function. Many patients are likely to suffer permanent disabilities.

The FFM teams heard conflicting estimates in this regard, ranging from 75 to 1,000 people, and believe that authoritative information regarding numbers of individuals or distribution according to age does not exist, primarily because of the poor documentation and limited access to injured people in the community at this stage.

Efforts are being made by hospitals to retrospectively assess the number of amputations and other surgeries done during the war; but at present, no statistics about surgical activities, including amputations, during the full duration of the war are available. The absence of such data makes it difficult to undertake adequate planning.

Irrespective of the exact figures, it is clear that rehabilitation, both physical and psychological, will be crucial as individuals and communities struggle to recover their lives and livelihoods; and, a marked increase in the need for specialized rehabilitation services is anticipated. It is important to note, as mentioned previously,¹⁵⁰ that the only public rehabilitation hospital in Gaza, Al Wafa, was completely destroyed early on in the war. In addition, a 12 July 2014 airstrike damaged the Mabarrat Filistine Association, a residential rehabilitation facility for the disabled in Beit Lahiya in northern Gaza. Two disabled women were killed in the attack and four people were injured.¹⁵¹ the current status of this facility is unknown.

An additional related issue, described by one doctor in a referral hospital, is that hospitals are seeing the long-term effects of hospitalization in patients, including 'narcotics addiction' due to prolonged opiate treatment for pain.¹⁵²

¹⁴⁹ See above, Chapters 1 and 4.

¹⁵⁰ See No 3.2 above.

¹⁵¹ Interview with Mustafa Abed of the Palestinian Medical Relief Society (PMRS) on 11 Nov 2014 by AV. See also UNRWA situation report from 13 Jul 2014 at <http://www.unrwa.org/newsroom/emergency-reports/gaza-situation-report-5>, accessed 23 Nov 2014.

¹⁵² Dr. Maher Al Deeb, Director of St Joseph Hospital East Jerusalem, interviewed on 22 Aug 2014 by the first FFM team.

6.4.2 Rehabilitation resources in Gaza

Two members of the FFM¹⁵³ were asked to collect additional information regarding rehabilitation resources in Gaza. The outline below is based on the information they gathered from different sources¹⁵⁴

Physiotherapy rehabilitation facilities in Gaza include:

- 2 Primary Healthcare Centers (PHCs) with rehabilitation / physiotherapy facilities
- 5 major MoH hospitals with rehabilitation / physiotherapy services (hospitalization and / or outpatient services)
- 3 paediatric hospitals with physiotherapy services
- 3 private hospitals in Gaza City
- UNRWA-run general healthcare services for refugee populations in Gaza City, Khan Younis (southern Gaza), Jabalia (northern Gaza), Bureij and Nusseirat (both in the middle area)
- NGOs: the Palestinian Medical Relief Society (PMRS)-run rehabilitation centers in the north and in Gaza City; MSF-sponsored post-op clinic in Gaza City with physiotherapy and dressing sections (specializing in burns and hand physiotherapy, including orthopaedic services) which has capacity to increase services to other locations

International reconstruction plans for Gaza include rebuilding the destroyed Al Wafa Hospital (Gaza's rehabilitation hospital - see 3.2 above) in Shuja'iya, pending the receipt of funds for this purpose.¹⁵⁵

Despite the availability of these services, access to them is not universal: some of them, for example, are private and depend on fee-for-service payment or adequate health insurance. In an interview with Mustafa 'Abed, rehabilitation coordinator for the Palestinian Medical Relief Society (PMRS) in Gaza City,¹⁵⁶ he stated that a key challenge for organizations providing services for the disabled is the lack of unity between the Hamas-led authorities in Gaza and the Fatah-led authorities in the West Bank, and thus the almost complete 'absence' of the Social Affairs Ministry coordination of services for disabled people. According to him, before 2007, the MoH coordinated the sector and provided clear guidelines and policies. The situation changed dramatically after Hamas took power in 2007, with many international donors unable or unwilling to collaborate with Hamas, and instead electing to deal directly with local NGOs. According to him, the outcome of this disjointed situation is a complete lack of coordination, the duplication of some services and neglect of others, together with a dearth of monitoring and evaluation - with inadequate data collection and analysis critical for planning.

¹⁵³ B and AV.

¹⁵⁴ Additional preliminary information is available in the Health Cluster Report at pp 25-26

¹⁵⁵ See http://foodsecuritycluster.net/sites/default/files/National%20Early%20Recovery%20and%20Reconstruction%20Plan%20for%20Gaza_Interventions%20A%20%20%20.pdf accessed 24 Nov 2014

¹⁵⁶ Interviewed on 11 Nov 2014 by AV.

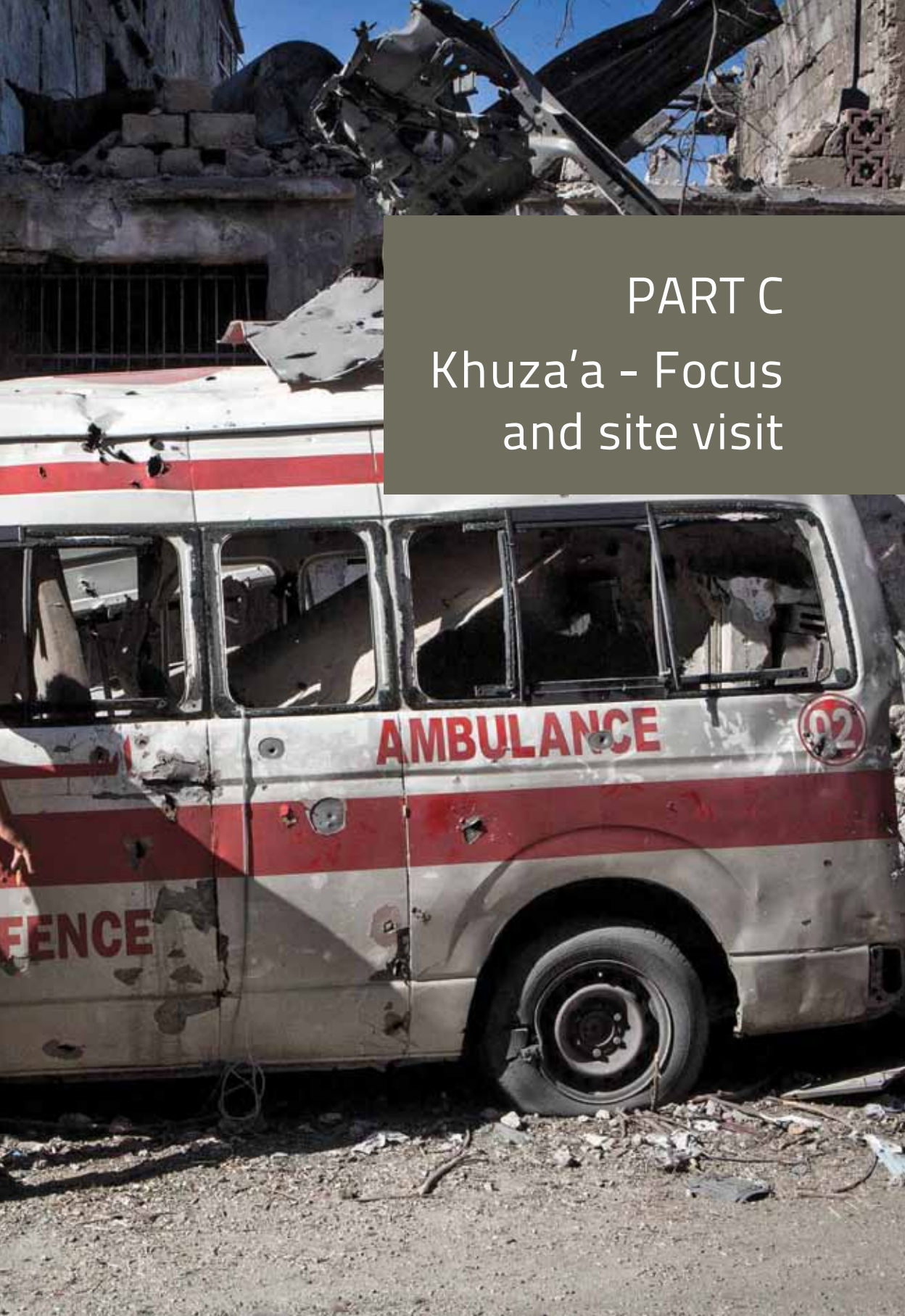
According to PMRS, the main provider of prosthetic limbs in Gaza is the Artificial Limb and Polio Center (ALPC) in Gaza City. It is supported by the ICRC, from which it receives funding. Generally speaking, all patients needing artificial limbs have access to this service, since expenses are covered by UNRWA, if the patient is defined as a Palestine refugee, or by MoH/donors/NGOs, if not. However, there are problems with financial access to other essential accessories such as wheelchairs, glasses and hearing aids.

The second FFM team visited a private church that serves as a full-time residential facility for permanently disabled and impoverished individuals, run by the Roman Catholic Sisters of Charity in Shuja'iya, Gaza City.¹⁵⁷ It serves babies from 10 days old to children of both sexes aged 10-12 years, and disabled women whose families do not provide for them. There are no existing facilities for similarly disabled men. According to the Sister in Charge, there are no other residential facilities for disabled children in Gaza. She stated that there are facilities for physiotherapy, but no full-time residential facilities. Families bring their disabled children to live here. They are able to visit their children on Fridays (visitors' day). She believes that the relatively large number of children with congenital and genetic anomalies is due to consanguinity. During the war, there were 28 children living at the facility. Fewer children were housed there after the war. Displaced people stayed in the church for a short time during the war. They then left for UNRWA schools which housed the displaced. She heard bombing all around the area of the church during the war. When told to evacuate, there were 4 sisters and 24 severely disabled children in the facility. Despite the warnings, they did not evacuate, as they could not physically move the children and women in their facility. Instead, they brought mattresses down to the bottom level of the facility and prayed that the Israeli military would see fit to not bomb a church.

In addition to the facilities within Gaza, patients (in theory) can be referred to more advanced rehabilitation centres in the West Bank, including the Bethlehem Arab Society for Rehabilitation in Beit Jalla, the Abu Raya Rehabilitation Centre in Ramallah and others. Others have been referred to Turkey or Germany for rehabilitation.¹⁵⁸ However, such referrals are dependent on securing the necessary paperwork as well as obtaining a financial commitment from the Fatah-led Palestinian Ministry of Health in Ramallah, West Bank.

¹⁵⁷ Interviewed on 12 Sep 2014 by the second FFM team.

¹⁵⁸ For more information regarding referrals see Chapter 5.



PART C
Khuza'a - Focus
and site visit



PART C

KHUZA'A - FOCUS AND SITE VISIT

Khuza'a is a town of 13,000 inhabitants in the south-east of Gaza, in the Khan Younis governorate and is about 1.5km from the border with Israel. This town first suffered bombardments and then a ground incursion by Israeli army troops between 21 and 25 July 2014. An unknown number of people were killed and injured in the course of these events.

The team gathered evidence regarding events at Khuza'a from the following sources:

- **A site visit held in Khuza'a by the second FFM team, on 10 September 2014,** organized and accompanied by the Palestinian Center for Human Rights in Gaza (PCHR).¹ The team received an overview of events from PCHR's lawyer, Shareef Abu Nassar, and then interviewed
 - **Dr. Kamal Qdeih Abu Rijala (hereafter referred to as Dr. Qdeih),** a doctor whose private primary healthcare clinic was pivotal to the events described;² and
 - **Ramadan Muhammad Tawfik Qdeih,** whose father's home was occupied by Israeli army forces in the course of these events.

The team visited the sites described with the witnesses and examined photographic and medical evidence, including x-rays, connected to the testimonies provided. They also encountered and listened to the stories of several other adults and children in the town who had experienced the events described below.


- **A second site visit to Khuza'a by FFM team member Alicia Vacas on 12 November 2014,** in which additional testimonies were recorded and photographs taken, among others the testimony of Sami Khaled Hussein Abu Rijala, who was injured

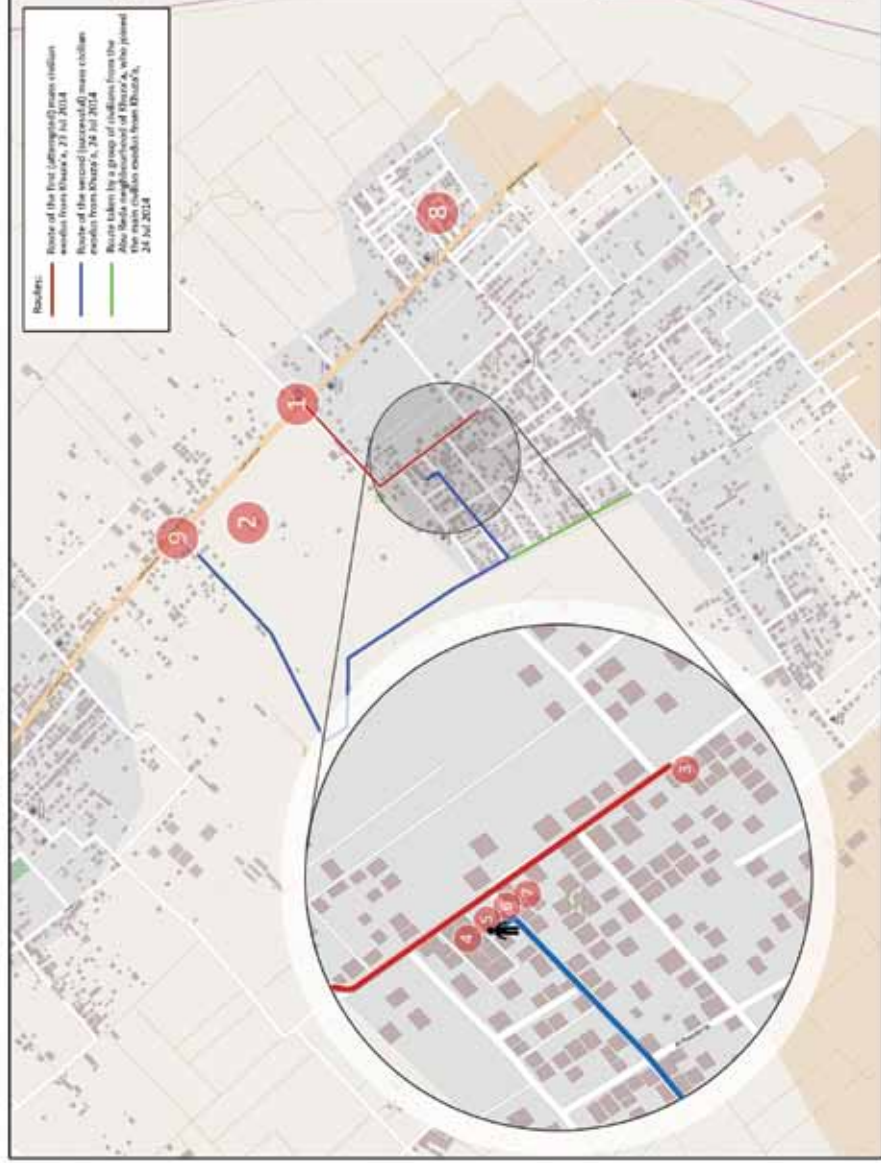
¹ Present at the site visit: KK, HPH, AV (translating) and two attorneys from PCHR.

² According to Dr. Qdeih, he was the only medical doctor in the area at this time. There were no registered nurses. The lab technicians, nurses, and other medics had left the area on the order to evacuate.

Khuza'a

Routes:
 Route of the first (attempted) mass civilian
 evictions from Khuza'a, 23 Jul 2014
 Route of the second (successful) mass civilian
 evictions from Khuza'a, 24 Jul 2014
 Route taken by a group of civilians from the
 Abu Bada neighbourhood of Khuza'a, who joined
 the coalition forces, 24 Jul 2014

- 1 Khuza'a main entrance and site of the attack on the first attempted eviction, 23 Jul 2014
 - 2 Israeli army occupied houses/local headquarters
 - 3 Samia Abu Odeh's brother's home
 - 4 Dr Odeh's Clinic
 - 5 Dr Odeh's uncle's home and basement
 - 6 Ahs. Ramadan Twifireq Odeh's home
 - 7 Muhammad Twifireq Odeh's home
 - 8 Hany Al Hajjar's home
 - 9 Evacuation zone
-  Point at which the boy Basir Odeh was seen entering for evacuation



during the events. She also met Iyad Qdeih (see 'Testimony of PHR-Israel staff' below)

- **Testimony of Samia Abu Daka**, who was injured during the events³ and interviewed by the team at St Joseph Hospital in East Jerusalem on 1 August 2014. She was interviewed a second time on 12 November 2014, in her home at Abasan Al Kabir, Khan Younis.
- **Testimony from a Palestine Red Crescent Society (PRCS) coordinator [name redacted and retained by PHR-Israel-Ed.]**⁴, given to the first FFM team in Gaza City on 19 August 2014.
- **Testimony of PHR-Israel staff**, who received and handled a telephone request for help and evacuation from Khuza'a resident Iyad Qdeih on 23-24 July 2014. Alicia Vacas also met him on 12 November 2014.

The account below and map on the left are a synthesis of these testimonies and evidence.

The general impression generated from all of these sources indicates the possible commission of multiple violations of human rights and international humanitarian law, in matters regarding the protection of civilians and medical teams and evacuation of the injured and the dead, and specific cases of ill-treatment, including the use of human shields, which may contravene the UN Convention Against Torture.

Other organisations and journalists have investigated these events, including the Palestinian Center for Human Rights (PCHR), Al Mezan Center for Human Rights in Gaza, Human Rights Watch,⁵ and various media outlets. This account does not seek to outline the entirety of events but to provide reliable testimony regarding particular events during this period.

1. Sweeping threats and mass flight, 17-18 July 2014

On **17 July 2014** the Israeli army began a ground incursion into Gaza. On the same date the army issued mass evacuation warnings via leaflets dropped from aircraft, media announcements and SMS texts to large parts of the Gaza Strip, warning them of the incursion and ordering them to leave their neighbourhoods for their own safety. One of these neighbourhoods was Khuza'a, where residents were advised to move westward toward the town of Khan Younis.⁶

Many residents left Khuza'a as a result of the warnings, but others could not or chose not to. Some had no relatives or friends in the recommended neighbourhoods, and they had heard of the poor living conditions in the already overcrowded UNRWA schools/shelters in Khan Younis. Many felt they would be safe as they had no

³ Full interview and photograph of injury at Appendix 1, interview sortcode EJJ15.

⁴ Name retained at PHR-Israel's office.

⁵ Human Rights Watch were not able to access Gaza directly due to refusal of Israeli and Egyptian authorities to give the necessary permission. They interviewed witnesses via local fieldworkers. Their 4 Aug 2014 account of events is available at <http://www.hrw.org/news/2014/08/04/gaza-israeli-soldiers-shoot-and-kill-fleeing-civilians>.

⁶ For the wording and locations of these generalized warnings see the website of the Israeli army, IDF, dated 17 July 2014, in which Khuza'a is described as 'Hirbat alhazah': <http://www.idfblog.com/blog/2014/07/17/idf-drops-warning-leaflets-gaza/>



Destruction in Khuza'a.
Photo by AV, 10 Sep 2014



Photo of the first attempted exodus from
Khuza'a, on cellphone of Dr. Kamal Qdeih.
Photo dated 23 Jul 2014

connections with armed groups (termed by Gaza residents as 'the resistance'). Therefore, they believed they would not be targeted as they were civilians. Others, like Samia Abu Daka, whose home is in the nearby town of Abasan Al Kabir, came to Khuza'a from other threatened areas hoping that it would be safer. Of those who did leave for areas further west in the Khan Younis governorate, some returned a few days later, around 20 July 2014, thinking the area was now safe.

On 21 July 2014 Israeli forces bombed the access routes from Khuza'a to Khan Younis, causing craters and obstacles that would not allow passage of vehicles on the roads. The access of the residents of Khuza'a to the outside world was therefore severely restricted for several days. The description that follows is of what occurred there during that time.

2. Sheltering with friends and family, 20-23 July 2014

Heavy shelling began in Khuza'a. Tanks and ground forces arrived in the town and Israeli soldiers occupied several houses, using them as military posts. Residents of the town reported the destruction of several houses by the Israeli army on the night of 20 July 2014 and during the day of 21 July 2014. Shelling and shooting were heard in different parts of the town on the morning of 21 July 2014.

Many residents sheltered in large groups in homes that had not been occupied by the Israeli army, too afraid to leave:

Samia Abu Daka spent this period in her brother's home (see point 3 on the map). With her were her elderly parents, her brother and sister-in-law with their six young children and her own son.

Ramadan Qdeih and his father, Muhammad Qdeih, spent the period from 21 to 25 July 2014 gathered with sixty other people in the basement of Muhammad Qdeih's home (see point 7 on the map).

Many elderly people and people with chronic illnesses (diabetes mellitus, hypertension, renal failure) took refuge **in the clinic of Dr. Kamal Qdeih** (see point 4 on the map), a private doctor who remained in the town when other governmental health workers had fled.

On the morning of 22 July 2014 the area came under heavy shelling and the doctor left his home and moved to his clinic, which is adjacent to his home. He felt it would be safer as it was a health clinic with protected status and due the presence of a large number (about 200) of patients and other civilians that had gathered there.

3. Failed coordination of evacuation and attack on a mass civilian exodus, 22–23 July 2014

On 22 July 2014 Dr. Qdeih contacted PRCS, the International Committee of the Red Cross (ICRC) and the Gaza Ministry of Health to ask them to coordinate their safe evacuation from the town. However, according to him, ICRC's attempts to coordinate evacuation failed. The Israeli army refused to assist with any arrangements and he was told by the ICRC that the area was now a closed, active military zone and they could not help.⁷

On 23 July 2014 at about 05:00 the bombing became more intense. The ICRC stated that they could assist with evacuation in about two hours. After the two hours had passed he contacted the ICRC again. They stated that they were about one kilometer from Khuza'a (Abaha area) but that the Israeli army was refusing to allow them to move any closer.

That morning, many of the remaining people in the town made a collective decision that it would be safest to gather in a common area and leave the town as a large group, walking out together, holding white flags to signify that they were civilians. People contacted each other by phone and young men were sent to the homes where people were sheltering, to inform them of this decision.

According to **Samia Abu Daka**, who participated in the mass march, 500 people took part. Other testimonies put the number as high as 3000.

They left the area of the clinic at 07:30, holding white bed-sheets, clothes tied to sticks, or any other white material including white plastic bags, and walked up the main road, which divides the town and leads westward towards the town of Khan Younis, calling 'peaceful, peaceful.' (The red line on the map marks their route.)

The group neared some tanks and soldiers (see point 1 on the map). According to Dr. Kamal Qdeih, who was in the front line of the group with his wife, grandfather and

⁷ On the matter of failed evacuation see also Para 11 below, and more broadly under Part B, 3.1 'Attacks on emergency teams' above.

children, he heard an announcement by megaphone saying: "You must return, you do not have permission to leave this area".

Soldiers and snipers were stationed on the rooftops of and inside houses along the streets, and the group came under gunfire. Dr. Qdeih says he saw Israeli soldiers with weapons shooting at the group.

According to Dr. Qdeih, about 31 people were injured by bullets and/or shrapnel. To support his testimony, he showed the team photos and X-rays of some of the injured.⁸

Samia Abu Daka sustained abdominal injuries she believes were from gunfire, and bled heavily.⁹ She testified that a tank turned its gun toward the group, but did not fire. Her son, **Kamal Abu Daka**, was mildly injured; according to Samia, three bullets grazed his shoulder and arm. The team observed a healing scar on his shoulder and arm on 12 November 2014.

Sami Khaled Hussein Abu Rijala, 21, suffered a shoulder injury during the attack. He said he was shot from behind. He was treated in Egypt and is now waiting for referral to Turkey to repair his shoulder joint. The team observed a scar on his right upper arm and severe limitation of the extension of his right arm.

A relative of Dr. Qdeih, a disabled, wheelchair-bound, 16-year-old girl with a seizure disorder, was left alone when the shooting started. Her brother was pushing the wheelchair in the large group but when the shooting started he ran away and left her. Later that day Dr. Qdeih tried to get ICRC to evacuate her. However, she died and her charred body was found by her family on 1 August 2014 in the street.

When the soldiers opened fire on the crowd there were moments of panic and chaos, causing them to turn back.¹⁰

4. Treatment and refuge in the clinic, 23 July 2014

Many of the returning group decided to take shelter in Dr. Qdeih's clinic (point 4 on the map). There was continuous shooting towards them as they approached the clinic. According to Dr. Qdeih, soldiers were 'all over the place'. He explained that they

⁸ X-rays shown to the team included shrapnel injuries but no clear evidence of gunshot injuries:

Shrapnel in the hip (Hussein Abu Rijala)

Skull/scalp with shrapnel in the neck

Shrapnel in the neck of the right femur

Mohammed Hussein Abu Rijala-shrapnel in the right elbow

Lu'ai Ayman Abu Rijala-shrapnel in left shoulder and chest right radius fracture, shrapnel in scalp and right hip. He was transported to and treated at the European Hospital in Khan Younis. Cannot move his hand secondary to pain. He was injured on the stairs of the basement.

⁹ Samia was interviewed by the FFM team in St Joseph Hospital in East Jerusalem, where she had been referred after initial treatment at Naser Hospital in Gaza. According to the Hospital Director of St Joseph, she was injured by foreign projectiles, but it was not possible to ascertain whether these were bullets or shrapnel from other munitions as they were not extracted from her abdominal wound. A CT also did not enable identification, according to hospital staff.

¹⁰ According to Ramadan Qdeih, when informed of the decision to leave Khuza'a en masse, his family left his father's basement but were forced back to the house by shelling. They remained in the basement throughout the events described below. The events in his father's home are recounted separately, at Para 10 below.

were so close to the civilian population that Dr. Qdeih's grandfather mistook them for [Palestinian] fighters, when he saw the fully-equipped soldiers using gas masks. The grandfather went up to one of them and, patting him on his shoulder, said: "Ya'atika al 'afya" (may God strengthen you). The relatives around him were terrified at his boldness and pulled him away. The grandfather of Dr. Qdeih was present at the interview and confirmed this account to the second FFM team.

Dr. Qdeih tried to get the 31 injured into his overcrowded clinic. He triaged patients according to the severity of their injuries (severe bleeding; neurological response). Shock and hysteria were a major problem. The majority of the injuries were shrapnel and bullet injuries of the upper body (chest, neck, abdomen, back and hands). He had some local anaesthetics but worked without it once it had run out. Similarly, he had some suture, but used normal sewing thread to close wounds once it had run out.

Samia Abu Daka turned back with most of the group after her injury, holding her child with one arm and her abdomen with the other. She couldn't reach her family's house, so was taken to her cousin's (Dr. Qdeih's) clinic. She described the clinic as small and crowded with 60-70 people, all lying on the floor in the inner yard and at the entrance. Due to the overcrowding, the doctor could only clean and dress her wounds. She was accommodated on the floor of the inner yard on a mattress.

5. Attack on the clinic, 23 July 2014, 17:00

The clinic, a private primary healthcare centre, was clearly marked as such with two signs outside. Nonetheless it came under attack.

According to both Dr. Qdeih and Samia Abu Daka, at about 17:00 Samia Abu Daka asked Dr. Qdeih to move her from where she was sitting. Just after she was moved, a missile fell and struck the spot where she had been sitting. A second missile struck at the same time, hitting the water tank, causing damage to it and to the wall and injuring several people including the doctor himself, with shrapnel. Dr. Qdeih was obliged to remove a piece of shrapnel from his left knee without any anaesthetics. The doctor's brother, Ahmad Qdeih, who was at the water tank at the time,¹¹ was hit by this second missile and died of his injuries about 10 minutes later.

Dr. Qdeih's cousin, Rami Qdeih, suffered a shoulder injury. He had been lying on the single bed in the clinic's treatment room when the television in the clinic room exploded. Rami ran out of the house after this injury and was shot. His family later found him dead, on their way out of Khuza'a the next day (see below at Para.8).

Later, **Dr. Qdeih** heard extensive explosions close to his house. There were 2 missiles/ bombs that sounded as if they were beside his house. He believes that they were fired from an F16 as an attack on his house. Approximately 1 hour after the initial attack on the clinic, a missile hit Dr Qdeih's brother's house about 45 meters from the clinic. Twenty to twenty-five (20-25) people were reported to have been injured in this strike.

¹¹ He was fetching water for a pregnant woman who had been injured by shrapnel at an earlier stage, causing injuries of her liver and kidney.



Dr. Kamal Qdeih, interviewed by the second FFM team in his clinic, Khuza'a. Photo by AV, 10 Sep 2014



Sign on front of Dr. Qdeih's clinic, Khuza'a. Photo by AV, 12 Nov 2014

About 1,500 people left the area to escape these missiles. They left behind the injured, the elderly and any who could not flee the house, and escaped the clinic area.

They later discovered that the Israeli army had occupied and taken over the clinic and Dr. Qdeih's adjacent house. Soldiers' clothing items were found inside these houses. Significant damage was caused by the Israeli soldiers in the whole area.

6. Refuge in the basement, 23-24 July 2014

After the clinic came under attack, about 200 of those who had been inside it took shelter in the basement of a neighbouring house, which belonged to Dr. Qdeih's uncle (point 5 on the map). The basement, which measured about 40 square meters, was very crowded.

Dr. Qdeih said of the flight to the basement:

People did things they never thought they would do out of fear: jumping through the window, running, jumping fences - but also leaving behind their dear ones or stepping over the injured, in panic and despair. We stayed for one day in the basement with 200 others. There were about 80 children.

Dr. Qdeih, Samia Abu Daka, her son Kamal and Sami Abu Rijala were among the group who fled to the basement. Although the injured were in need of medical assistance, evacuation was impossible due to the heavy shelling of the area. According to the staff of PHR-Israel, they were contacted by Dr. Kamal Qdeih's brother, Iyad Qdeih, on 23 July 2014 for assistance in coordinating evacuation of civilians trapped in several houses in Khuza'a, including those trapped in this basement. Between 19:00 on 23 July 2014 and 09:00 on 24 July 2014 PHR-Israel attempted to coordinate safe



Damage to inner yard of clinic, where Samia Abu Dakka was lying, Khuzada. Photo by HPH, 10 Sep 2014



Samia Abu Daka. Photo by AV, 12 Nov 2014

evacuation by speaking to the Israeli military authorities, the PRCS and ICRC, with no success. An ambulance reportedly arrived in the area around midnight but was prevented by Israeli forces from approaching.

The team met with some of the children of the town who had experienced the events described, including sheltering in the clinic and basement. They took the team around the sites, told them of the violence they had witnessed and described symptoms suggestive of PTSD, including nightmares, flashbacks and night bedwetting.

7. Attack on the basement, 24 July 2014

According to Dr Qdeih on 24 July 2014 at about 05:00 he found a teargas canister at the entrance to the stairs of the basement. All the people in the basement felt as if they couldn't breathe due to the gas. They were coughing, sneezing and crying 'hot tears'. They could not leave due to the severe bombing in the area but they also felt they could not stay as they had significant difficulty breathing. Some people were going in and out of the basement to get air. Others stayed in this basement for at least 2 hours. Later that morning, at about 10:30, a missile, believed by Dr. Qdeih to be launched from a drone, blew open the basement gate/door, injuring several adults and children who had been sitting on the stairs.¹² Dr. Qdeih called everyone to leave the basement. Some of the young people in the group broke through a brick wall that separated the back yard of this house from the neighbouring house. They

¹² This is a more accurate description of the event than that reported by Samia Abu Daka, who experienced the attack as destruction of the house. The doctor was in a better position to ascertain the extent of the damage, which was not destruction of the entire house but only damage to the entrance to the basement. Cf Samia's interview at interview sortcode EJJ15.

were then able to make their way through the rubble and through the neighbour's back yard until they reached Muhammad Tawfiq Qdeih's house on a parallel street (point 7 on the map).

8. Exodus from Khuza'a, 24 July 2014

After being forced out of the basement, this group made a second attempt to leave the town en masse. This time they were allowed to proceed, via a different route leading from Khuza'a to Abasan Al Kabir (the blue line on the map marks this route). According to Dr. Qdeih, as they came out onto the street they saw the body of his cousin, Rami Qdeih, lying on the ground but could not stop to care for the body¹³. As they reached the end of the street, they saw a large crowd coming towards them from the adjacent neighbourhood of Abu Reda (the green line on the map marks the route of this group). The two groups merged and they continued trying to reach Abasan Al Kabir. According to Dr. Qdeih, 'all of Khuza'a' was covered by a white fog cloud due to the large amounts of teargas deployed in the area. After about one hour of walking, tanks appeared and pointed their guns at them. He said:

We were about 5-10 meters in front of soldiers with our hands raised. My daughter was waving a white shirt and all were crying "We are civilians". There were about 500 soldiers with bulldozers and 10 tanks every 10 meters with guns pointed directly towards us. We were told to sit down where we were. The soldiers made a corridor between the tanks and told us to walk slowly down the corridor. While this large group walked down the corridor, we heard a large explosion. A motorcycle was targeted by a tank, killing those on the motorcycle and 3 others at the back of our group. We were then able to leave the town. Over the final day, we, people from 1 day old to 100 years old, walked about 3 kilometers.

According to Dr. Qdeih, during the march, a pregnant woman with a baby was not able to walk any further, so she gave her child to others to take to safety. Another woman began having contractions while walking the long distance. She delivered her child at the hospital.

According to **Samia Abu Daka**, she required help from her relatives to complete the 3-km walk. She described the fields on both sides of the road as full of holes, with big mountains of dirt and soil behind which many tanks were hidden. She said they took a narrow path between the fields and some chicken farms to avoid the tanks, because they were terrified of a new attack.

The group finally arrived at a place behind a military checkpoint, where ambulances, private cars, minibuses and even tok-toks (*3-wheel motors-Ed.*) were waiting for them (point 9 on the map). According to Samia Abu Daka, they knew about this meeting point because some of the people in the group had been in touch with their families in Abasan by phone and had heard that ambulances were waiting.

¹³ See also Ramadan Qdeih's testimony at Para 10 below, regarding seeing this body at this location.



Samia Abu Daka at place from which second exodus from Khuza'a began on 24 Jul 2014. Photo by AV, 12 Nov 2014



Destroyed water tower and mosque, Khuza'a. Photo by AV, 12 Nov 2014

Some of the group from the basement did not join this mass exodus. Dr. Qdeih's brother, Iyad Qdeih, reported to PHR-Israel staff that he and his family left the basement under cover of the march and moved first to a school for shelter, and then, because the school was full, to a hospital. His group included two children and Iyad Qdeih's wife, who was 8 months pregnant with twins.

9. The death of Bader Qdeih, 6 years old - denial of medical evacuation

Samia Abu Daka, Dr. Kamal Qdeih and Ramadan Qdeih¹⁴ all recounted that as the second mass attempt to leave Khuza'a began on 24 July 2014, on the main road just in front of Muhammad Tawfiq Qdeih's house, they saw a small boy, who approached them crying, while holding his intestines with his hands, pleading 'take me with you, take me with you' (the estimated location is located by a pictogram of a person on the map). Dr. Qdeih described his injuries as 'severe shrapnel injuries to the abdomen exposing his intestines'. Although Samia Abu Daka and Ramadan Qdeih thought he looked about 9 or 10, Dr. Qdeih said that he later discovered this child to be his relative, a boy called Bader Qdeih, aged 6.

Samia said:

I was so weak and terrified myself that we ran for our lives leaving the child behind. This scene now tortures me and I feel guilty. He was like my son - the same age. He could have been my own son, and I left him there to die.

¹⁴ See Ramadan Qdeih's testimony at Para 10 below, regarding seeing the boy at this location.

Dr. Qdeih said:

I was carrying my own child in my arms, and he was terrified. On the way, my son was begging me not to leave him behind even if he died, because the soldiers would take his body or leave him lying on the street, like the many bodies we were leaving behind. I couldn't take care of the little child crying out for help, but I promised him that I would call ICRC and bring an ambulance for him. I actually did this as soon as we managed to reach safety. Now I feel shame and guilt because I left this boy behind.

When the first FFM team interviewed a PRCS coordinator in Gaza City,¹⁵ he showed a video of an evacuation from Khuza'a on 24 July 2014, as an example of the evacuation team being held at a military checkpoint for three hours with no explanation. The footage includes a child holding his abdomen and begging for assistance. The nature of his injury and his age suggest that this was the same child described above. Judging from the location of the footage, Bader was at the checkpoint and was in the process of being evacuated from Khuza'a, but the evacuation was blocked by the army. In the video he asks for water (which the paramedic explained he could not give him due to his injuries) and asks not to be left alone.¹⁶

In the opinion of Dr. Qdeih the Israeli soldiers and officers must have seen the boy, since they were on the streets in the same area, but no one facilitated his evacuation. It is the opinion of the FFM teams that the army must have seen him at least by the time he was being treated by ambulance teams, since they were present on site and blocking the ambulances' access.

According to Dr. Qdeih and the PRCS coordinator interviewed by the FFM team, the boy, Badr Qdeih died of his injuries after arriving at the hospital.

**10. Ramadan Qdeih and his family, 25 July 2014:
Occupation of a civilian home; execution of a civilian;
interrogation and beatings; 'human shields'.**

Ramadan Qdeih was interviewed by the second FFM team during their visit to Khuza'a on 10 September 2014. According to him, he remained with 60 members of his extended family throughout 21-25 July 2014, in the basement of the home of his father, Muhammad Tawfiq Qdeih [*a different basement from the one described in the other testimonies above, see point 7 on the map-Ed*]. On the morning of 23 July 2014, Ramadan Qdeih's family group tried to leave the basement to join the large group in their first attempt to leave Khuza'a but were forced back into the basement by shooting.¹⁷ The night between 23 and 24 July 2014 was 'terrible' because the Israeli forces fired teargas grenades into their basement, and the situation became almost unbearable. People were crying and had respiratory problems and chest pain, but they did not dare leave due to the shelling in the area.

¹⁵ On 19 Aug 2014, in Gaza City.

¹⁶ The footage is available by special request.

¹⁷ Described above at Para 3.

On 24 July 2014 at about 09:00, most of the people in the basement left and joined the second exodus from Khuza'a.¹⁸

Ramadan and his father, 65-year-old Muhammad Qdeih, left the basement and went outside their house to explore the possibility of evacuating. Almost immediately, they saw the body of Rami Qdeih, Dr. Qdeih's cousin, lying on the ground.¹⁹ They also saw the little boy with the severe abdominal injury exposing his intestines, begging for help.²⁰ Ramadan's father was terrified. He decided to go back and die in his house. He said, "If I die here on the street, the Israelis will not give me a proper burial. But if I die in my house, you can find me and bury me". Ramadan and his family wanted to stay with their father, so they returned to the basement. A total of 27 people, all family members, were gathered in the basement at this time.

Israeli soldiers, speaking over megaphones, stated that ambulances were on their way to evacuate the families. However, young men running between the houses as messengers informed the family that this was not true. They saw an ambulance drive by but the driver did not dare stop at the house. The ambulance staff picked up two wounded persons on the street and left immediately. The ambulance driver said that they would come back to rescue women and children, but they did not return. Ramadan phoned the ICRC, but they told him that they were unable to help. The family then felt hopeless. Ramadan's father told him to crawl towards a neighbour's house to connect the neighbour's water supply with the water tank in their basement. He did so, and in that way they were able to supply sufficient water to the basement. Ramadan was not injured during this excursion.

On 25 July 2014 between 1000 and 1030 Israeli soldiers knocked down the door of their garage with a bulldozer, and soldiers entered the house through the side door. The women and children of the family shouted to alert the Israelis that women and children were in the house. Muhammad Qdeih (the father), standing by the basement door at the bottom of the stairs, shouted to the soldiers in Hebrew that they were all civilians and that he was a Spanish citizen. The Israeli soldiers ordered the entire family up the stairs. The family started to climb the basement stairs. Ramadan's father came first, with Ramadan on his right, then the other men of the family and then the women and children.

Ramadan's father opened the front door of the house, thinking that the soldiers were standing at the main entrance to the house - but they were already in the house behind him, having entered through the side door. Ramadan's father was ordered to turn around from the front door, which he did. As he began to climb the few stairs from the front door towards the side door, in the direction of the soldiers, he was shot twice by one Israeli soldier at a distance of about two meters. The projectiles perforated his chest and the glass of the front door. He died immediately in front of his family. Ramadan 'went completely mad', yelling and shouting. Immediately, the soldiers forced him down, tied his hands behind his back and blindfolded him.

¹⁸ Described above at Para 8.

¹⁹ See above, Paras 5 and 8.

²⁰ See above, Para 9.

The soldiers then directed the older men and the women and children to leave the house. They were told to go to the house of Ramadan's uncle (a well-respected lawyer also called Ramadan Qdeih), a short distance away (see point 6 on the map). The younger men, a total of 7, were kept in the house and blindfolded.

Shortly after, the men's blindfolds were removed and the soldiers ordered Ramadan and the other young men to undress to their underwear. The men were beaten and accused of having bombs. They were accused of intending to explode a suicide bomb, killing themselves and the Israeli soldiers. One by one they were interrogated and beaten. The Israeli soldiers demanded to know the location of Hamas headquarters and resistance fighters.

The soldiers then made Ramadan walk in front of them down the stairs to the basement. He was warned that if any person hiding in the basement was found, the soldiers would immediately kill him. Ramadan was terrified, fearing that if anyone had remained in the basement and the soldiers heard or saw any movement, they would be shot. While walking down the stairs he mentally counted the women and children who had left the house, trying to calculate if anyone was missing and might still be hidden in the basement. At the door to the basement, one soldier placed the barrel of his rifle on Ramadan's shoulder and fired into the basement. When Ramadan began to shout in fear, he was struck with the rifle butt and insulted by the Israeli soldiers.

The 7 males were kept in the house. Some of the soldiers went to the uncle's house and brought the women, the children, and the uncle back to Ramadan's house together with the uncle's family. The women, children and older men were ordered to go to the first floor and were kept there.

The young men were taken to the second floor. The Israeli soldiers had removed the glass from the windows facing the street. Two of the young men were then placed in front of the open windows in each room. The Israeli soldiers placed the rifle barrels onto the men's shoulders and fired out the windows. They did not fire continuously, but now and then over approximately one hour. Meanwhile the Israeli soldiers were laughing and joking. The rifle barrels were alternately placed on the left and the right shoulder of Ramadan (probably the same regarding the other men) and Ramadan was ordered to stand completely still. This lasted for about 8 hours, during which time Ramadan received no food or drink. During the shooting, he got a severe headache with pain and mild ringing in his ears (tinnitus), which persisted for several days. At the time of the interview with the second FFM team, he reported no tinnitus.²¹

After a while the women and the children were again ordered to leave the house. The Israeli soldiers also left the house, leaving one soldier behind to guard the men. Ramadan was untied by his uncle. He started to scream and ran around looking for

²¹ This description of the young men being used as human shields in the occupied house has been described by a Geneva-based group called Euro-Mid. A video of their description is available at <http://www.euromid.org/en/article/597/Euro-Mid-Documents-Israel%E2%80%99s-Use-of-Human-Shields-in-Gaza>, accessed 23 Nov 2014



Bullet hole A in front door of Muhammad Qdeih's house, direction inside-to-outside. Photo by HPH, 10 Sep 2014.



Bullet hole B in front door of Muhammad Qdeih's house, direction inside-to-outside. Photo by HPH, 10 Sep 2014.

his father's body. The remaining Israeli soldier then 'fled the house'. It was unclear to Ramadan how many soldiers had been in the house during these incidents, but he had the impression that the house was invaded by a total of about 150 Israeli soldiers.

Ramadan found his father's body in the WC. He did not want to leave his father's body but the other men dragged him out of and away from the house. They were then instructed by the Israeli soldiers on the street which way to leave town.

Note regarding mental health impact of the incident: At interview, **Ramadan Qdeih** said that he often has flashbacks of the incident. He said he feels as though his life is broken. He is very irritable, much less patient than before and has severe difficulties with falling asleep. When he does sleep, he wakes several times during the night. He feels empty and also has the feeling that it would have been better if he had been killed during the attack. During the interview some children upstairs began screaming. After less than a minute, Ramadan suddenly got up from his chair, ran up the stairs and shouted at the children. When he came back, he apologized but explained that he had lost his tolerance towards any noises.

Comment by interviewers: The impression is of a man with clear symptoms of PTSD.

11. Evacuation delay, 24 July 2014

According to a PRCS coordinator in Gaza City, as well as the testimony of Dr. Qdeih, the PRCS carried away several dead and injured from Khuza'a on 24 July 2014.²² They were then kept at a military checkpoint outside Khuza'a for 3 hours without permission to

²² According to the PRCS coordinator, interviewed on 19 Aug 2014 in Gaza, 7 dead and 9 injured, some of them very serious, were evacuated on 24 Jul 2014; according to Dr. Qdeih, 5 dead and 7 injured were evacuated that day.



Muhammad Qdeih's house, Khuz'a. Photos by HPH, 10 Sep 2014. Left: damage to garage and side entrance

move.²³ Numerous tanks were in the area near the ambulances. While there they were not allowed to use their cell phones. Only the head of the ambulance team was allowed to make telephone calls, and only from the 'soldiers' station' (an occupied house) and under the soldiers' supervision. According to the PRCS coordinator, the ambulance team said they felt that they were being used as human shields by the soldiers.

The PRCS coordinator stated that the coordination of ambulance access to Khuz'a following this incident took several days, which he said, was highly unusual even for this war.

12. The Al Najjar home

PCHR took the second FFM team to a house in Khuz'a (point 8 on the map) where, according to local residents, a pile of at least 6 corpses in advanced stages of decomposition were found in the bathroom.²⁴ There they observed organic remains on the floor and walls of the indicated room. In addition, marks of either shrapnel or gunfire were on the walls of this room. According to one person's testimony, a hand grenade was thrown into the room causing these deaths. Others theorized that gunfire or slitting of the victims' throats was the causes of their death. Bullet casings, shrapnel, a grenade pin and knives were shown to the team on site. However, it was not possible to verify the validity of any of this evidence or to connect it to the death as no first-hand accounts were available and the scene had been altered by outsiders. It should be noted that Al Mezan and PCHR are holding investigations into this case.

²³ See also above, Para 9. The exact location is unclear, but it is likely to be near point 9 on the map.

²⁴ An early published description of this case is in a 1 Aug 2014 media report by Jesse Rosenfeld of the Daily Beast, available at <http://www.thedailybeast.com/articles/2014/08/01/who-is-behind-gaza-s-mass-execution.html>, accessed 22 Nov 2014.



middle: House's side and front entrances visible. Right: damage to garage and side entrance

Legal note: The use of civilians as 'human shields'

The Israel Defence Forces Manual on the Laws of War (1998) states that it is prohibited to exploit the presence of prisoners to render military objectives immune from attack.²⁵ Israel, Laws of War in the Battlefield, Manual, Military Advocate General Headquarters, Military School, 1998, pp. 52 and 57. The Israel Defence Forces Manual on the Rules of Warfare (2006) states that, in the rules of war, there is a serious prohibition on the use of civilians as human shields.²⁶ Israeli case law also includes rulings prohibiting the use of civilians as human shields.²⁷

International humanitarian law prohibits the use of civilians as human shields.²⁸ The International Criminal Tribunal for the former Yugoslavia has held that using a civilian as a human shield may constitute cruel and/or inhuman treatment and an outrage upon personal dignity, as prohibited by common Article 3 and the grave breaches regime of the 1949 Geneva Conventions.²⁹

The methods described by Ramadan Qdeih at Para 10 above involved a combination of methods of coercion, during which civilians were forced to act as human shields

²⁵ Cited in the ICRC's online resource Customary IHL, 'Israel: Practice Relating to Rule 97. Human Shields', available at https://www.icrc.org/customary-ihl/eng/docs/v2_cou_il_rule97, accessed 17 Nov 2014.

²⁶ Ibid.

²⁷ In its judgment in HCJ 3799/02 Adalah et al v OC Central Command (Neighbour Procedure) in 2005, Israel's High Court of Justice stated: [I]t is clear that an army ... is not permitted to use local residents as a "human shield".

²⁸ See article 28 of IV Geneva Convention Relative to the Protection of Civilian Persons in Time of War 1949 and Article 51(7) of The First Protocol [1977] Additional Protocol I.

²⁹ Kordic and Cerkez, (Trial Chamber), February 26, 2001, paras. 256, 265; Kvočka et al., (Trial Chamber), November 2, 2001, para. 161; Aleksovski, (Trial Chamber), June 25, 1999, para. 229.

for Israeli armed forces while suffering threats of death, violence, constraints on movement and restriction of basic necessities.

The FFM teams conclude that the severe pain and suffering described above in the testimony of Ramadan Qdeih, and his use as a human shield, engage the international humanitarian law prohibition of human shields, and the prohibition of cruel and/or inhuman treatment, and outrages upon human dignity, as codified in common Article 3 and the grave breaches regime of the 1949 Geneva Conventions.³⁰ The resultant pain and suffering also meets the definitions of torture in the Tokyo Declaration of the World Medical Association.³¹

In addition, regarding suspicions voiced above regarding use of evacuating medical teams as human shields, if confirmed, such practices are likely to be a serious violation of IHL: Under no circumstances may medical units be used in an attempt to shield military objectives from attack.³²

Conclusion

The incidents recorded at Khuza'a are in general indicative of several violations of human rights and international humanitarian law, stemming from actions and decisions by multiple levels of the chain of military command: from heavy bombardments of civilian neighbourhoods, which must have entailed approval from top-level decision-makers, through denial of medical care and attacks on medical evacuation, despite repeated coordination attempts and eye-contact between forces on the ground and the injured persons, to shooting of civilians at short and medium range by individual soldiers using light arms, and finally to abuse and ill-treatment during occupation of residential buildings, including the use of civilians as human shields and practices that could amount to Cruel, Inhuman or Degrading Treatment (CIDT). No less serious was the prevention of prompt access of external investigators to the site. In some senses the events at Khuza'a can be said to epitomise the failings of Israeli policy and practice in the course of this armed conflict in Gaza.

³⁰ See Article 3 GC IV, and Article 147 GCIV.

³¹ WMA Declaration of Tokyo - Guidelines for Physicians Concerning Torture and other Cruel, Inhuman or Degrading Treatment or Punishment in Relation to Detention and Imprisonment Adopted by the 29th World Medical Assembly, Tokyo, Japan, October 1975 and editorially revised by the 170th WMA Council Session, Divonne-les-Bains, France, May 2005 and the 173rd WMA Council Session, Divonne-les-Bains, France, May 2006. The UN Manual on Effective Investigation and Documentation of Torture and Other Cruel, Inhuman or Degrading Treatment or Punishment, published by the Office of the High Commissioner for Human Rights and commonly known as the Istanbul Protocol, lists examples of torture methods in its section, 'G. Review of torture methods', including, inter alia, "(b) Positional torture... prolonged constraint of movement, forced positioning; (n)... restriction of sleep, food, water, toilet facilities, bathing, activities, medical care...; (p) Threats of death, harm to family... mock executions." See section G. Review of torture methods, at p.29. Available at <http://www.ohchr.org/documents/publications/training8rev1en.pdf>, accessed 17 Nov 2014.

³² Additional Protocol I, Art 12(4)

PART D

Conclusions and Recommendations





PART D

CONCLUSIONS AND RECOMMENDATIONS

1. Accountability

As indicated in the introduction to this report, the FFM's aim was to provide a partial contribution based on its expertise in the fields of health, human rights and forensic medicine, to fit into a broader picture of evidence. Therefore, this Report focuses mainly on these aspects of the armed conflict.

- More broadly, the FFM concludes that the incidents recorded in Gaza during this armed conflict are suggestive of several serious violations of human rights and international humanitarian law:
- The attacks were characterised by heavy and unpredictable bombardments of civilian neighbourhoods in a manner that failed to discriminate between legitimate targets and protected populations and caused widespread destruction of homes and civilian property. Such indiscriminate attacks, by aircraft, drones, artillery, tanks and gunships, were not the result of decisions made by individual soldiers or commanders; they must have entailed approval from top-level decision-makers in the Israeli military and/or government.
- The initiators of the attacks, despite giving some prior warnings of these attacks, failed to take the requisite precautions that would effectively enable the safe evacuation of the civilian population, including provision of safe spaces and routes.
- All first-person reports received by the FFM teams emphasized that because of the incessant and unpredictable nature of the attacks, there was no guaranteed safe space in the Gaza Strip, at any time, in any location. When the attacks did occur, the targets included possible escape routes, ambulances attempting to reach the wounded, and individuals attempting to flee. Because of the closure of

all crossings and borders, there were also no escape routes to exit Gaza.

- The FFM encountered numerous cases in which double or multiple consecutive strikes on a single location led to multiple civilian casualties and to injuries and deaths among rescuers.
- In addition, the FFM encountered numerous examples of the denial of coordination of medical evacuation and attacks on medical teams and facilities. It is not clear whether such contravention of medical neutrality was the result of a policy established by senior decision-makers, a general permissive atmosphere leading to the flouting of norms, or the result of individual choices made on the ground during armed clashes.
- In the particular case of Khuza'a, the FFM also received evidence indicating human rights violations by specific troops in the area, including denial of medical care despite eye-contact between the troops and the injured person/s, shooting of civilians at short and medium range by individual soldiers using light arms, and abuse and ill-treatment during occupation of residential buildings, including the use of civilians as human shields and practices that could amount to cruel, inhuman or degrading treatment (CIDT) or even torture.

The FFM contends that each of the above findings requires further investigation by the international human rights community. In other words, the FFM calls for the conduct of all members at all levels of the Israeli government and military – and of all other parties to this armed conflict – to be investigated in a credible and transparent manner, and for those responsible for such violations to be held to account. The fact that the government of Israel prevented swift access of external investigators to the Gaza Strip following the ceasefire of 26 August 2014 adds to the urgency of this recommendation. The FFM also calls upon the UN, the EU, the US and other international actors to take steps to ensure that the governments of Israel and Egypt permit and facilitate the entry of such investigative teams, which must include experts in international human rights law and in conventional and non-conventional weapons. The delays introduced by the government of Israel notwithstanding, it is essential that a wide range of external authorities be given access to the facts of this conflict and be allowed to sift through the evidence that still exists in the Gaza Strip.

In relation to such an investigation, the FFM draws attention to the independence and credibility of local Palestinian civil society groups such as Al Mezan, PCHR, GCMHP and PMRS, and encourages the international community to support and recognize their efforts to collate evidence in Gaza, in order to proceed with legal and/or other remedies as well as to seek justice and/or reparations.

2. Health and its social determinants

In addition, the FFM recommends urgent and rigorous investigation into the impact of this war, as well as the previous armed conflicts, on public health, mental health and the broader social determinants of health in Gaza:

2.1 Impact on public health and the broader social determinants of health

The FFM teams were not able within their timeframes to investigate the impact of the attacks on the primary healthcare system. Nor could the teams ascertain the public health impact of extensive attacks on infrastructure (including water, sewerage and power generation, and public buildings and residential resources) and on the environment (including explosive remnants of war and toxic pollution of land, water, and air). These issues will undoubtedly represent a lasting challenge for the residents of the Gaza Strip in years to come, especially in light of continued Israeli restrictions on entry of reconstruction teams and materials. In this regard, it is recommended that a detailed impact analysis be undertaken by water and sanitation engineers and toxicologists together with public health experts to examine both the extent and nature of the attacks (e.g., whether a legitimate war target can be identified among those structures that were destroyed and/or whether the extensive damage suggests indiscriminate attack). In this examination, it will also be essential to assess the current and anticipated longer-term effect the destruction wrought by this conflict will have on the broader social determinants of health of the population of the Gaza Strip.

In this assessment, the implacable effects of the on-going occupation itself must be taken into account. By continuing to constrict the future economic and human development of the society (for example Gaza's dependence on Israel for electricity and food production and the marked restrictions on mobility and trade), the occupation exerts a dominant and grim impact on the health and human rights of this population.

As stated in the Ottawa Charter for Health Promotion (1986), 'health is...a resource for everyday life, not the objective of living.'¹⁵⁹ The Charter lists 8 'prerequisites for health' which are critical conditions that must exist for health to be possible. These are: peace, shelter, education, food, income, a stable ecosystem, sustainable resources, social justice, and equity. The FFM notes that these basic, or foundational, prerequisites have been so disrupted in Gaza over the past three wars-and even further eroded during these present attacks-that 'health' will remain a precarious notion for some time.

2.2 Psycho-social effects of the war

The physically and psychologically injured and disabled of this war will join survivors of previous wars to swell the population of those suffering grievous personal assaults on their human potential and dreams of the future. They

¹⁵⁹ See the Ottawa Charter for Health Promotion <http://www.who.int/healthpromotion/conferences/previous/ottawa/en/> accessed 5 Dec 2014

See <http://www.ohchr.org/en/NewsEvents/Pages/DisplayNews.aspx?NewsID=14897&LangID=E> accessed 5 Dec 2014

will persist to others as permanent reminders of the attacks on their families, communities and surroundings. While not wishing to devalue in any way the traumatic effects of the war on Israeli civilians, these pale in comparison with the consequences of the massive destruction wreaked on Gaza. The damage caused to the Gazan people's sense of security and trust, as described to the members of this FFM by residents of the Gaza Strip, is likely to erode inter-generational relationships and social solidarity, with deep and long-lasting destabilizing effect on the community - despite its great resilience (expressed frequently to the FFM teams as *sumoud*). The further fact that many of those displaced and otherwise affected in this war were already traumatised (as refugees, wounded, disabled and bereaved) from previous rounds in this decades-long conflict compels the stark recognition of how necessary it is to bring about an immediate and permanent resolution.

The FFM believes that the *prima facie* evidence it has collected and presented in this Report should be used for the purposes of legal determination of violations of international human rights and humanitarian law, whether through local or international justice mechanisms. For this purpose it is willing to assist and provide evidence to any credible investigation established for this purpose.

In the absence of political will to resolve the underlying causes of this conflict, it is likely that the residents of Gaza - and those of Israel and of the other parts of the occupied Palestinian territory - can expect to see future repetitions and escalations of the war of 2014. In such a scenario, the campaign for accountability, of which this fact-finding mission is a part, should be seen as a long-term quest, of historic as well as current importance.

The FFM experts can be contacted via PHR-Israel at ffm@phr.org.il or +972 3 5133100.

Oifa and Momem Alouh, the only daughter and son remaining of Mustafa Alouh, is seen injured following an Israeli airstrike during the last Israeli offensive, in Deir al-Balah city, September 16, 2014. The attack killed 8 members of their family. Mustafa survived as he woke up for prayer and went to the kitchen.



A photograph showing a woman in a black hijab and a man lying in a hospital bed. The woman is sitting on the left, looking towards the camera. The man is lying in the bed on the right, also looking towards the camera. The bed has a patterned pillow and a metal frame. The background is a plain, light-colored wall.

APPENDIX 1

Patient Interviews

INDEX OF INTERVIEWS BY SORTCODE

Interview Sortcode	Page Number	Interview Sortcode	Page Number
EJJ1a/EJJ10	208	EJM13	191
EJJ2	199	EJM14	109
EJJ3/EJJ3a	210	EJM15	158
EJJ3a/EJJ3	210	EJM16/EJM12	177
EJJ4a/EJJ20	156	EJM17	139
EJJ5	186	EJM18	154
EJJ6	212	EJM19	192
EJJ7	223	EJM20	194
EJJ8	187	Erez1	159
EJJ9	214	GS1	136
EJJ10/EJJ1a	208	GS2	142
EJJ11	107	GS3	169
EJJ12	132	J2	116
EJJ13	108	J3	118
EJJ14	144	J4	166
EJJ15	201	J5	167
EJJ16	215	J6	179
EJJ17	120	J7	222
EJJ18	121	J8	181
EJJ19	112	J9	197
EJJ20/EJJ4a	156	J10	110
EJJ21	189	J11	115
EJJ22	199	J12	173
EJJ23	123	MED1	148
EJJ24	145	MED2	152
EJJ25	200	MED3/EJM1	147
EJM1/MED3	147	MED4/WBBJ1	106
EJM2	140	WBBJ1/MED4	106
EJM3	217	WBN1	128
EJM4	171	WBN2	219
EJM5	172	WBN3	155
EJM6	175	WBN4	129
EJM7	124	WBN5	131
EJM8	114	WBN6	161
EJM9	126	WBN7	221
EJM10	127	WBR1a/WBR1b	162
EJM12/EJM16	177	WBR2	195

1.1 Erez area



Image by PHR-Israel, Bethlehem Arab Society for Rehabilitation, Beit Jala, West Bank, 4 Aug 2014

WBBJ1 (MED4)

Patient: Saed Ihsan Qadura Hamouda

Gender: M

Age: 30

Witness: Saed Ihsan Qadura Hamouda

Date of Interview: 04 Aug 2014

Location of Interview: Bethlehem Arab Society for Rehabilitation, Beit Jalla, West Bank

Interviewer/s: Alicia Vacas, PHR-I Staff

Also present: Patient's uncle, Mahmoud Hamouda

Home address: Jabalia, Northern Gaza

Occupation: Ministry of Health paramedic

Injuries: Shrapnel in R and L thighs, chest. Hospital director added that a bullet in his leg, not previously detected by X-ray, was detected in a CT scan.

Date/time of incident: 21 Jul 2014, around 19:00.

Location of incident: Near Erez Crossing, in a private residence.

Circumstances of injury: During medical evacuation. The patient set out via ambulance to evacuate injured from the bombardment of a house near Erez Crossing next to the border area. After the first injured person was evacuated to the ambulance, the house in which the evacuation was taking place was hit by a drone strike. The patient was wearing a paramedic's uniform at the time.

Others killed/injured in same event: Unknown

Evacuation and care inside Gaza: The patient was immediately evacuated by a Ministry of Health ambulance to the Kamal Edwan hospital, and transferred the following morning to Shifa Hospital in Gaza City, where he stayed for 7 days.

Evacuation out of Gaza: On 28 Jul 2014 the patient was transferred to East Jerusalem. He left Shifa Hospital at 10:30 and arrived in East Jerusalem at 14:00. The ambulance waited one hour before entering Erez Crossing and underwent a quick security check there.

Comments on displacement: None

Comments on rehabilitation: None

1.2 Beit Hanoun

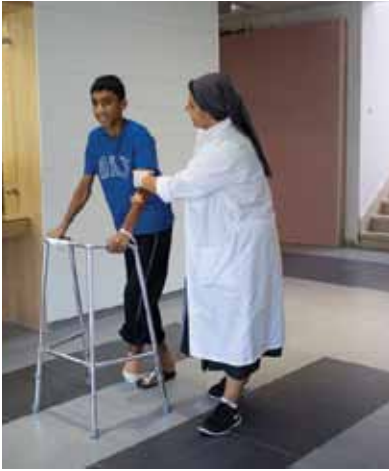

Image by PHR-Israel, St Joseph Hospital, East Jerusalem, 29 Jul 2014

EJJ11

Patient: KN [Minor; name redacted and retained at the offices of PHR-Israel]

Gender: M

Age: 15

Witness: KN [Minor; name redacted and retained at the offices of PHR-Israel]

Date of Interview: 29 Jul 2014

Location of Interview: St. Joseph Hospital, East Jerusalem

Interviewer/s: PHR-Israel staff

Also present: Father of patient

Home address: Beit Hanoun (Abraj Al Awda)

Occupation: 9th grade student

Injuries: L foot amputated above ankle, due to injury by shrapnel.

Date/time of incident: 21 Jul 2014

Location of incident: Beit Hanoun (Abraj Al Awda), in the patient's home.

Circumstances of injury: The patient's family house in Abraj al Awda is very close to Beit Hanoun town. When the bombing started the family moved to a house they hoped would be safer, in the same neighbourhood. They had no food there, and the patient, with his two brothers and his father, returned to the family house to bring food. When they were inside the house a first missile struck; they tried to leave and then a second missile struck and the patient was injured by shrapnel.

Others killed/injured in same event: Unknown

Evacuation and care inside Gaza: The patient went down 5 flights of steps to get out of the house. The ambulance arrived within 5 minutes and evacuated him to Shifa hospital in Gaza City; the journey took 15 minutes. At the hospital his L foot was amputated. The patient remained there for 5 days.

Evacuation out of Gaza: The patient was transferred to East Jerusalem because Shifa Hospital lacked suitable medication and equipment. Arranging the transfer took two days. He was taken from Shifa Hospital to Erez Crossing in a PRCS [*patient said Red Cross-Ed.*] ambulance. They waited at the checkpoint for 90 minutes because there were a lot

1.2 Beit Hanoun

of ambulances ahead of them. Security personnel checked everything, even their hair. Examination of their entry permit took 30 minutes. There was a problem with the coordination so they went first to Maqassad Hospital in East Jerusalem and then to St. Joseph Hospital in East Jerusalem.

Comments on displacement: Unclear whether the family home was completely or only partly destroyed, or if the patient is now displaced.

Comments on rehabilitation: The patient will need crutches; his father asked for help procuring them. According to a medical report received subsequently, the patient was transferred to the Bethlehem Arab Society for Rehabilitation on 31 Jul 2014.

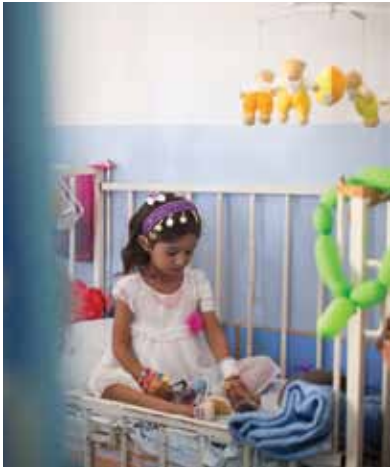

Image by PHR-Israel, St Joseph Hospital, East Jerusalem, 29 Jul 2014

EJJ13

Patient: SM

[Minor; name redacted and retained at the offices of PHR-Israel]

Gender: F

Age: 4

Witness: Patient's aunt, with her in the hospital

Date of Interview: 29 Jul 2014

Location of Interview: St. Joseph Hospital, East Jerusalem

Interviewer/s: PHR-Israel staff

Also present: Patient's aunt

Home address: Beit Hanoun

Occupation: None

Injuries: Shrapnel - internal bleeding

Date/time of incident: 9 Jul 2014, 11:00

Location of incident: In the street in the neighbourhood of the patient's home in Beit Hanoun.

Circumstances of injury: The patient's mother was with four children including the patient, a 15-year-old boy and 17-year-old boy and girl [*the witness didn't mention whether they were twins-Ed.*]. The patient's mother took the children to the doctor as one of the boys had an ear infection and then to visit her sister [*a different aunt from the witness-Ed.*] in Beit Hanoun. Before they reached her sister's house, outside the house, they were hit by a missile

1.2 Beit Hanoun

from a drone. This was a first missile. The mother ran to check on one of the boys and several family members also rushed to the scene to see what was happening. Another missile fell a few minutes after the first. The patient's mother and two brothers and a female cousin who had rushed to the scene were killed by the second missile. The patient held her older sister's hand the whole time and the shrapnel fell over both of them. Her sister had internal bleeding and died shortly afterwards. The patient was conscious the whole time and saw everything.

Others killed/injured in same event: 5 members of the patient's family were killed. Number of injured unknown.

Evacuation and care inside Gaza: The patient was evacuated to Beit Hanoun Hospital and from there she was taken by her aunt (the witness) to Shifa Hospital in Gaza City. She was injured by shrapnel that went right through her body. The x-rays didn't show anything inside, but there was internal bleeding and she started vomiting blood.

Evacuation out of Gaza: The patient was transferred to St Joseph Hospital in East Jerusalem. No details were provided regarding her journey there.

Comments on displacement: None.

Comments on rehabilitation: Interviewer comment at interview: the child looks physically well and can walk on her own.

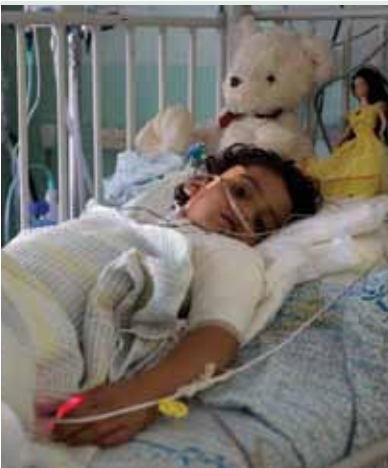

Image by PHR-Israel, Maqassad Hospital, East Jerusalem, 29 Jul 2014

EJM14

Patient: AA [Minor; name redacted and retained at the offices of PHR-Israel]

Gender: F

Age: 5

Witness: The patient's mother ('Umm Ahmad'), with her in the hospital

Date of Interview: 29 Jul 2014

Location of Interview: Maqassad Hospital, East Jerusalem, Children's Intensive Care Unit

Interviewer/s: PHR-Israel staff

Also present: The patient's mother ('Umm Ahmad')

1.2 Beit Hanoun

Home address: Beit Hanoun

Occupation: None

Injuries: Fracture L scapula - severed nerve to area, L arm paralysed; spleen injury; pneumothorax - chest drain inserted and subsequently removed.

Date/time of incident: 22 Jul 2014

Location of incident: Outside a grocery store in the neighbourhood of the patient's home.

Circumstances of injury: The patient was playing near the neighbourhood grocery. Many people were in the area. She was hit by a missile from a drone or a tank, the witness does not know which.

Others killed/injured in same event: None

Evacuation and care inside Gaza: The patient was evacuated by medical personnel from an international organisation; they were wearing medical personnel vests. She was taken within 10 minutes to Beit Hanoun Hospital, and was transferred a short time later by ambulance to Shifa Hospital in Gaza City, where she remained for 2 days.

Evacuation out of Gaza: The patient was transferred to Maqassad Hospital in East Jerusalem and is currently in the Children's Intensive Care Unit.

Comments on displacement: None

Comments on rehabilitation: Rehabilitation will be necessary.



J10

Patient: OA

[Minor; name redacted and retained at the offices of PHR-Israel]

Gender: M

Age: 14

Witness: OA [Minor; name redacted and retained at the offices of PHR-Israel] and his brother, Muhammad

Date of Interview: 30 Aug 2014

Location of Interview: Medinat Hussein Al Tibbeya Hospital, Amman, Jordan

Interviewer/s: Alicia Vacas

Also present: The patient's brother, Muhammad

Home address: Beit Hanoun (Abu 'Awuda Street) -

1.3 Beit Lahiya

a rural area, not densely populated

Occupation: 9th Grade student

Injuries: Fracture to L arm with bone and muscle tissue loss.

Date/time of incident: 24 Jul 2014

Location of incident: UNRWA school shelter in Beit Hanoun

Circumstances of injury: On 15 Jul 2014 the family received a warning to leave their house in Beit Hanoun and took refuge in the local UNRWA school. On 24 Jul 2014 the school was hit by 15 tank missiles.

Others killed/injured in same event: 21 people were killed in the attack including the father of the patient. About 500 were injured.

Evacuation and care inside Gaza: The patient was evacuated by ambulance. It took more than 30 minutes to evacuate due to the ongoing barrage, the great number of victims and the general chaos. He was taken to Beit Hanoun Hospital, but it was overwhelmed by the number of injured and dead, so he was transferred first to Kamal Edwan Hospital and then to Shifa Hospital in Gaza City, where he spent 3-4 days before being referred to the Jordanian Hospital in Gaza.

Evacuation out of Gaza: At the Jordanian Hospital in Gaza the patient was selected by a committee to be sent to Medinat Hussein Al Tibbeya Hospital in Amman, Jordan. They left Gaza on 6 Aug 2014 in a convoy of 6 ambulances. The trip was long, from 14:00 to 23:00. At Erez Crossing the soldier tried to open the patient's dressings and to manipulate the external fixation; this was extremely painful and he started crying and shouting, so the soldier gave up.

Comments on displacement: None

Comments on rehabilitation: Several graft operations and external fixation were performed. Patient was expected to undergo bone transplant after 6 weeks. Will need rehabilitation.

1.3 Beit Lahiya

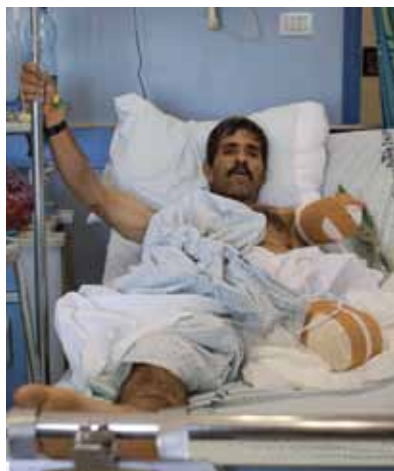

Image by PHR-Israel, St Joseph Hospital, East Jerusalem, 29 Jul 2014

EJJ19

Patient: Mansour Awad Khalil

Gender: M

Age: 51

Witness: The patient's brother. He was not present during the incident but the patient had difficulties talking following his injury.

Date of Interview: 29 Jul 2014

Location of Interview: St. Joseph Hospital, East Jerusalem. The patient was seen a second time at the Bethlehem Arab Society for Rehabilitation in Beit Jala, West Bank, on 4 Aug 2014.

Interviewer/s: Alicia Vacas and PHR-Israel staff

Also present: The patient's brother

Home address: Beit Lahiya

Occupation: Donkey cart driver

Injuries: L above knee amputation, L above elbow amputation, chest wound on L side.

Date/time of incident: 17 Jul 2014, about 08:00

Location of incident: In yard of patient's home in Beit Lahiya.

Circumstances of injury: The patient and 13 members of his family including his wife, their seven daughters and two sons, an aunt and two nephews were sitting together in the yard of their home at *Iftar* [the daily meal to break the Ramadan fast-Ed.]. As soon as they had finished their meal a 'warning missile' hit the house of their neighbour.¹ The entire family went back inside except for the patient, who continued to drink his coffee. Another missile of the same type fell in the yard of his home and caused him these injuries.

Others killed/injured in same event: None

Evacuation and care inside Gaza: An ambulance arrived in the vicinity of the incident after 15 minutes but didn't know how to reach the house, so neighbours carried the patient on foot to the ambulance, which was 5 minutes' walk away. It took them 10 minutes to reach Kamal Edwan Hospital, where the amputated limbs were kept and fixation

¹ It is unclear if the patient meant a roof-knock missile or some other type of strike perceived as a warning.

1.3 Beit Lahiya

was performed. After one day the patient was transferred to Shifa Hospital in Gaza City where his limbs were amputated. He remained at this hospital for one week.

Evacuation out of Gaza: The patient was referred to East Jerusalem. The journey to Erez Crossing took 20 minutes. They waited in the ambulance for more than two hours with tanks 'milling around'. Inside the Crossing area they were checked for 10 minutes and then transferred by 'back-to-back' procedure to a PRCS ambulance [*sent from Jerusalem-Ed.*].² At the final watchtower they were stopped and the ambulance was told over the phone by the Israeli military coordinating authorities (District Coordinating Office, DCO) to turn back or they would not be allowed to enter Gaza in the future. The ambulance turned back and the army claimed the driver had been asked to stop and didn't do so. The driver said the gate had been open and no one had asked him to stop. After this explanation the patient's accompanying relative was asked some questions (not his name and address) and within 10 minutes they were allowed to continue. At the hospital he underwent debridement and grafting. PHR-Israel staff was shown a Jerusalem PRCS log of the event with the following data:

09:35 call received

10:52 arrived Erez

13:02 left Erez

14:10 arrived East Jerusalem.

Comments on displacement: Unknown

Comments on rehabilitation: Will need rehabilitation. The patient asked for help procuring prosthetic limbs. According to a medical report received subsequently, the patient was transferred on 31 Jul 2014 to the Bethlehem Arab Society for Rehabilitation, in stable condition.

² Ambulances from the occupied Palestinian territories, with Palestinian number plates, are prohibited by the Israeli authorities from entering Israel or East Jerusalem. For this reason Gaza ambulances were required to meet designated ambulances from East Jerusalem carrying Israeli number plates at the crossing and transfer the patient on a stretcher from one ambulance to the other, in a procedure known as 'back-to-back'. Similar procedures are used for transfer of goods into Gaza. See also Chapter 5 Part B .

1.3 Beit Lahiya

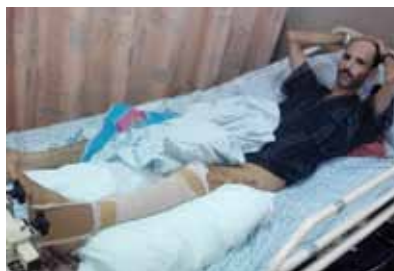

Image by PHR-Israel, Maqassad Hospital, East Jerusalem, 10 Sep 2014

EJM8

Patient: Abd Al Rahman Hamouda

Gender: M

Age: 38

Witness: Abd Al Rahman Hamouda

Date of Interview: 10 Sep 2014

Location of Interview: Maqassad Hospital, East Jerusalem

Interviewer/s: Jennifer Leaning

Also present: PHR-Israel staff

Home address: Beit Lahiya.

Occupation: Agricultural worker

Injuries: L leg fixation.

Date/time of incident: 12 Jul 2014, 18:00.

Location of incident: Outside home on way to water supply tap.

Circumstances of injury: The patient was walking with his son to get filtered water for his home as the water at his home was contaminated. The filtered tap was not far from his home. Before he reached the tap, a drone missile hit the ground near him and he was hit by shrapnel in his L leg.

Others killed/injured in same event: Patient's son also hit; sustained minor injury

Evacuation and care inside Gaza: The patient, who was bleeding considerably, was evacuated by an ambulance called by neighbours, which arrived in 10-15 minutes. He was taken to Kamal Edwan Hospital; the journey took about 10 minutes. He was hospitalised for about 10 days and received external fixation of his fracture. The hospital discharged him but the wound became infected and after one month he 'got help' for a transfer to Maqassad Hospital in East Jerusalem.

Evacuation out of Gaza: The ambulance journey through Erez Crossing was fast - it took 10 minutes to enter; someone with gloves swept over his body to look for powder³ and then he was scanned by someone else very quickly; he does not recall details.

³ According to many patients, procedures at Erez included a body check with gloves whose aim was to check for any residue of explosive materials. See also Chapter 5. Part B.

1.3 Beit Lahiya

He arrived at Maqassad Hospital around 1 Sep 2014.

Comments on displacement: The patient's home is damaged, extent unclear; the windows of the house were smashed.

Comments on rehabilitation: The external fixation was removed and patient is in traction now awaiting surgery for internal fixation. He is concerned that he has not moved his legs in 2 months; he has lost about 5-6 kg according to his brother. The interviewer's impression is rehabilitation should be straightforward with physical therapy for weight bearing and flexibility; no obvious reason now why he could not return to his previous work.

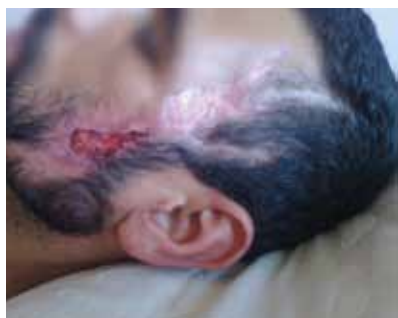

Image by Alicia Vacas, Medinat Hussein Al Tibbeya Hospital, Amman, Jordan, 30 Aug 2014

J11

Patient: RK [Name redacted and retained at the offices of PHR-Israel] (*compare J2 -Ed.*)

Gender: M

Age: 37

Witness: RK [Name redacted and retained at the offices of PHR-Israel]

Date of Interview: 30 Aug 2014

Location of Interview: Medinat Hussein Al Tibbeya Hospital, Amman, Jordan

Interviewer/s: Alicia Vacas

Also present: None

Home address: 'Izbat Beit Hanoun (Abraj al Awla)

Occupation: Hamas officer

Injuries: Head trauma (was in coma for 26 days), L knee trauma, open wound with complications in R leg.

Date/time of incident: 7 Jul 2014.

Location of incident: On a motorbike on Al Manshia Street, Beit Lahiya

Circumstances of injury: The attack occurred on 7 Jul 2014, before the official beginning of the war. The patient was going to work when he met his friend [*name redacted, see interview J2 below-Ed.*], who was riding his motorcycle and offered him a ride. The patient is an officer for Hamas and that morning was carrying some weapons in his backpack. After a few meters a drone hit them with two missiles.

1.3 Beit Lahiya

There was no fighting in the area. According to the patient, the targeting was intentional.

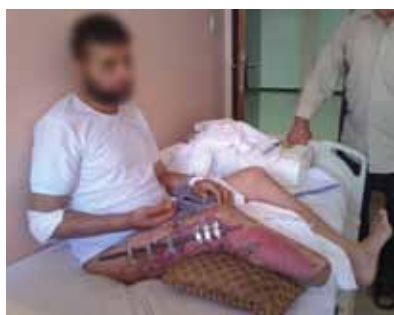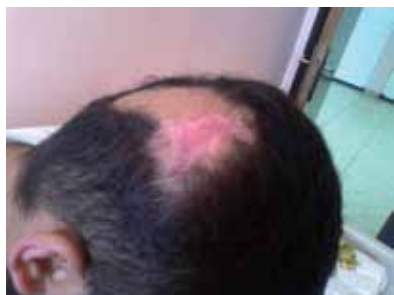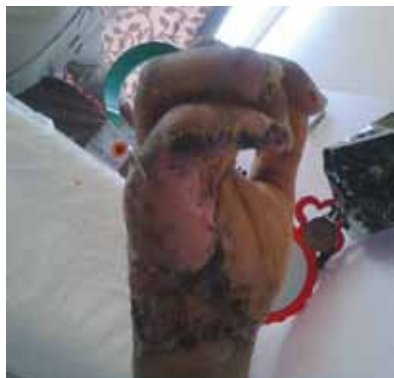Others killed/injured in same event: The driver of the motorbike.

Evacuation and care inside Gaza: People gathered around the place of the incident. The patient was taken to Kamal Edwan Hospital in a car (a van for public transportation), while his friend was evacuated by ambulance. When the patient arrived at the hospital the ER team thought he was dead and moved him to the morgue. When his brother went to collect his body for burial he realized that he was alive. He remained in Kamal Edwan Hospital for 7 days and was then transferred to Shifa Hospital in Gaza City and from there to Amman, Jordan.

Evacuation out of Gaza: The patient was in coma after his injury and cannot remember anything about his treatment in the hospitals, the referral, Erez Crossing or his arrival at Medinat Hussein al Tibbeya Hospital in Amman.

Comments on displacement: None.

Comments on rehabilitation: The patient is bitter and resentful about the treatment he has received at this hospital. Will need rehabilitation; prognosis unclear.



Images by Alicia Vacas, Medinat Hussein Al Tibbeya Hospital, Amman, Jordan, 30 Aug 2014

J2 [compare J11 - Ed.]

Patient: AN [Name redacted and retained at the offices of PHR-Israel]

Gender: M

Age: 28

Witness: AN [Name redacted and retained at the offices of PHR-Israel]

Date of Interview: 30 Aug 2014

Location of Interview: Medinat Hussein Al Tibbeya Hospital, Amman, Jordan

Interviewer/s: Alicia Vacas

Also present: Patient's uncle

Home address: Beit Hanoun, Hay Al Amal, a residential area 1km from the border.

Occupation: Owner of a chicken shop at Beit Lahiya's local market

1.3 Beit Lahiya

Injuries: Amputation R leg below knee, fracture of R femur with external fixation; severe incapacitating trauma to R hand and arm with loss of function; head trauma from shrapnel; open wound in back, requiring 30 stitches; multiple wounds and burns.

Date/time of incident: 7 Jul 2014, 07:30

Location of incident: On a motorbike on Manshia Street, Beit Lahiya

Circumstances of injury: The patient [*referred to in testimony J11 - Ed.*], was attacked on 7 Jul 2014, before the war started. He claims to be the first victim of the war. The patient was going to work at his shop in Beit Lahia local market when he saw his friend [*name redacted, see interview J11 above - Ed.*] and gave him a ride on his motorcycle. He didn't notice any signs of danger. Suddenly two drone missiles hit them directly. The patient thinks that he was targeted intentionally, because the Israeli army suspects anybody riding a motorcycle and often hits them, thinking that they are going to launch rockets.

Others killed/injured in same event: The patient's friend, to whom he offered a ride on his motorcycle, was injured.

Evacuation and care inside Gaza: The patient was evacuated by ambulance to a local hospital. Due to the seriousness of his wounds, he was referred immediately to Shifa Hospital in Gaza city, where he remained for 6 days in ICU in coma.

Evacuation out of Gaza: The patient was referred to Amman on 13 Jul 2014, thanks to the donation of the kingdom of Jordan. The procedure at Erez Crossing was fast and smooth. There were 6 ambulances in the convoy. The patients were not checked, only their accompanying relatives, and transfer was by back-to-back to other ambulances.⁴ The patient has undergone surgery to fix the fracture on his R leg and several skin grafts. Further surgery is needed to remove external fixation.

Comments on displacement: The patient's 5-story house, in which his extended family lived, was destroyed during attacks on Beit Hanoun. His family has taken refuge at an UNRWA school. This is a cause of great distress for the interviewee, who is

⁴ See Note 2.

1.4 Jabalia Refugee Camp



maimed, and aware that his family has no place to stay. Four members of his extended family were killed in different attacks during this war.

Comments on rehabilitation: The injuries will leave serious disability. The patient is tormented by this as he is the head of his household, who are now homeless. He requested aid in support of his family.

J3

Patient: Anas Tayseer Abd ElKarim Al Hinnawi

Gender: M

Age: 23

Witness: The patient's uncle, Ramzi Al Hinnawi

Date of Interview: 30 Aug 2014

Location of Interview: Medinat Hussein Al Tibbeya Hospital, Amman, Jordan

Interviewer/s: Alicia Vacas

Also present: The patient's uncle, Ramzi Al Hinnawi, and mother

Home address: Jabalia Refugee Camp

Occupation: Student of Social Work, Al Quds Open University

Injuries: Shrapnel in head causing hemiplegia L side and loss of vision in R eye; shrapnel in chest with damage to lungs. Condition defined critical; sedated and ventilated.

Date/time of incident: 11 Jul 2014, 12:00.

Location of incident: Outside, on way to mosque in the neighbourhood of the patient's home.

Circumstances of injury: The patient was on his way to pray in the mosque. There was no heavy fire in the area at that time, or he would not have left home. Many men were heading to the mosque for Friday prayers when he was hit by a drone missile.

Others killed/injured in same event: The man who was walking close to the patient, in his seventies, was killed by the explosion. Number of other deaths / injuries unknown.

Evacuation and care inside Gaza: The patient was taken by ambulance to Kamal Edwan Hospital and later on the same day to Shifa Hospital in Gaza City, where he remained in ICU for two more days.

1.4 Jabalia Refugee Camp

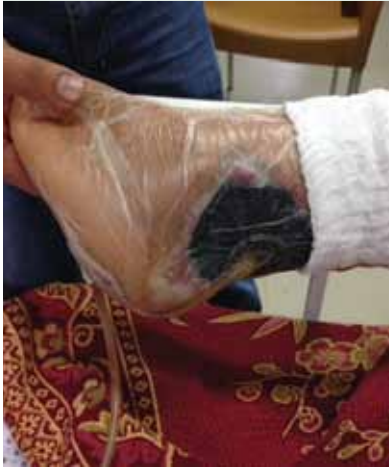

Image by Karen Kelly, St Joseph Hospital, East Jerusalem, 8 Sep 2014

Evacuation out of Gaza: The patient arrived in Medinat Hussein al Tibbeya Hospital in Jordan on 13 Jul 2014.

Comments on displacement: None

Comments on rehabilitation: His condition has not improved and his prognosis is poor according to the testimony of the family and the comments of the head nurse of recovery room. They sought assistance with referral to another hospital.

EJJ2

Patient: Feryal Jadallah

Gender: F

Age: 42

Witness: Feryal Jadallah

Date of Interview: 8 Sep 2014

Location of Interview: St. Joseph Hospital, East Jerusalem

Interviewer/s: Jennifer Leaning

Also present: PHR-Israel staff

Home address: Jabalia Refugee Camp

Occupation: Not specified

Injuries: L ankle/lower foot extensive soft tissue loss

Date/time of incident: 11 Jul 2014

Location of incident: Outside the patient's home in Jabalia Refugee Camp.

Circumstances of injury: The patient was injured by shrapnel from a drone attack outside her home.

Others killed/injured in same event: A boy from the neighbourhood was killed - decapitated; a girl or woman was wounded; a child had extensive burns.

Evacuation and care inside Gaza: The patient was evacuated by ambulance which arrived within 5-10 minutes and was taken to Kamal Adwan Hospital.

Evacuation out of Gaza: On 29 Jul 2014, the patient was transferred to St Joseph Hospital in East Jerusalem where she underwent muscle transplant.

Comments on displacement: Unclear

Comments on rehabilitation: The patient requires plastic surgery evaluation, reconstruction and

1.4 Jabalia Refugee Camp

rehabilitation. She hopes to go to Turkey for further surgery and seeks assistance to this end.

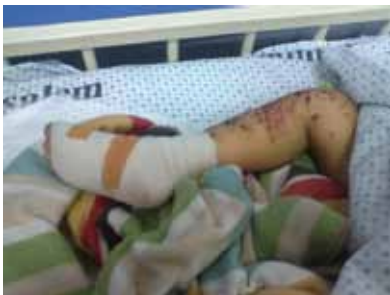
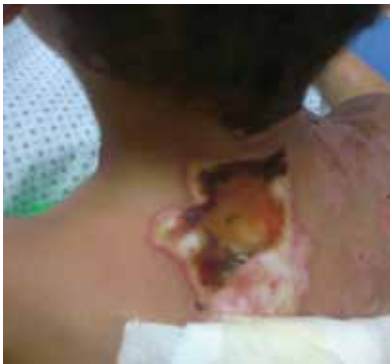
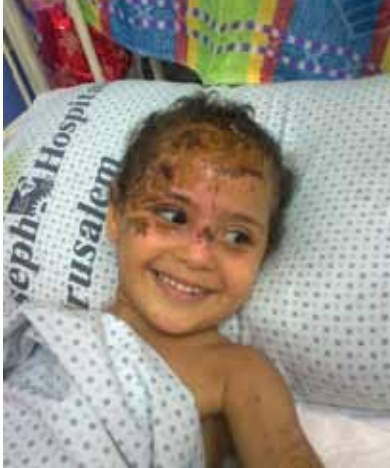Image 7 by Alicia Vacas, St Joseph Hospital, East Jerusalem, 12 Aug 2014

EJJ17

Patient: HA [Minor; name redacted and retained at the offices of PHR-Israel]

Gender: F

Age: 3

Witness: Patient's aunt, Hanaa' (*refuses to give full name*), not present at the incident but heard the details from the patient's father and mother who were present and injured in the same incident.

Date of Interview: 12 Aug 2014

Location of Interview: St. Joseph Hospital, East Jerusalem

Interviewer/s: Alicia Vacas

Also present:

Home address: Jabalia Refugee Camp, Bir al Naja

Occupation: None

Injuries: 2nd degree burns over scalp and back requiring skin grafts; deep wound on right foot requiring skin graft; head injury due to shrapnel: small epidural hematoma in parietal region and subarachnoid haemorrhage of both parietal regions.

Date/time of incident: 30 Jul 2014

Location of incident: In the home of the patient on the 4th floor of a building in Jabalia Refugee Camp (Bir Al Naja)

Circumstances of injury: [*See also interview EJJ18 for circumstances of same event-Ed.*] There was bombing in the area. The patient lived with her family in a 4th floor flat and the whole family was in the flat (father, mother and three children: the patient, aged 3 years, and siblings aged 20 months and 5 months). A missile hit the house, the witness doesn't know where it came from, hitting many members of the family including the patient.

Others killed/injured in same event: [*see interview EJJ18 below -Ed.*]; The patient's sister, 5 months old, was killed. Her mother, Ilham Abu Aida, 30, was severely injured and is in the same hospital,

1.4 Jabalia Refugee Camp

her father and brother, 20 months old, were less seriously injured and are in Gaza.

Evacuation and care inside Gaza: The patient's father rescued her from the rubble and took her to hospital where the wounds on scalp and face were sutured repaired. [*See also interview EJJ18 for further details-Ed.*].

Evacuation out of Gaza: No details regarding evacuation provided. Admitted to St. Joseph Hospital in East Jerusalem where she underwent a brain CT scan and skin grafts to back and neck area and right foot.

Comments on displacement: Home completely or partially destroyed. Alternative accommodation unclear.

Comments on rehabilitation: Will need rehabilitation.

Update: According to a medical report received subsequently she was discharged home in good condition on 4 Sep 2014 with recommendation for follow up with a plastic surgeon and physiotherapy for right foot in Gaza.



EJJ18

Patient: Ilham Saadi Ibrahim Abu Aida

Gender: F

Age: 30

Witness: Ilham Saadi Ibrahim Abu Aida

Date of Interview: 12 Aug 2014

Location of Interview: St. Joseph Hospital, East Jerusalem

Interviewer/s: Alicia Vacas

Home address: Jabalia Refugee Camp, Bir al Naja

Occupation: Housewife

Injuries: R shoulder fracture; thoracic spinal fracture T10-T11 (surgically repaired) no neurological damage; trauma to head, upper limbs and back.

Date/time of incident: 30 Jul 2014, about 16:00

Location of incident: In the home of the patient on the 4th floor of a building in Jabalia Refugee Camp (Bir Al Naja)

1.4 Jabalia Refugee Camp

Circumstances of injury: [See also interview EJJ17 for circumstances of same event-Ed.]. According to the patient there was heavy shelling in the area, both from Apache [helicopters] and tanks. All five members of the family were at home. The patient took the children to the dining room, because the room was internal and thought to be more protected. Her husband remained at the entrance. The 4th floor of the house was hit by a missile/bomb, likely from a tank. The bomb entered the house making a hole in the wall, crossed the entrance and exploded in the room where the patient was with the children, injuring her.

Others killed/injured in same event: The patient's daughter, 5 months old, was killed immediately. Her 3-year-old daughter [EJJ17-Ed.] was severely injured and is in the same hospital; her husband and son, 20 months old, were less seriously injured and are in Gaza.

Evacuation and care inside Gaza: The patient's husband rescued them from the rubble and took the children to the Kamal Edwan hospital. The patient was evacuated by ambulance after about 15 minutes. In Kamal Edwan Hospital, X-Rays were done and, after a diagnosis of fractured vertebrae, the patient was transferred to Shifa Hospital in Gaza City. The CT scanner was out of order there, so she was sent to Al Quds Hospital and then back to Shifa with the results of the CT scan. At Shifa Hospital, the wounds to her scalp were sutured repaired.

Evacuation out of Gaza: The patient was transferred to St Joseph Hospital in East Jerusalem on 11 Aug 2014. Procedures at Erez Crossing were 'normal' but she found the body search extremely painful as she had several fractures and the soldier 'did not know how to move her'. At the hospital she underwent a spine CT and then spinal surgery after which she was admitted to ICU for observation. Patient showed improvement as a result.

Comments on displacement: Home completely or partially destroyed. Alternative accommodation unclear.

Comments on rehabilitation: The patient has undergone surgery to fix the fractured vertebrae and avoid neurological damage. Progress defined as

1.4 Jabalia Refugee Camp

good. Will require rehabilitation.

Update: According to a medical report received subsequently, the patient was discharged home on 4 Sep 2014 in improved condition with recommendation for follow up with gynaecologist, neurosurgeon and GP in Gaza.

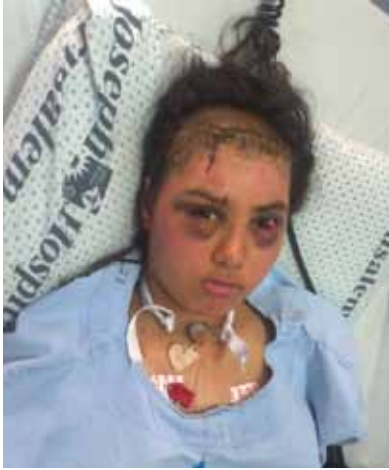

Image by Alicia Vacas, St Joseph Hospital, East Jerusalem, 2 Aug 2014

EJJ23

Patient: TZ [Minor; name redacted and retained at the offices of PHR-Israel]

Gender: F

Age: 15

Witness: The patient's maternal grandmother, Rahma Ibrahim Al Dabbagh (not present at event)

Date of Interview: 2 Aug 2014

Location of Interview: St. Joseph Hospital, East Jerusalem

Interviewer/s: PHR-Israel Staff

Also present:

Home address: Jabalia Refugee Camp

Occupation: N/A 9th grade student

Injuries: Head trauma: Le Fort III fracture (multiple facial bone fractures - broken jaw, broken nose, eye injury); skull base basilar skull fracture; subdural haemorrhage; tracheostomy; lateral right thigh hematoma.

Date/time of incident: 22 Jul 2014, 14:00

Location of incident: In the home of the patient in Jabalia Refugee Camp

Circumstances of injury: The patient's neighbour's house was bombed by aircraft. The patient was playing with her two younger brothers at home, and when she heard the bombing tried to cover her brothers to protect them. The neighbour's house collapsed onto their house injuring the patient.

Others killed/injured in same event: No

Evacuation and care inside Gaza: The patient was evacuated by ambulance promptly to Kamal Edwan Hospital. An hour later she was transferred to Shifa Hospital in Gaza City, where she stayed for 10 days in ICU. Her scalp lacerations were repaired. She required a tracheostomy due to concerns for

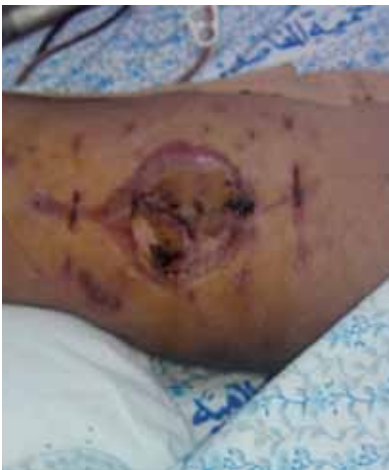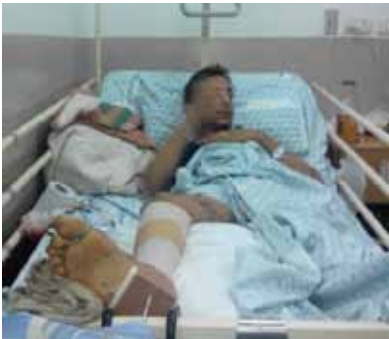1.5 Jabalia

respiratory compromise due to her facial injuries.

Evacuation out of Gaza: The patient was referred to St Joseph Hospital in East Jerusalem after 4 days of hospitalisation in Gaza, but her permit was delayed and patient was only transferred on 31 Jul 2014. The ambulance left Shifa Hospital at 10:00 and arrived in East Jerusalem at 14:00. At Erez Crossing soldiers took a photo of her. At the hospital she underwent CT scans and surgery including maxillary packing.

Comments on displacement: Extent of damage to home unclear.

Comments on rehabilitation: Patient will require rehabilitation. Discharged to her home 26 Aug 2014.



Images by PHR-Israel, Maqassad Hospital, East Jerusalem, 10 Sep 2014

EJM7

Patient: Hamid Zuhair Marzouq

Gender: M

Age: 22

Witness: Hamid Zuhair Marzouq

Date of Interview: 10 Sep 2014

Location of Interview: Maqassad Hospital, East Jerusalem

Interviewer/s: Jennifer Leaning

Also present: PHR-Israel staff

Home address: Jabalia

Occupation: Car mechanic

Injuries: Shrapnel, burns on all parts of body; fixation of lower L leg.

Date/time of incident: 21 Jul 2014

Location of incident: At the patient's home in Jabalia, north Gaza.

Circumstances of injury: The number of people in the patient's household is 13. The patient's building was hit by a sudden succession of four guided missiles from F-16 aircraft, one rapidly after another. After the first hit, everyone tried to flee; the subsequent missiles caught people outside, by the gate.

Others killed/injured in same event: One uncle and one neighbour were killed; another five members of the patient's family were injured. The patient is not

1.5 Jabalia

sure of further details because of the chaos.

Evacuation and care inside Gaza: The patient was evacuated by ambulance, which took 10 minutes to arrive; he was taken to Kamal Edwan Hospital in Jabalia, where he was first thought to be dead; two hours later he was transferred to Shifa hospital in Gaza City where he stayed 1–3 days [*notes unclear-Ed.*]. External fixation of L leg was performed at Shifa Hospital. Due to overflow of patients at Shifa, the patient was then transferred to Ma'amadani Hospital [*former name of Al Ahli Arab Hospital in Gaza City - Ed.*] where he stayed for one month.

Evacuation out of Gaza: Due to infection of his wound, the patient was transferred to Maqassad Hospital in East Jerusalem, arriving there on 20 Aug 2014. At Erez Crossing there were no delays. An Arab man swept over his body with gloves and checked for residue;⁵ a soldier scanned him with a hand-held machine.

Comments on displacement: The patient's family home is completely destroyed. His wife and parents are in Gaza.

Comments on rehabilitation: At Maqassad Hospital, the external fixation was removed (because of infection) and at time of interview he has healing shrapnel wounds of his extremities. He has no hearing problems but decreased sight in his L eye. He is now awaiting internal fixation repair but there is the soft tissue damage, and swelling and the infection demands must be cleared before repair. A drain is in place in his still very swollen leg. Patient is on antibiotics; appears depressed. He has lost considerable weight and muscle mass.

It is too soon to tell how his leg will respond to current treatment or when internal fixation can be applied. If things go well, he will need several months of rehabilitation and physical therapy to regain strength and full weight-bearing use of his leg.

⁵ See Note 3.

1.5 Jabalia

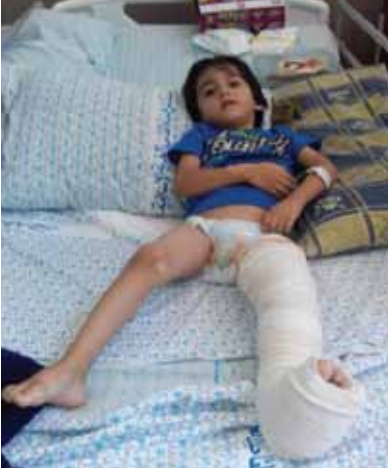

Image by PHR-Israel, Maqassad Hospital, East Jerusalem, 10 Sep 2014

EJM9

Patient: KM [Minor; name redacted and retained at the offices of PHR-Israel]

Gender: M

Age: 4

Witness: The patient's father

Date of Interview: 10 Sep 2014

Location of Interview: Maqassad Hospital, East Jerusalem

Interviewer/s: Jennifer Leaning

Also present: PHR-Israel staff

Home address: Jabalia

Occupation: N/A

Injuries: L leg crush injury

Date/time of incident: 28 Aug 2014 (*after the ceasefire - Ed.*)

Location of incident: In the rubble of destroyed houses in Jabalia, near the home of the patient.

Circumstances of injury: The patient was playing with friends in the rubble of destroyed houses two days after the ceasefire in Jabalia, north Gaza. One of his friends pushed him down a flight of stairs and a large piece of concrete slab with metal fragments jutting out of it fell onto his L leg.

Others killed/injured in same event: None

Evacuation and care inside Gaza: The patient's family extracted him from the rubble with difficulty; he was taken by private car to Kamal Edwan Hospital in Jabalia where the family was told it was not a serious injury; the injury was bandaged and the patient was sent to Shifa Hospital in Gaza City. He remained in Shifa for 5 days and was then referred to Maqassad Hospital in East Jerusalem for skin grafts.

Evacuation out of Gaza: Patient was referred to Maqassad Hospital in East Jerusalem. No comments regarding Erez Crossing. When he came to Maqassad he was febrile and could not move his toes. Operated on 6 Sep 2014; father reports plan to remain another 3 weeks.

Comments on displacement: None

Comments on rehabilitation: Post-war injury in

1.5 Jabalia

rubble; likely to see many more of these. At time of interview patient can move his bandaged leg freely at hip; toes look pink and healthy at end of long bandage. Patient is young and healthy with good support system and receiving definitive care at the hospital. Recovery should be straightforward pending healing of grafts, prevention of infection, physical therapy for range of motion and weight bearing. Excellent prognosis.

EJM10

Patient: IS [Minor; name redacted and retained at the offices of PHR-Israel]

Gender: M

Age: 15

Witness: The patient's uncle, Nabeel Muhammad Sahweil, with him in the hospital. The uncle was not present at the incident described.

Date of Interview: 11 Sep 2014

Location of Interview: Maqassad Hospital, East Jerusalem

Interviewer/s: Jennifer Leaning

Also present: PHR-Israel staff; patient's uncle, Nabeel Muhammad Sahweil

Home address: Beit Hanoun refugee camp

Occupation: N/A

Injuries: Head trauma leading to unconsciousness; shrapnel entered L lower back and emerged L upper quadrant.

Date/time of incident: 30 Jul 17:00

Location of incident: Jabalia Elementary Girls School, used as UNRWA shelter in Jabalia.

Circumstances of injury: The family was sheltering in Jabalia Elementary Girls School that was being used as an UNRWA shelter. While many people were asleep before breaking their fast (*during Ramadan - Ed.*), four missiles hit the school in rapid succession. The patient's family of 8 were sleeping in the school, the men were on the balcony and the women were in the interior. The patient was hit on the head and knocked unconscious, sustaining multiple injuries.

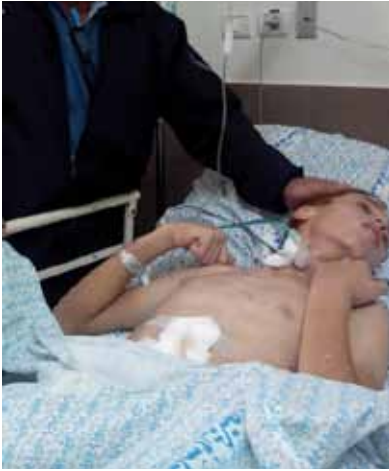

Image by PHR-Israel, Maqassad Hospital, East Jerusalem, 11 Sep 2014

1.5 Jabalia

Others killed/injured in same event: The patient's brother was killed in the incident; his mother and another brother were injured. Seventeen others sleeping nearby in the school (not family members) were killed.

Evacuation and care inside Gaza: Ambulances were called and arrived quickly. The patient was taken to Shifa Hospital in Gaza City and stayed there for three days; he underwent abdominal surgery, splenectomy, craniotomy to remove blood clot.

Evacuation out of Gaza: No comments on Erez Crossing procedure. The patient was transferred to Maqassad Hospital in East Jerusalem, and has now been there for 50 days. Here he underwent a further craniotomy to remove a second blood clot. The patient has twice torn at his tracheostomy and had two respiratory/cardiac arrests, each time with further anoxic brain injury. Currently minimally responsive. Gastric feeding tube; foley catheter. Has lost 30 kg, very thin.

Comments on displacement: Reason for move to shelter (warning / destruction of home) unknown.

Comments on rehabilitation: Patient showing signs of progressive debility (weight loss, contractures) and it is only a matter of time before he begins to have bed sores and urinary tract infections. A long-term skilled nursing facility is required with brain rehabilitation capacities; prognosis for longer term very guarded.

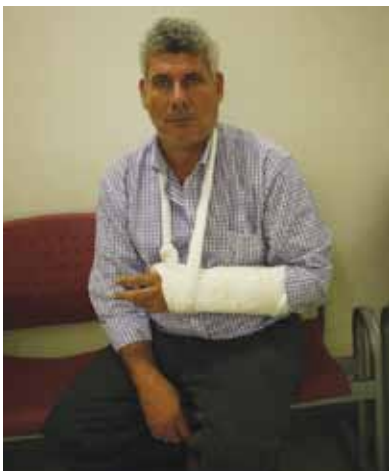

Image by PHR-Israel, Najah Hospital, Nablus, West Bank, 13 Aug 2014

WBN1

Patient: Akram Yousef Ahmad Muqbel

Gender: M

Age: 43

Witness: Akram Yousef Ahmad Muqbel

Date of Interview: 13 Aug 2014

Location of Interview: Al Najah Hospital, Nablus, West Bank

Interviewer/s: PHR-Israel staff

Also present:

Home address: Jabalia village

Occupation: Employee of the Palestinian Authority

1.5 Jabalia

Injuries: L arm fracture

Date/time of incident: 4 Aug 2014, 19:00

Location of incident: In the street outside the patient's parents' home 500m away from his own home in Jabalia village.

Circumstances of injury: The patient was on his way to evacuate his parents from the family home and to take them to his uncle's home. When he reached their address and while getting out of the car the area was shelled and a piece of brick broke his arm and the car window.

Others killed/injured in same event: The patient's father was hit on the head by a stone because of the same shell.

Evacuation and care inside Gaza: The patient and his father were evacuated by ambulance to Kamal Edwan Hospital in Jabalia. Time between injury and evacuation: 10 min. Time between evacuation and hospital: 15 min. He remained at the hospital for one day and his arm was placed in a plaster cast.

Evacuation out of Gaza: The medical reasons for transfer to Najah Hospital in the West Bank are unclear. No details on procedure.

Comments on displacement: None

Comments on rehabilitation: None



WBN4

Patient: Majd Yousef Ahmad Muqbel

Gender: M

Age: 23

Witness: The patient's uncle, with him in the hospital (uncle was not present at the incident but heard the description from the patient)

Date of Interview: 13 Aug 2014

Location of Interview: Al Najah Hospital, Nablus, West Bank

Interviewer/s: PHR-Israel staff

Also present: The patient's uncle and brother

Home address: Jabalia village

Occupation: Unemployed, injured in the 2008 attack on Gaza (shrapnel in R leg, tendon cut; shrapnel in abdomen)

1.5 Jabalia

Injuries: Broken knee caused by bullet.

Date/time of incident: 30 Jul 2014, 16:30

Location of incident: Outside the home of the patient's sister, in 'Izbet Abed Rabbo, east Jabalia

Circumstances of injury: The patient was on his way to his sister's home to bring her to his home because the situation where his sister lives was dangerous.

He went there on foot and before reaching his destination the area came under fire. He was shot in the knee. He did not see who shot him or from where but assumes it was Israeli Special Forces because they broke through that area at that time.

Others killed/injured in same event: Unknown

Evacuation and care inside Gaza: The patient bound his own wound and crawled back away from the source of fire. He was evacuated to Kamal Edwan Hospital in Jabalia but the journey, usually a 10-minute drive, took 1 hour and 15 minutes. He underwent fixation and stayed there until 3 Aug 2014, after which he was referred to Najah Hospital in Nablus, West Bank.

Evacuation out of Gaza: The patient waited for approval of coordination for the ambulance in the hospital on the day of evacuation from 11:00 to 15:00. He then waited at the Palestinian checkpoints [*before Erez Crossing - Ed.*] for 2 hours and 30 minutes. He then waited a further 30 minutes before being allowed by the Israeli forces into Erez Crossing. In Erez Crossing the procedure was 30 minutes, including a body search with gloves, and then they were transferred by 'back-to-back' to an ambulance on the other side. The patient is currently waiting for surgery, which has been twice postponed.

Comments on displacement: According to the patient his immediate family members are scattered among relatives' homes. He is unclear where he will be returning to.

Comments on rehabilitation: The injury will leave permanent disability and the patient will need crutches. He will be cared for by his brother.

1.5 Jabalia

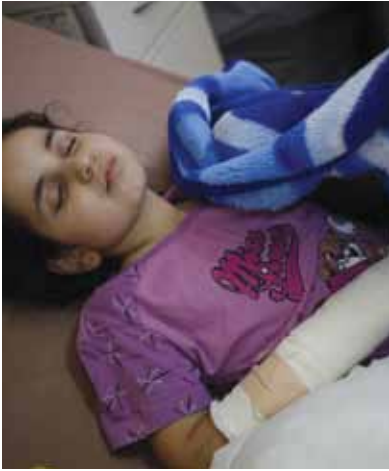

Image by PHR-Israel, Najah Hospital, Nablus, West Bank, 13 Aug 2014

WBN5

Patient: SR [Minor; name redacted and retained at the offices of PHR-Israel]

Gender: F

Age: 8

Witness: The patient's uncle Sami Rehan, who was near the incident at the time.

Date of Interview: 13 Aug 2014

Location of Interview: Al Najah Hospital, Nablus, West Bank

Interviewer/s: PHR-Israel staff

Also present: The patient's uncle, Sami

Home address: Jabalia Town, near Khat al Sharqi'

Occupation: N/A

Injuries: Penetrating shrapnel injury. Entered from the back and caused loss of left kidney, spleen, part of liver and part of small intestine; diaphragm function damaged. One finger of R hand eradicated, tendons and ligaments cut.

Date/time of incident: 30 Jul 2014

Location of incident: At the patient's home in Jabalia Town

Circumstances of injury: One night before the reported incident, the area was under fire from tanks and aircraft, from 23:00 to 02:00. 25 Palestinians were killed in that area as a result, including the Abed Rabbo family. At 09:15, while the patient was eating breakfast, two missiles from an F16 aircraft struck the patient's neighbour's home. Because of shrapnel from this attack the wall next to the patient collapsed, injuring her.

Others killed/injured in same event: Other girls in the room were also slightly injured.

Evacuation and care inside Gaza: The patient was transferred to Kamal Edwan hospital in Jabalia, reaching the hospital 20 minutes after the injury. She underwent multiple surgeries and remained there until 3 Aug 2014.

Evacuation out of Gaza: The patient was referred to Al Najah Hospital in Nablus, West Bank. The journey from the hospital to Erez Crossing took 15 minutes; they waited before the Crossing for 3 hours (they were the first ambulance in line). Inside Erez

1.5 Jabalia

Crossing they underwent a quick security check - the procedure took 20 minutes - after which they were transferred to another ambulance that took them to Nablus. The patient underwent two operations on the R hand as well as several procedures on the digestive system and physiotherapy.

Comments on displacement: The house was damaged and the patient is displaced. She will live in her aunt's home until the family finds a place to rent.

Comments on rehabilitation: Will need extensive rehabilitation and treatment. Is due to return to the hospital three weeks after discharge for follow up.

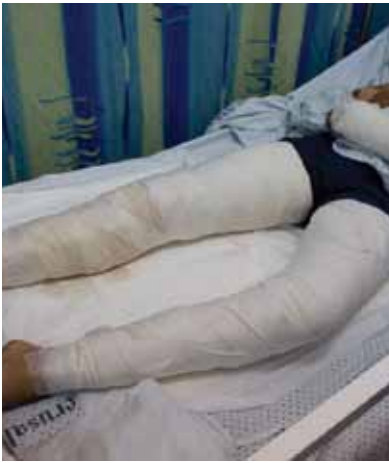

Image by PHR-Israel, St Joseph Hospital, East Jerusalem, 29 Jul 2014

EJJ12

Patient: RM [Name redacted and retained at the offices of PHR-Israel]

Gender: M

Age: 18

Witness: RM [name redacted and retained at the offices of PHR-Israel]

Date of Interview: 29 Jul 2014

Location of Interview: St Joseph Hospital, East Jerusalem

Interviewer/s: PHR-Israel staff

Also present:

Home address: Northern Gaza (exact address not provided)

Occupation: Student

Injuries: Muscle injuries to both legs and one arm

Date/time of incident: 22 Jul 2014, 04:00

Location of incident: At the home of the patient in northern Gaza

Circumstances of injury: There was an electricity cut. The patient went out with his cousin into the stairwell when the house was hit directly by a missile. There had been no warning.

Others killed/injured in same event: The patient's cousin was also injured but remained in Gaza.

Evacuation and care inside Gaza: The patient was promptly evacuated by ambulance to Kamal Edwan Hospital in Jabalia, north Gaza, and after an hour and

a half was transferred to Shifa Hospital in Gaza City.

Evacuation out of Gaza: No details provided.

Comments on displacement: The house was partially or completely destroyed.

Comments on rehabilitation: None provided.

2.1 Al Tuffah



GS1

Patient: Osama Musbah Subhi Al Batesh

Gender: M

Age: 31

Witness: Osama Musbah Subhi Al Batesh

Date of Interview: 20 Aug 2014

Location of Interview: Shifa Hospital in-patient ward, Gaza City

Interviewer/s: Laurel Baldwin, Alicia Vacas

Also present: Patient's mother, two brothers, one cousin.

Home address: Sharia Al Nakhal, Al Tuffah neighbourhood, Gaza City. The five buildings along the street belonged to different members of the Al Batesh family.

Occupation: Police officer

Injuries: Amputation of R leg below knee with phantom limb syndrome; multiple burns to face, chest, back, L lower limb and foot, R shoulder; multiple shrapnel injuries scattered all over body; head trauma with skull fracture affecting visual acuity of L eye; L mandibular fracture.

Date/time of incident: 12 Jul 2014 about 22:00

Location of incident: At the home of the patient's uncle in Sharia Al Nakhal, Al Tuffah neighbourhood, Gaza City.

Circumstances of injury: During Iftar (*the daily breaking of the Ramadan fast, after sunset-Ed.*) that evening the patient was in the 4-story house of his uncle (Tayseer Al Batesh, chief police of Gaza), with many family members, mainly from his uncles' family. The patient's mother, wife and children were in his own house down the road.

The men were sitting together in one room and the women in another, bringing them food and sweets from time to time. They could hear the sounds of many drones but there was no barrage. The patient describes it being somewhat 'quiet.' Suddenly, without warning, two missiles hit the house; according to the patient each one weighed 2 tons. It was a massive blast, destroying not only the house of the patient's uncle, but also three of the buildings around it.

2.1 Al Tuffah

No warning was given to evacuate the building but, twenty days after the attack, the patient's uncle received a telephone call saying that his house was going to be destroyed and that he should evacuate; however, three of the buildings were already reduced to rubble in the first attack and the other two buildings belonging to the family were completely uninhabitable.

Others killed/injured in same event: 20 people were killed in the incident. More than 50 people were injured in this attack.

At the moment of the attack, there were 17 people in the house, including children. All, apart from the patient, were killed:

- The uncle (scalped)
- Two cousins, who were married to one another, as well as their 18-month-old daughter
- Five women of the family (aunts and female cousins), including the wife of one of the cousins in her 6th month of pregnancy. The patient stated that the bodies of the women were found in pieces, and only some parts of them could be recognized by the family (the hand of the aunt, with the wedding ring and the heel of the foot from one of the babies)
- Several children, among them 8 and 10 years old, also died: the children's bodies were found fatally injured, with wounds and amputations. He also remarked that the bodies were 'swollen'.

In the building in front of the uncle's house was another group of family members. Some young men, mainly cousins, were praying, lined up with their backs to the window, when the blast shattered the wall and the rubble hit them. The aunt of the interviewee (sister of his mother) was killed by the explosion, as well as 2 cousins—for a total of 20 people who died during this attack.

Six more men suffered injuries, mainly in the head, neck, shoulders and back. All of them suffered the same type of injuries, since the wall came upon them while they were praying in the same position. There is video of one of the uncles injured by shrapnel, and one of the cousins, wounded in the head and neck, who makes the profession of faith

2.1 Al Tuffah

as he passes away.

In another building on the same street were the mother of the patient (present during the interview), with his wife and 2 small children, 2 and 3 years old. All of them were injured by the broken glass and rubble due to the strong blast, which blew out the window and frame from his house. The patient's wife had head trauma and the younger of his sons had head trauma and broken teeth. The mother was injured by broken glass in her leg. She is a cancer patient, who had a mastectomy in Maqassad Hospital in East Jerusalem four months ago, and chemotherapy.

Evacuation and care inside Gaza: Many neighbours and relatives came to help in the evacuation when they heard the blast. According to the patient, when ambulances arrived, only his head was emerging from the rubble, all his body was buried and he was unconscious. Ambulances arrived promptly but couldn't access the area due to the rubble and destruction in the street. One of the neighbours, whose relative had been also wounded in the same attack, managed to reach Shifa Hospital by private car and gave instructions to the ambulance drivers how to reach the injured. Many other injured reached Shifa Hospital in private cars. At Shifa Hospital, his treatment included below-the-knee amputation of the L leg; multiple debridements and skin grafts; jaw reconstruction. The patient remained in coma for 12 days after the incident.

Evacuation out of Gaza: None

Comments on displacement: The patient is displaced; all the houses belonging to his family are either completely destroyed or uninhabitable.

Comments on rehabilitation: The patient will need constant healthcare post discharge and will not be able to resume his former occupation. Several members of his extended family were killed in different incidents during this war. The patient experiences severe emotional and physical pain and distress. The patient reported that when he realized that he was the only survivor of that house he couldn't bear the pain and the shock, felt dizzy and fainted. The scene repeated several times, because

2.1 Al Tuffah

every time he woke up he couldn't endure the sense of loss and grief. Quote from patient: 'I suffer so much the absence of my family. There is no consolation. You are making us hate so much. Our children have to cheer when a bomb is going to kill other people [*this statement when a Qassam rocket took off nearby-interviewer*]. What have we become?'

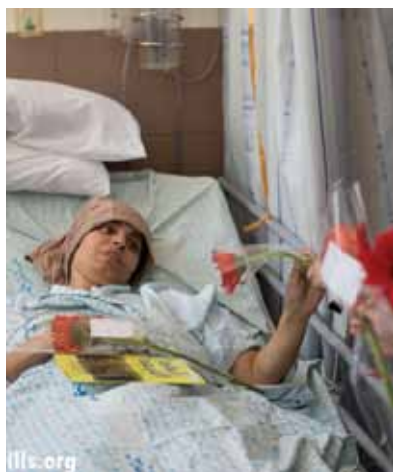

Image by Activestills Maqassad Hospital, East Jerusalem, 29 Jul 2014

EJM17

Patient: Rahmeh Muhammad Al Atawi

Gender: F

Age: 33

Witness: Rahmeh Muhammad Al Atawi

Date of Interview: 29 Jul 2014

Location of Interview: Muqassad Hospital, East Jerusalem

Interviewer/s: PHR-Israel staff

Also present: The patient's sister; Sami, a Palestinian paramedic from an East Jerusalem ambulance service who transferred the patient from Erez Crossing to Jerusalem.

Home address: Al Tuffah neighbourhood, Gaza City

Occupation: Housewife

Injuries: Injury to spinal cord, paraplegia.

Date/time of incident: 20 Jul 2014, 11:00

Location of incident: At home in Al Tuffah neighbourhood Gaza City

Circumstances of injury: The patient was at home, a 3-story house, with 17 other people, all on the second floor in the middle. There were attacks on the Shuja'iya neighbourhood nearby. Family members phoned the patient to tell her to leave the house because of bombings nearby. During the phone conversation with her family she heard a missile strike from a tank. [On her way] from the bedroom to the living room she heard three explosions. Her mother, who was in the house with her, had a broken leg from a prior condition and could not move. The patient tried to get her mother out without success. A tank missile/shell entered the house. It seemed to her that it was aimed at the

2.1 Al Tuffah

second floor where the family was.

Others killed/injured in same event: Others were injured, but the details are unclear to the patient. According to the patient's sister, who spoke to the interviewers separately, her parents and two of her daughters were killed, but the patient has yet to be told.

Evacuation and care inside Gaza: There were no ambulances in the area near the incident because of ongoing attacks by the Israeli army. The patient and other injured were taken to Shifa Hospital in private cars. The patient remained at the hospital for 6 days.

Evacuation out of Gaza: The patient was referred to Maqassad Hospital in East Jerusalem. After being checked at Erez Crossing she was transferred to the Israeli field hospital at the Crossing. All the doctors there wore army uniforms. There was an Arabic translator. They examined the wound on her back and told her that Maqassad hospital 'don't know how to work' and offered to transfer her to Hadassah Hospital (*Israeli hospital in West Jerusalem - Ed.*). The patient was also questioned (*unclear by whom-Ed.*) at the field hospital about how the missile arrived, what they thought about everything that was happening and why they didn't leave the house.

According to Sami, the paramedic who transferred them and accompanied PHR-Israel, his ambulance service receives calls directly from the Palestinian Authority to transfer patients to Maqassad or St. Joseph hospitals in East Jerusalem only, and he is not prepared to transfer to other hospitals as the Palestinian Authority does not commit to pay for treatment there.⁶

Comments on displacement: The patient's home is damaged, extent unclear.

Comments on rehabilitation: The patient is paraplegic.



EJM2

Patient: TR [Name redacted and retained at the offices of PHR-Israel]

Gender: M

⁶ See Chapter 5, Part B.

2.1 Al Tuffah

Age: 38

Witness: TR [Name redacted and retained at the offices of PHR-Israel]

Date of Interview: 10 Sep 2014

Location of Interview: Maqassad Hospital, East Jerusalem

Interviewer/s: Jennifer Leaning

Also present: PHR-Israel staff

Home address: Al Mashahra neighbourhood, Al Tuffah, Gaza City

Occupation: Works at Basma Medical Centre (MA in medical sciences from Islamic University) doing research on male fertility issues

Injuries: Loss of consciousness, conscious at time of interview with decreased vision in L eye; R Leg fixation; L leg fixation; L elbow fixation; hearing in both ears markedly decreased due to blast

Date/time of incident: 21 Aug 2014

Location of incident: In the street near the patient's home in Al Mashahra neighbourhood, Al Tuffah, Gaza City

Circumstances of injury: The patient went out 'to get something' and was 270 m from his home with his two brothers and their two sons and four of his own children, three boys and one girl. The children were running out in front when a drone missile struck the group. He was injured by shrapnel from the missile and could not move.

Others killed/injured in same event: The patient's four children, two brothers and one of their sons were killed. Another son is now disabled as a result of an injury.

Evacuation and care inside Gaza: After the strike, the patient was on the ground and his mobile phone was 4-5 m away; he tried to crawl to reach it but could not. He called out; neighbours came and then he was evacuated by private car to Al Khidma Al 'Ama Hospital in Hai Al Daraj. He was then promptly transferred by ambulance to Shifa Hospital in Gaza City where he spent two weeks, undergoing external fixation of L elbow and L leg and receiving a plaster cast for his R leg. He also had abdominal exploratory surgery for shrapnel in the liver and

2.2 Al Shati Refugee Camp

small intestines. According to the patient the holes in his small intestine were small and were closed without exteriorization of the bowel.

Comment from interviewer: he now has a midline abdominal vertical incisional scar

Evacuation out of Gaza: The patient was transferred to Maqassad Hospital in East Jerusalem. It took 30-45 min to go through the security checks at Erez Crossing with no particular problems. An Arab man with gloves swept across him, collecting residue and then an Israeli soldier did it again. The patient said he thought that the soldier did not trust the first negative test. He was then scanned as well before being allowed through to the ambulance to East Jerusalem. At Maqassad he underwent new internal fixation at L elbow and L leg; said his R leg was healing well in the cast.

Comment from interviewer: abdomen evidently healing well; patient has no abdominal symptoms or pain

Comments on displacement: None

Comments on rehabilitation: The patient's future plans are uncertain. Comments from interviewer: It is too early to assess rehabilitation needs. Mental health will be paramount due to his multiple bereavement. He will also need considerable physical therapy and mobility training for his L elbow and both legs. Latent traumatic brain injury could also be a possibility, given the reported power of the impact and his residual eye and hearing impairment. His current mood is volatile and his long-term mental health issues are likely to be considerable.

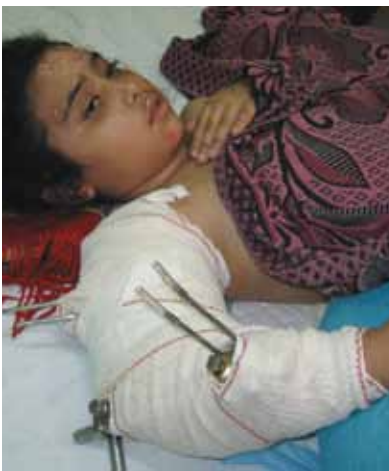

Image by Laurel Baldwin Ragaven, Shifa Hospital, Gaza City, 20 Aug 2014

GS2

Patient: HB [Minor; name redacted and retained at the offices of PHR-Israel]

Gender: F

Age: 9

Witness: The patient's father, Muhammad Ahmad Kamal Al Bakri

Date of Interview: 20 Aug 2014

2.2 Al Shati Refugee Camp

Location of Interview: Burns Unit, Shifa Hospital, Gaza City

Interviewer/s: Laurel Baldwin; Alicia Vacas

Also present: The patient's father, Muhammad Ahmad Kamal Al Bakri

Home address: Block 11, Al Shati Refugee Camp, Gaza City (densely populated area).

Occupation: N/A

Injuries: Burns; shrapnel; R elbow fracture.

Date/time of incident: 4 Aug 2014, 10:07

Location of incident: At home, in Block 11, Al Shati Refugee Camp, Gaza City

Circumstances of injury: A cease-fire had started at 10:00, so the attack happened 7 minutes into the cease-fire. The patient's family lives in a 3-story building, together with the extended family (around 20 members). The flat of the patient is on the second floor. The patient's uncles (father's brothers) live on the floors below and above them. There is a second house, adjacent to the building, where the grandparents and unmarried aunt live. Eight people lived in the flat of the patient: father, mother, four sisters and two brothers.

On the day of the attack, the house was hit directly from the top. They did not know exactly what happened and did not receive any kind of prior warning. Neighbours later told them that two missiles from an F16 aircraft hit the house. The building of the patient was hit from above and collapsed 'like a pancake.' All the other surrounding houses were also damaged.

Others killed/injured in same event: Five people were killed: the mother of the patient (38 years old), two sisters (aged 7 and 4 months, respectively), her uncle (father's younger brother, 32 years old) and his son/her cousin (4 years old).

All survivors of the attack were also injured - 15 family members - as well as 5 neighbours.

The most severely injured is the patient. Her sister, aged 11, was admitted to Shifa Hospital for several days, with burns and shrapnel, and is now discharged. The 3rd floor of the building belongs to the elder uncle, who was not at home at the time

2.2 Al Shati Refugee Camp

of the attack. His wife survived the attack and was admitted to Shifa Hospital, in critical condition. In the small house adjacent to the building lived the grandparents and an unmarried aunt who were all injured in different ways.

Evacuation and care inside Gaza: Evacuation was carried out by neighbours; everyone helped. Injured and casualties were taken to Shifa Hospital in private cars and tok-toks [*three-wheel motor-Ed.*]. The patient has undergone three surgeries thus far to remove shrapnel, skin grafting and debridement for burns (fat pad grafting) and internal/external fixation of her fractured right elbow/arm.

Evacuation out of Gaza: None to date. Doctors have said that the fracture cannot be optimally treated in Gaza, so her case has been referred to a visiting Turkish delegation; the patient will be transferred to Turkey pending permission from Israel who is processing her referral for further treatment.

Comments on displacement: The family home was destroyed and the patient is displaced. The family is renting a flat where all the survivors try to support each other and 'be safe.' The three children who survived the attack are now in the rented flat with the aunt and the grandparents, since their mother was killed.

Comments on rehabilitation: The patient will have need of extensive, long term physical and psychological rehabilitation.



EJJ14

Patient: HA [Name redacted and retained at the offices of PHR-Israel]

Gender: M

Age: 30

Witness: HA [Name redacted and retained at the offices of PHR-Israel]

Date of Interview: 29 Jul 2014

Location of Interview: St Joseph Hospital, East Jerusalem

Interviewer/s: PHR-Israel staff

Home address: Nusseirat Refugee Camp, central Gaza

2.2 Al Shati Refugee Camp

Occupation: Employee of the Palestinian Authority

Injuries: Shrapnel in abdomen with stoma.

Date/time of incident: 22 Jul 2014, 24:00

Location of incident: Shati Refugee Camp, Gaza City

Circumstances of injury: At midnight the patient received a telephone warning from the Israeli army, saying that they were going to attack the house he was in. After all the inhabitants had fled the house they realized that in the panic they had forgotten some small children in the house. The patient went back to fetch a baby and then there was a blast, which injured him. Three minutes after they left, the house was blown up.

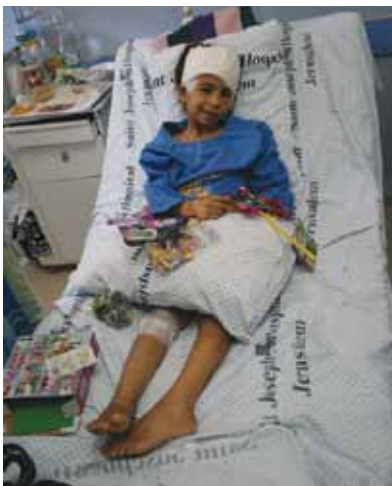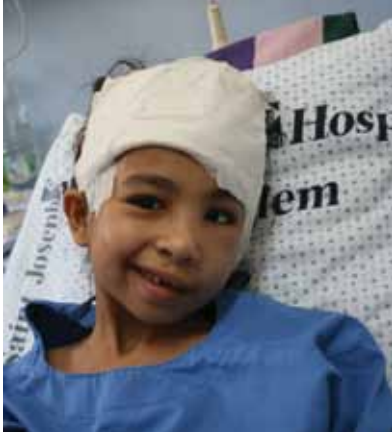Others killed/injured in same event: A 63-year-old man was killed and another 30 were injured.

Evacuation and care inside Gaza: According to the patient the time before and after the incident was very frightening, with attacks from the sky and the sea and it was very difficult to leave the area. There was no electricity. Some people were evacuated in private vehicles but the patient was taken to Shifa Hospital in Gaza City by ambulance. He was there for four days and was then transferred to St Joseph Hospital in Jerusalem.

Evacuation out of Gaza: No details regarding timing or security procedures at Erez Crossing.

Comments on displacement: The house the patient was staying in was destroyed. It is unclear if he is now displaced (home address is in Nusseirat).

Comments on rehabilitation: None.



Images by Önder Özkalıpci, St Joseph Hospital, East Jerusalem, 22 Aug 2014



Shrapnel extracted from wound.
Image by Önder Özkalıpci, St Joseph Hospital, East Jerusalem, 22 Aug 2014

EJJ24

Patient: DR [Minor; name redacted and retained at the offices of PHR-Israel]

Gender: F

Age: 7

Witness: The patient's grandmother, Hana' Ramlawi

Date of Interview: 2 Aug 2014, also seen 22 Aug 2014

Location of Interview: St Joseph Hospital, East Jerusalem

Interviewer/s: PHR-Israel staff

2.2 Al Shati Refugee Camp

Also present: Önder Özkalipci (second visit)

Home address: Shuja'iya, Gaza City

Occupation: N/A

Injuries: In ICU at first interview. Shrapnel in head (*see image for photo of shrapnel extracted on 18 Aug 2014*), entered right posterotemporal lobe and was found in the left anterofrontal lobe, causing injuries to the internal capsule. Full paralysis of left leg, partial paralysis of left hand, dysphasia. Internal bleeding in her skull at the first interview, ICU staff were waiting for the intracranial haemorrhage to resolve before deciding whether or not to operate and remove shrapnel.

At second visit, the patient was post-surgery, in the ward, but staff clarified that left-sided hemiplegia would persist for the longer term as her brain cerebral ventricles are still full of blood.

Note from forensic expert: Medically, I would guess that her hemiplegia is really due to cortical injuries rather than haemorrhage in her ventricles.

Date/time of incident: 28 Jul 2014, 24:00

Location of incident: Shati Refugee Camp, Gaza City

Circumstances of injury: On the first day of Eid Al Fitr, the patient and her mother left their home in Shuja'iya because of the bombings, to stay with her grandparents in Shati refugee camp. The patient and her grandfather were playing on a swing in a playground in the camp when the playground was bombed.⁷

Others killed/injured in same event: 11 others were killed including the patient's grandmother. 50 were injured, including the patient's grandmother and 4 of her cousins.

Evacuation and care inside Gaza: The patient was evacuated by neighbours and later found by the family in Shifa Hospital ICU in Gaza City. She remained in ICU for 3 days and was then referred to St Joseph Hospital in East Jerusalem.

Evacuation out of Gaza: The patient was transferred on 31 Jul 2014, with no delays. She left Gaza at 11:30 and arrived at the hospital at 12:30. On 18 Aug 2014

⁷ For media accounts of this event see Ma'an news, 28.7.2014, in which an Israeli allegation that the playground was hit by Hamas, and not by Israel, is also cited. Available at <http://www.maannews.net/eng/ViewDetails.aspx?ID=716699>.

2.3 Shuja'iyah

she underwent left frontal craniotomy and removal of shrapnel.

Comments on displacement: None

Comments on rehabilitation: Staff at the hospital clarified that the hemiplegia would persist for a prolonged period with possible permanent damage. The hospital recommended referral to the Bethlehem Arab Society for Rehabilitation. According to her medical report she was discharged from the hospital on 2 Sep 2014.



EJM1 (MED3)

Patient: Ahmad Sihel

Gender: M

Age: 25

Witness: Ahmad Sihel

Date of Interview: 10 Sep 2014

Location of Interview: Maqassad Hospital,
East Jerusalem

Interviewer/s: Jennifer Leaning

Also present: PHR-Israel staff

Home address: Zeitoun, Gaza City

Occupation: No regular job; works as volunteer paramedic for PRCS

Injuries: Fixation L lower leg and foot with skin burns from shrapnel from tank shell; now bandaged; patient cannot move his L foot because it is in restrictive soft dressing.

Extensive shrapnel fragment soft tissue injury and burns up and down the entire R leg (bandaged)

Date/time of incident: 30 Jul 2014

Location of incident: In an ambulance in Shuja'iyah neighbourhood, Gaza City

Circumstances of injury: The patient was with another paramedic working with El Sidr family ambulances. They were called to rescue people in Shuja'iyah after an attack by a tank shell on a house. The patient arrived at the site in the ambulance; they had loaded one young girl killed in that shelling, when another tank shell hit the ambulance killing the other paramedic and injuring the patient.

2.3 Shuja'iya

Others killed/injured in same event: The other paramedic was killed.

Evacuation and care inside Gaza: The patient was evacuated to Shifa Hospital with a delay of one hour in evacuation. He remained there for 14 days and underwent external fixation of L leg, and skin grafts for burns and shrapnel. The skin grafts failed to heal.

Evacuation out of Gaza: The patient was transferred to Maqassad Hospital in East Jerusalem. The ambulance was held up for 3 hours before Erez checkpoint but then went through quickly. An Israeli person in uniform and wearing gloves swept his hand all over the patient's body and tested residue on some machine; he also scanned him all over. The patient then left quickly by ambulance to Jerusalem. He left Shifa Hospital at 16:00 and arrived at Maqassad Hospital at 20:00. In total, the patient has had 8 general anaesthesia surgeries (4 of them for skin grafts).

Comments on displacement: None

Comments on rehabilitation: Since arrival at Maqassad Hospital, a new internal fixation was performed and fresh skin grafts applied; the patient is waiting now for these to heal before going home in one week and returning periodically to Maqassad; the first visit will be to receive a special boot to wear for one year. The patient requires rehabilitation. He is not sure if he will resume paramedic work; this depends on the healing of his injuries.



Image by Karen Kelly, Gaza City, 10 Sep 2014

MED1

Interviewee: Yousef Salim Al Kahlout

Gender: M

Age: 32

Date of Interview: 9 Sep 2014

Location of Interview: Interviewee's home

Interviewer/s: Hans Petter Hougen, Karen Kelly, Alicia Vacas

Also present: Two of the interviewee's brothers, Al Mezan fieldworker Muhammad Suleiman, Marwan Diab of the Gaza Community Mental Health

2.3 Shuja'iya

Programme and an interpreter

Occupation: Palestinian Authority employee (unable to work regularly since 2007 Hamas takeover). Uses his free time working as a volunteer paramedic for PRCs. He received first aid training as well as emergency management and passed the test to drive ambulances.

Injuries: Physical injuries (trauma to L shoulder and hip, temporary loss of consciousness) now apparently resolved. Mental health issues paramount with symptoms of PTSD (see comments on rehabilitation below).

Date/time of incident: [30 Jul 2014]⁸

Location of incident: Shuja'iya Market, Gaza City

Circumstances of injury: The interviewee received a call from Shuja'iya, in the east of Gaza City, for evacuation of multiple injuries in the marketplace. An attack had occurred on the 3rd and 4th floors of a nearby building and in the large open space in front of it. When they arrived there was a large fire. Flames were coming from the 3rd and 4th floors and from the ground floor areas of that building. There was a large fire at the marketplace. Fire rescue was present and attempting to put out the fire. A large number of people were attempting to assist others. The interviewee's team was the first to arrive on scene at the empty space in front of the house. The interviewee took a stretcher to go and find injured persons. He was told that bombs had come down on the top of the building. There were 3 paramedics in the ambulance. The driver remained in the ambulance. The other 2 paramedics took stretchers and their medical boxes into the house. The house was 'full of blood'. Many people were dismembered. Many had amputations. The interviewee and his colleagues assessed the situation to determine who was alive in order to evacuate them for help. They found a young girl (about 10-12 years old) who was severely injured with a faint pulse and shallow breathing. When they realized she was alive, they took her down to

⁸ This date was not stated but deduced since the attack on Shuja'iya marketplace as described in the testimony took place on 30 July 2014, according to numerous sources. See also next note below.

2.3 Shuja'iya

the ambulance and then returned to see if others were alive. While they were climbing the stairs to return, several young people were coming down the stairs carrying a severely injured person with skull fractures and brain matter coming out of the head. The interviewee's colleague suggested that the interviewee help these people take this person out and that he would go up to see if others were still alive. While the interviewee was dragging the body down from the 3rd to the 2nd floor, severe shelling began on this house and on the people outside. Due to the blast, they fell to the ground floor. They were lucky as many died in the stairway. They fell onto others' bodies. The interviewee landed hard on his left shoulder and hip and briefly lost consciousness. Then it began 'raining' rockets into the empty space in front of the house where all of the people were gathered. There were many different types of shells. The interviewee believes that they were fired from tanks. He also believes that some of the shells contained gas, as it was difficult to breathe. When the interviewee regained consciousness, he was surrounded by bodies above and below. He saw a light from somewhere and believed it was a window in an adjacent room. He crawled towards the light, which was in the opposite direction of the bombing. He and several others gathered in a room away from the shelling. Many of these people were injured and were bleeding profusely. The interviewee no longer had his medical kit, so he took clothing from the house and used it to attempt to stop their bleeding, including making tourniquets. He also gave directions to others so they could help stop the bleeding of others while they waited. He tried to call the ambulance driver and his dispatch for additional help, but there was no communication (the lines were down). He eventually reached dispatch where the Director answered. The shooting had stopped and the interviewee opened the door. He was traumatized by the sights of the injured and dead in the open space in front of the houses. He couldn't see any of the other paramedics. He went back to check on the young girl, as there had been a direct attack on the ambulance.

A near-by house was also targeted. He gave first aid to some there, but was taken to another house. The situation there was similar; many young women with shrapnel injuries of their face/body. He tried to stop the bleeding. A young man had suffered an amputation. Many other houses were targeted. It was an overwhelming situation, 'like a nightmare,' with people all calling for help everywhere he turned. In the chaos, he found the ambulance driver and they began to work together. Another paramedic team also arrived. They began to organize to take the injured away before the dead were transported. He was working with difficulty breathing and then he collapsed with loss of consciousness. A large ambulance then arrived which took 8 patients (including some dead persons, due to pressure from their families). The Director came himself with about 5-6 ambulances and a large truck. The interviewee was trying to bring more people to the ambulances, but the Director told him to go to the hospital. He went with the first group to the hospital. They continued to attend to the patients in the ambulance who were still bleeding. Many died before their eyes. Doctors and volunteers were waiting at the hospital. The interviewee tried to help with unloading the ambulance and return to the scene. He became very cold, had a headache and couldn't breathe due to the pain in his left shoulder and left side. He looked for his friend who had been taken to Emergency Department for loss of consciousness. He was then hospitalized for observation for 24 hours.

Others killed/injured in same event: Multiple - see above

Evacuation and care inside Gaza: See above

Evacuation out of Gaza: None

Comments on displacement: None

Comments on rehabilitation: Before starting his account, the interviewee asked the interviewers if there was any psychiatric specialist in the team, and made an explicit request for psychological support, since he is deeply disturbed by nightmares, flashbacks and other PTSD symptoms,

2.3 Shuja'iyah

such as anxiety, irritability, oppression, intrusive thoughts, lack of meaning and weight loss (around 7kg). The brothers of the interviewee confirm his need for mental health support services. PRCS has established specialized psycho-social support for its workers, but not for volunteers, so that the interviewee doesn't know how to reach such services. Marwan Diab, who was present at the interview, put him in contact with the Gaza Community Mental Health Programme (GCMHP) and made an appointment for him with Dr Yasser Abu Jame'i, psychiatrist and director of the organization.

MED2

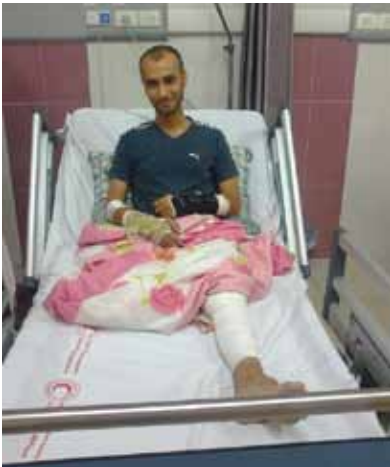

Image by Hans Petter Hougen, Al Quds Hospital, Gaza City, 10 Sep 2014.

Patient: Akram Ahmad Abd El Latif Al Awoor

Gender: M

Age: 38

Witness: Akram Ahmad Abd El Latif Al Awoor

Date of Interview: 10 Sep 2014

Location of Interview: Al Quds Hospital, Gaza City

Interviewer/s: Alicia Vacas, Hans Petter Hougen, Karen Kelly, Louis Reynolds

Also present: Marwan Diab of the Gaza Community Mental Health Programme, interpreter, the patient's brother

Occupation: PRCS paramedic (previously a karate trainer)

Injuries: R leg amputation immediately below the knee; fracture L femur and knee; severe damage to pelvic area including ruptured bladder; many other injuries from shrapnel; septicaemia after 3 days in hospital; urethral stenosis due to incorrect placement of urinary catheter. Patient has had significant weight loss (c. 10kg) and is very thin. Mental health: Can't sleep, when he does he has nightmares / screaming; flashbacks; worst image haunting him is amputated leg. Does not want to eat at times.

Date/time of incident: 30 Jul 2014 (*described as 'third day of the feast of Ramadan' ['Eid Al Fitr']-Ed*)

Location of incident: [*Shuja'iyah Market, Gaza City*]⁹

⁹ This location was not specified but understood, and is compatible with other

Circumstances of injury: The patient was called to an attacked house to evacuate the wounded. He had a photojournalist with him, and another paramedic called Yousef; they had worked together before. When they arrived there was heavy shelling. His was the third ambulance to arrive. When a fourth arrived a shell struck, right in the middle of the 4 ambulances and on the door of his ambulance, killing paramedics and bystanders who had come out to see what was going on. The patient saw his leg amputated, he was fully conscious. He did his own first aid; other paramedics helped to control the heavy bleeding.

Others killed/injured in same event: the photo-journalist and the ambulance driver of the 3rd ambulance were killed, as well as other paramedic/s and bystanders. Others were critically injured.

Evacuation and care inside Gaza: The patient was evacuated to Shifa Hospital where he was rushed to the operating theatre in critical condition due to blood loss. However, due to the high volume of injuries there were no free doctors. Paramedics helped him until he could be admitted to the operating theatre. He remained at Shifa Hospital for 3 days, receiving blood transfusions, treatment for septicaemia. He was then transferred to AlQuds Hospital where the care was reported to be good. Six (6) surgical debridements were performed.

Evacuation out of Gaza: None. Israel refused transfer to Turkey.

Comments on displacement: None

Comments on rehabilitation: The patient wants physical and emotional rehabilitation in Turkey but has been refused access. He was financial provider for his family (wife and 4 children) before these injuries and is now permanently disabled. He wants a prosthetic limb in order to resume his profession.

evidence and with testimonies MED1 and MED6/EJM1 regarding the 30 Jul 2014 attack on Shuja'iya marketplace at which at least 17 people were killed including medics. Footage of the incident described, including the ambulances and the photojournalist who was killed, was shown to the teams during the interview and is available at: <https://www.youtube.com/watch?v=HqBZ-JoxhQY> (warning: graphic). During the first two minutes of the video, 11 consecutive explosions can be heard, at intervals of 10-15 seconds.

2.4 Zeitoun



EJM18

Patient: KM [Minor; name redacted and retained at the offices of PHR-Israel]

Gender: M

Age: 6

Witness: The patient's mother, Nahed Abu Marahin

Date of Interview: 29 Jul 2014

Location of Interview: Maqassad Hospital, East Jerusalem

Interviewer/s: PHR-Israel staff

Also present: The patient's mother, Nahed Abu Marahin

Home address: Zaitoun neighbourhood, Gaza City

Occupation: N/A

Injuries: Head trauma

Date/time of incident: 10 Jul 2014, 10:00

Location of incident: In the home of the patient's uncle near his own home in Zaitoun neighbourhood

Circumstances of injury: The patient was at his uncle's house near his own home. The family has agricultural land next to their homes. The land was hit by two missiles from F-16 aircraft. The patient was knocked over by the force of the explosion and a metal pipe fell on his head.

Others killed/injured in same event: Six others were injured

Evacuation and care inside Gaza: The patient was evacuated by an ambulance, which arrived immediately. He was taken to Shifa Hospital, together with 6 other injured. He remained in the intensive care unit for 5 days and was then transferred to the intensive care unit at the Red Crescent Hospital in Tel Al Hawa.

Evacuation out of Gaza: The patient was referred to Maqassad Hospital in East Jerusalem. He was transferred by ambulance to Erez crossing where they waited 30 minutes before entering. At Erez Crossing the patient was not checked as he was ventilated. They passed through a 20-meter corridor and received an entrance permit and then got on another ambulance to Jerusalem.

Comments on displacement: None

Comments on rehabilitation: Unclear

2.5 Al Naser

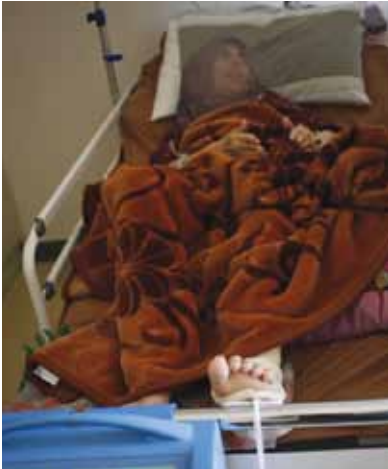

Image by PHR-Israel, Najah Hospital, Nablus, West Bank, 13 Aug 2014

WBN3

Patient: Huda Muhammad Abu Shamala

Gender: F

Age: 52

Witness: Huda Muhammad Abu Shamala

Date of Interview: 13 Aug 2014

Location of Interview: Al Najah Hospital, Nablus, West Bank

Interviewer/s: PHR-Israel staff

Home address: An Naser neighbourhood Gaza City (in front of the Fatouh building)

Occupation: Housewife, with diploma in child education

Injuries: Broken hip; prior condition rheumatoid arthritis and osteoporosis.

Date/time of incident: 8 Jul 2014 (first day of the war)

Location of incident: Outside her home in An Naser neighbourhood Gaza City (in front of the Fatouh building)

Circumstances of injury: The patient, who has suffered for many years from rheumatoid arthritis, slipped on the ground in front of her house and broke her hip joint.

In a separate incident after her return home, and two weeks after the beginning of the war, the Fatouh building, a large structure in front of her family home received an evacuation call from the Israeli army. Some people informed the patient's family that their building would also be attacked. They decided to leave their home due to its proximity to the larger building. However, the patient couldn't move because of her condition and refused to leave with her family. Her son carried her and while they were leaving, the Fatouh building was hit by a missile from aircraft. They went back inside and a second missile hit the Fatouh building. None of them was injured but the condition of the patient's hip deteriorated because of her hurried evacuation (her knees were folded up to her chest).

Others killed/injured in same event: None

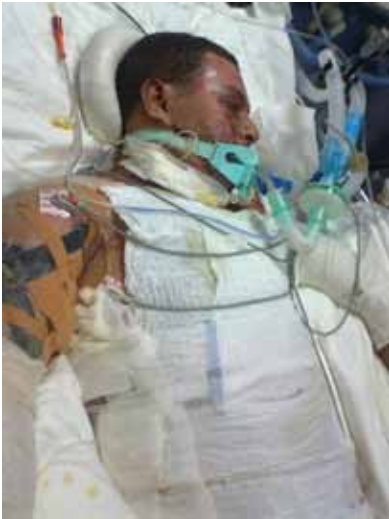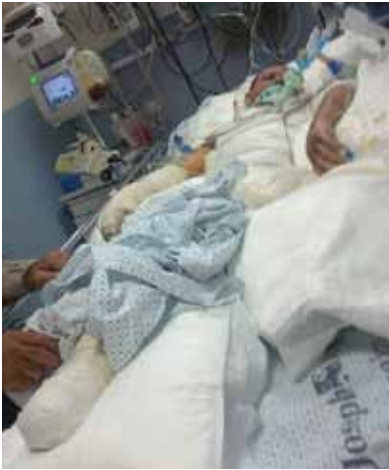2.6 Gaza Beach & Port

Evacuation and care inside Gaza: After breaking her hip the patient went to Shifa Hospital on the same day. She was given fluids for 10 days but was then discharged home because her bed was needed for war injuries.

Evacuation out of Gaza: The patient was referred to Najah Hospital in Nablus on 5 Aug 2014. The journey to Erez Crossing took 20 minutes. At Erez a female soldier wearing a glove/mitten on her hand checked her under her clothes from all sides. The patient said she was using a strange implement like an ultrasound. After the body check they used another device that looked like a hair dryer. The patient was then transferred immediately to the ambulance that took her to Qalandia checkpoint (*in the West Bank - Ed.*), and from there to another ambulance which took her to Nablus. The hospital has yet to make a decision regarding a hip replacement.

Comments on displacement: None

Comments on rehabilitation: Hip replacement surgery is available in Nablus. The patient has been lacking the medications she needs for her prior medical condition for the past two years due to medicine shortage in Gaza.



Images by Alicia Vacas, St Joseph Hospital, East Jerusalem, 2 Aug 2014

EJJ4a / EJJ20

Patient: Jeries George Kamal Ayad

Gender: M

Age: Approximately 30

Witness: Patient's father, George Ayad

Date of Interview: 2 Aug 2014 (first interview); 8 Sep 2014 (second interview)

Location of Interview: St. Joseph Hospital, East Jerusalem

Interviewer/s: Alicia Vacas and PHR-Israel staff (first interview); Jennifer Leaning (second interview)

Also present: PHR-Israel staff; patient's father George Ayad

Home address: Gaza Beach area, Gaza City

Occupation: Student of Computer Studies, Al Quds Open University

Injuries: Brain damage following stroke; extensive burns on torso, arms and face; L leg amputation above knee; R leg amputation at ankle; extubation; patient conscious, eyes track.

Date/time of incident: 27 Jul 2014, 11:30

Location of incident: At the patient's home in the Gaza Beach area, Gaza City

Circumstances of injury: A small bomb hit the roof (*possibly a 'roof-knock' warning - Ed.*) causing damage to the roof and water leakage. The patient's father went out to see what had happened and a second strike hit the house, destroying it and burying the patient and his mother under the ruins.

Others killed/injured in same event: The patient's mother, Jalila, was killed.

Evacuation and care inside Gaza: Relatives and neighbours extracted the patient from the rubble. He was evacuated to Shifa Hospital (mode of transport unclear), where his leg and foot were amputated. The family believes the amputation would not have been necessary had the required experts and equipment been available.

Evacuation out of Gaza: Patient was transferred to St Joseph Hospital, East Jerusalem with a quick and uneventful transit through Erez Crossing. He was transported alone to Jerusalem by ambulance with no companion.

Comments on displacement: The family home is destroyed. The 25-year-old brother of the patient, Anton, is now alone and sleeps in a church. Because the family is Christian, Anton was given the key to the church and asked to be responsible but he is having trouble with other, Muslim youth who are also seeking shelter in the church. The father seeks help bringing the patient's brother out of Gaza to the hospital but the (*Israeli-Ed.*) authorities have not granted this permission.

Comments on rehabilitation: The patient has clinical signs of brain damage; extent is unclear. If able to function (stand up, follow commands) he will need extensive prosthesis work on both extremities and expert training in mobility and use of aids. Need for plastics unclear.

2.6 Gaza Beach & Port

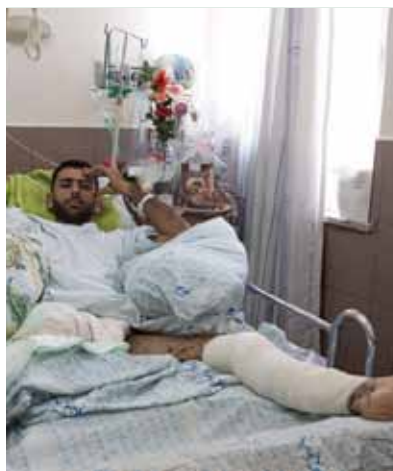

Image by Activestills, Maqassad Hospital, East Jerusalem, 29 Jul 2014

EJM15

Patient: Khamis Zaki Abu Hatsera

Gender: M

Age: 33

Witness: Khamis Zaki Abu Hatsera

Date of Interview: 29 Jul 2014

Location of Interview: Maqassad Hospital,
East Jerusalem

Interviewer/s: PHR-Israel staff

Also present: The patient's uncle, Suleiman Khamis
Khamis Abu Hay

Home address: Near Gaza Port, Gaza City

Occupation: Technician for Jawwal
Telephone Company

Injuries: Amputation of R leg above the knee; fracture of R forearm; loss of hearing in R ear; part or all of intestine removed; shrapnel throughout the body including lower back.

Date/time of incident: 16 Jul 2014

Location of incident: In the street in Gaza City, en route from Shuja'iya neighbourhood (eastern neighbourhood) and Sheikh 'Ijleen (western neighbourhood near the coast)

Circumstances of injury: The patient and two colleagues were in Shuja'iya when they received a call to go to Sheikh 'Ijleen. On their way to the work site they visited the family of a friend who had been killed when his home was bombed (*exact location unclear-Ed*). After visiting the friend's house, which had been badly damaged, they came out and started walking to their car. They had walked about 300-400 meters when the patient suddenly heard the sound of a missile coming very close. He saw the missile 'flash in his eye' and then felt nothing. He remained conscious. When he looked down he saw that the lower part of his R leg was missing and that he was bleeding heavily.

Others killed/injured in same event: One of the patient's friends who was with him had both legs amputated and underwent surgery but died about an hour later. The fate of the third colleague remains unclear.

Evacuation and care inside Gaza: The patient was

taken by private car to Shifa Hospital. It was the day the children had been killed on the beach¹⁰ and there were still Israeli aircraft in the air so many people were afraid to approach the area. At the hospital, the staff were forced to amputate the leg very high, almost to the groin. Two hours after arrival at the hospital, they found that he was bleeding internally. The patient received a blood transfusion and was stabilized. In an attempt to stop the bleeding, he was operated on twice. As he continued to bleed, a laparotomy was then performed. He had three operations within six hours.

Evacuation out of Gaza: It took two days to arrange transfer to Maqassad Hospital. The patient arrived there on 25 Jul 2014. He was delayed at Erez Crossing for a security check but did not go through the field hospital.

Comments on displacement: None

Comments on rehabilitation: The injuries will cause permanent disability and prosthetics and physical therapy are needed. The patient added that his injury is not only that of the amputation, but also the mental anguish to him and his whole family. His whole life has been ruined. He wants the world to know that what is going on in Gaza is a war crime.



Erez1

Patient: Musleh Abd Al Karim Rawag

Gender: M

Age: 21

Witness: The patient's mother, Maha Abd Al Jabbar Rawag

Date of Interview: 8 Sep 2014

Location of Interview: Erez Crossing

Interviewer/s: Alicia Vacas

Also present: The patient's mother, Ibtisam

Home address: Jala Street, Gaza City

Occupation: Tok-tok (*three wheel motor-Ed.*) driver

¹⁰ For a description of the event mentioned see e.g., Guardian news item from 16 Jul 2014, <http://www.theguardian.com/world/2014/jul/16/witness-gaza-shelling-first-hand-account>, accessed 19 Nov 2014.

2.7 Other

Injuries: Maxillofacial injury on left side due to shrapnel, with multiple fractures and complications due to massive blood loss.

Date/time of incident: 22 Jul 2014 between 10:00 and 11:00

Location of incident: At the patient's home, in Jala Street, Gaza City

Circumstances of injury: The victim was in bed with his wife. It was Ramadan and they were in bed late that morning after *sohur* (*last meal before starting the fast at sunrise-Ed.*). At the time there was an intense attack on Shuja'iya. Their house is not far from Shuja'iya and they could see the shelling in the distance, but felt safe because they thought they were far enough from the area. Suddenly the neighbourhood was hit by several missiles from an F16 aircraft, with no warning. A dense cloud of smoke and dust filled the area. A piece of shrapnel entered through the window, hit the opposite wall of the room, and fell on the bed where the patient was sleeping with his wife, injuring him on his left cheek.

Others killed/injured in same event: No

Evacuation and care inside Gaza: The patient's uncle and some neighbours took him to Shifa Hospital in a private vehicle. The ambulance arrived later, when he had already been taken to the hospital, where he had a cardiac arrest, but recovered after Cardio-Pulmonary Resuscitation (CPR) and defibrillation. He was in Shifa Hospital for 5 days and then was referred to St Joseph Hospital in East Jerusalem.

Evacuation out of Gaza: The patient was transferred to St Joseph Hospital in East Jerusalem. During the transfer to Erez Crossing there was shooting on the route and they had to stop for a while. The patient was in serious condition and suffering great pain. At Erez Crossing the procedure took one hour and was 'normal.' He was in ICU at St Joseph Hospital for 4 days and was released back to Gaza on 31 Aug 2014. However they were detained at Erez Crossing because Israeli security found some money on them, which they had been given as donations during their stay in Jerusalem, to continue the medical treatment and to support their family back in Gaza. The amount they had collected was ILS

2.7 Other

43,000 (about \$11,000). Israeli security confiscated ILS 10,000 (\$2,500) and charged the patient's mother with an offense. They were called to a court close to Ben Gurion Airport on 7 Sep 2014 where she was represented by a lawyer from PCHR. They lost the case and the ILS 10,000 were definitively confiscated as a 'fee'.

Comments on displacement: Unclear

Comments on rehabilitation: None



Image by PHR-Israel, Najah Hospital, Nablus, West Bank, 14 Aug 2014

WBN6

Patient: AA [Minor; name redacted and retained at the offices of PHR-Israel]

Gender: M

Age: 9

Witness: The patient's mother, Ibtisam

Date of Interview: 14 Aug 2014

Location of Interview: Al Najah Hospital, Nablus, West Bank

Interviewer/s: PHR-Israel staff

Also present: The patient's mother, Ibtisam

Home address: Jawdat building, Zaitoun Street, Gaza City

Occupation: N/A

Injuries: Sepsis in leg

Date/time of incident: 18 Jul 2014 after 20:00

Location of incident: At the patient's home, in Jawdat building, Zaitoun Street, Gaza City

Circumstances of injury: The family home was shelled and while the family was fleeing the house the patient fell, injuring his leg and aggravating a prior condition (sepsis following three previous injuries to the leg).

Others killed/injured in same event: Unclear

Evacuation and care inside Gaza: No details

Evacuation out of Gaza: The patient was transferred to Najah Hospital, Nablus, West Bank the day after the injury. They left by ambulance at 11:00, arrived at Erez Crossing an hour later, and left Erez Crossing at 14:00. At Erez they were offered medical care (*at the field hospital-Ed.*) but refused it. They then

2.7 Other

travelled by shared taxi to the West Bank to save costs. They were in the hospital by 17:15, more than 6 hours after their initial departure. At the hospital the patient is receiving antibiotics. He uses a wheelchair.

Comments on displacement: The family house is still intact and the patient will return there after discharge.

Comments on rehabilitation: The injury is not expected to cause permanent disability and the patient will not need continuous care.



WBR1a / WBR1b

Patient: Hassan Akram Halaq

Gender: M

Age: 35

Witness: Hassan Akram Halaq

Date of Interview: 26 Aug 2014 (first interview); 8 Sep 2014 (second interview)

Location of Interview: Abu Raya Rehabilitation Center, Ramallah, West Bank

Interviewer/s: PHR-Israel staff (first interview); Jennifer Leaning (second interview)

Also present: None (first interview); Karen Kelly, Prof. Rita Giacaman of Bir Zeit University, Australian visitors, patient's father (second interview)

Home address: Karama neighbourhood, Gaza City

Occupation: Bank of Palestine Employee (MA in IT from Oxford University)

Injuries: Fracture in R femur with fixation, transection of quadriceps muscle just above R knee; perforated eardrum; first-degree burns.

Date/time of incident: 20 Jul 2014, 18:30

Location of incident: At the patient's sister's home in Rimal neighbourhood, Gaza City

Circumstances of injury: The patient had left his home because it was near the border with Israel and moved to his parents' home in Shuja'iya neighbourhood in Gaza City. After the attacks on Shuja'iya began he moved again, to his sister's home in Rimal, a 300sq meter apartment on the

fourth floor of a 9-story building. The extended family was then together, including the patient's father, mother, two brothers and their wives and children, two sisters and their husbands and children, and his own wife and two children. On the evening of the incident, the family were preparing for the daily breaking of the Ramadan fast. The patient's mother, wife, 2 sisters, 2 sisters-in-law and all the children were in the back room cooking; the father, 2 brothers, 2 brothers in law and the patient himself were in the front room, and some children were also playing in the hall between the two rooms. The apartment was suddenly hit by a missile or two missiles (*in the first interview he said 2 on the building; in the second he said one on the apartment-Ed.*) from an F-16 aircraft. There was no warning. Three floors of the building were targeted: the one he was on and the floors above and below it. He found himself on the floor, covered in dust and bleeding from his leg; he felt the burns and his broken bones. Across the hallway he saw his mother under rubble and one of his children, his son, beneath her. Both looked dead. The house was full of smoke.

Others killed/injured in same event: The patient's wife, two children, two sisters, all female in-laws, all nieces and nephews and his mother were killed. The only survivors apart from himself are his father, brothers and brothers-in-law. (*The information regarding the deaths of others was only provided at the second interview; the first interview included details only about the patient's own injury-Ed.*)

Evacuation and care inside Gaza: The patient's brother came to ask him to leave the building with him. At first he refused because he could not move but then his brother helped him down the stairs and he was taken by private car to Shifa Hospital. They arrived within 10 minutes of the incident. There he received external fixation and was transferred to Al Quds Hospital for two more days for supervision and antibiotics.

Evacuation out of Gaza: The patient was transferred to Maqassad Hospital in East Jerusalem on 24 Jul 2014. The ambulance waited for 45 minutes before

2.7 Other

Erez Crossing but then passed through quickly. He was checked with a scanner and by hand and then transferred to another ambulance. He spent 25 days at Maqassad Hospital where the external fixation was replaced by internal fixation, then moved to Abu Raya Rehabilitation Center in Ramallah for rehabilitation. He has received treatment for his eardrum in a private clinic in Ramallah, he expects healing within 6 months.

Comments on displacement: None

Comments on rehabilitation: The physical wounds are healing very well. The patient is in rehabilitation and will need to continue with physical therapy once home. The patient is very composed in the telling of his story but the fact that he completely omitted the story of his multiple bereavement when testifying to the first interviewer (who, unlike the second interviewers, had no previous contact with the patient) is telling. Grief and mental health issues will undoubtedly surface later. The patient wishes to pursue a PhD at Oxford University, continuing his previous studies there.

3.1 Nusseirat Refugee Camp



J4

Patient: HJ [Minor; name redacted and retained at the offices of PHR-Israel]

Gender: M

Age: 2 and a half

Witness: The patient's mother, Faten Abd El Rahman Al Jidi

Date of Interview: 30 Aug 2014

Location of Interview: Medinat Hussein al Tibbeya, Amman, Jordan

Interviewer/s: Alicia Vacas

Also present: The patient's mother, Faten Abd El Rahman Al Jidi

Home address: Nusseirat Refugee Camp in central Gaza

Occupation: N/A

Injuries: Paraplegic due to shrapnel in the back. Spinal cord injury - damage at L3-L4 vertebrae - leading to permanent disability.

Date/time of incident: 29 Jul 2014, 15:00

Location of incident: At the patient's home, in Nusseirat Refugee Camp in central Gaza

Circumstances of injury: It was the second day of *'Eid el Fitr* (the Muslim holiday at the end of the month of Ramadan). There was an intense attack on the area, mainly by tanks shooting at random. It didn't last long, around 15 minutes, but caused massive destruction and the patient's house was partly destroyed. The patient was injured in the back by shrapnel.

Others killed/injured in same event: The patient's younger sister aged 10 months was also injured lightly, but was discharged from the hospital emergency room after receiving first aid without being officially admitted.

Evacuation and care inside Gaza: The patient was taken by ambulance to Shuhada' al Aqsa Hospital and from there to Shifa Hospital in Gaza City, where he underwent surgery to remove the shrapnel from his back. There were complications after surgery and the patient suffered spinal cord fluid leakage. His situation became critical so he was referred to Amman on 6 August 2014.

3.2 Bureij Refugee Camp

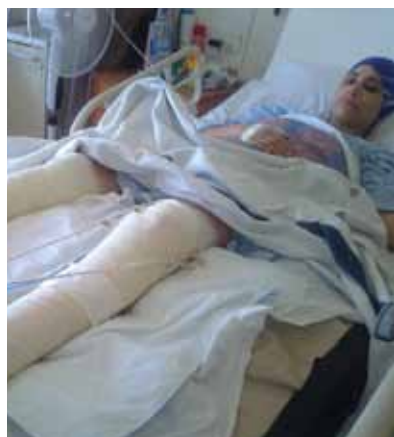

Image by Alicia Vacas, Medinat Hussein Al Tibbeyya Hospital, Amman, Jordan, 30 Aug 2014

Evacuation out of Gaza: The patient left via Erez Crossing in a convoy of 6 ambulances. No issues regarding the procedure.

Comments on displacement: The house was partly destroyed but the family still lives there.

Comments on rehabilitation: The patient is permanently paraplegic.

J5

Patient: Heba Mahmoud Abd Al Rahman Zakout

Gender: F

Age: 33

Witness: Heba Mahmoud Abd Al Rahman Zakout

Date of Interview: 30 Aug 2014

Location of Interview: Medinat Hussein Al Tibbeyya Hospital, Amman, Jordan

Interviewer/s: Alicia Vacas

Also present: The patient's mother, Raja' Zakout

Home address: Nusseirat Refugee Camp, Gaza City

Occupation: Housewife. Husband only partly employed (used to be a labourer for the Petrol Company in Rafah but has not received a regular salary for 5 years as workers are not paid)

Injuries: Multiple fractures in both legs with necrosis and loss of tissue; trauma/wounds in both legs; multiple shrapnel injuries of back and head. Mental health: Depressed, insomnia, flashbacks, nightmares, cries during interview.

Date/time of incident: 27 Jul 2014 around 13:00.

Location of incident: At the patient's home in Nusseirat Refugee Camp in Gaza City.

Circumstances of injury: The patient was alone with her children in her apartment on the second floor, while her husband had gone to Friday prayers. There were tanks on the streets and random shelling. She entered the bathroom to do the ritual washing before prayers and then she heard a first explosion. The house had been hit. The door of the bathroom was torn off its hinges and broke into pieces. The pieces fell on her, pushing her to the ground and wounding her leg. She called out to her children

3.2 Bureij Refugee Camp

and they all came to the bathroom and started crying and shouting at seeing her wounded. At that moment the house was hit a second time and some of her children were wounded. She saw the flesh of her legs flying around her and shouted to the children to leave the house and go down the stairs. As soon as they left the house was hit a third time and completely destroyed.

Others killed/injured in same event: Some of the patient's five children were also injured; no details.

Evacuation and care inside Gaza: Ambulances couldn't reach the area easily because the streets were full of rubble, due to the heavy barrage. It took around 30 minutes to complete evacuation. Paramedics took a long time, up to 15 minutes, trying to help the patient onto the stretcher. Her legs were smashed and 'wouldn't hold together,' and the bleeding was very heavy. The patient was transported by ambulance to Shuhada' al Aqsa Hospital, where she received 11 units of blood and underwent surgery to remove the shrapnel and do some basic debridement. The goal of the surgery was to save her life, but it was decided that the treatment of the wounds should be done abroad. After being stabilized she was referred to Amman.

Evacuation out of Gaza: On 29 Jul 2014 the patient was transferred to Medinat Hussein Al Tibbeya Hospital in Amman, Jordan. The trip was very long and exhausting, since the patient was in serious condition and fainted several times during the trip. The roads in Gaza were bumpy and made her cry out with pain. The security check at Erez Crossing was extremely difficult and painful. They had to wait around 2 hours until all 6 ambulances were checked. A female soldier examined every inch of her body and touched her without taking into consideration her many fractures and wounds. They left the hospital in Gaza at 11:00 and reached the Jordanian hospital around 20:00.

The patient thinks the bombs used against them had some chemical or bacterial components because the three women patients in the room and their accompaniers agree that most patients arriving in Amman had their wounds infected by *Pseudomonas*,

3.2 Bureij Refugee Camp

despite the fact that they were coming from different hospitals.

Note: Pseudomonas is commonly associated with hospital-acquired infections, so it is probable that the patients were infected in the hospital in Amman - Ed.

The patient and her mother also complained of negative attitudes from the hospital staff in Jordan, e.g., when they asked a nurse to replace a leaking catheter / urine collection bag she replied 'go to Gaza and bring your bags'.

Comments on displacement: The family home has been completely destroyed and the children are displaced, staying with relatives. The patient doesn't know where to go with her children, since all the extended family are very poor and it will be difficult to support them in the long term.

Comments on rehabilitation: Will require extensive reconstructive care/prostheses and physical therapy, as well as mental health support.

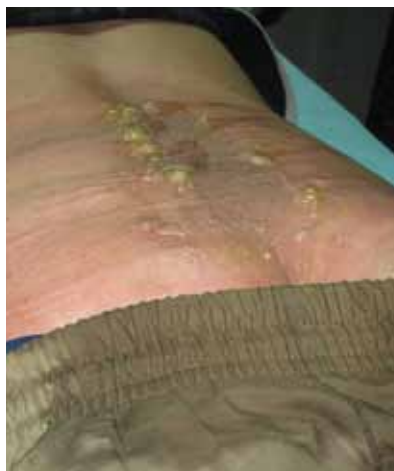

Image by Laurel Baldwin Ragaven, Shifa Hospital, Gaza City, 20 Aug 2014

GS3

Patient: Ibrahim Abdallah Hassan Ahmad

Gender: M

Age: 40

Witness: Ibrahim Abdallah Hassan Ahmad

Date of Interview: 20 Aug 2014

Location of Interview: Emergency department, Shifa Hospital, Gaza City

Interviewer/s: Laurel Baldwin, Alicia Vacas

Also present: Other members of the patient's family (not specified)

Home address: Bureij Refugee Camp central Gaza

Occupation: Farmer / agricultural worker

Injuries: Extended dermatitis with multiple blisters on lower back and buttocks.

Date/time of incident: 19 Aug 2014 from 10:00 to 15:00

Location of incident: The patient's field in Bureij in central Gaza

Circumstances of injury: The patient's home in Bureij had been exposed to heavy shelling

3.2 Bureij Refugee Camp

throughout the attack. On the day of the incident, taking the chance as the area was relatively calm, the patient went to his field and worked from 10:00 to 15:00. He took a break during his work and lay down to rest on the ground. He returned home around 15:00 and, about five hours later (near sunset), he started feeling an intense 'heat' in his body, with pain and itching in the back. In a short span of time the skin of his back became red and irritated and big blisters covered the affected area. He couldn't obtain medical assistance during the night for safety reasons, despite his temperature reaching 42°C (the interviewee affirms that he had the temperature measured with a thermometer).

Others killed/injured in same event: None. The patient was alone in the field.

Evacuation and care inside Gaza: During the morning following the incident, the patient reached Shuhada' Al Aqsa Hospital, where he was advised to go to ER at Shifa Hospital in Gaza City, since there were no specialists available for his case. He reached Shifa Hospital around 18:00 on 20 Aug 2014 (*the day of the interview-Ed.*), and was interviewed and photographed directly in ER, before any treatment was applied to his blisters.

The patient's treating doctor, Awad Shedar,¹¹ a 4th year medical student at the Islamic University, told the interviewers that the lesions could either be explained by chemical contamination of the area during the shelling or by exposure to pesticides or other chemicals used by the farmers themselves. There was no clear evidence of the incident being conflict-related.

Evacuation out of Gaza: None

Comments on displacement: None

Comments on rehabilitation: None. The patient is not expected to need constant healthcare after his discharge and will be able to resume his occupation.

¹¹ The medical student mentioned here provided further information, referred to in Part B, 4.2.

3.2 Bureij Refugee Camp



EJM4

Patient: Reem Salama Nabaheen

Gender: F

Age: 35

Witness: Reem Salama Nabaheen

Date of Interview: 10 Sep 2014

Location of Interview: Maqassad Hospital, East Jerusalem

Interviewer/s: Jennifer Leaning

Also present: The patient's husband (*see also his testimony EJM5 below-Ed.*); PHR-Israel staff

Home address: Bureij Refugee Camp, central Gaza

Occupation: Housewife

Injuries: L leg fixation; R leg soft tissue damage from shrapnel

Date/time of incident: 28 Jul 2014

Location of incident: At the patient's family home in Bureij Refugee Camp, central Gaza

Circumstances of injury: (*see also testimony EJM5 below, of husband injured in same incident-Ed.*) The patient and her family of 5 were living in two rooms on the first floor of a building; a warning(?) missile hit one room and some kind of chemical smell erupted. When the patient and her husband fled to the other room where her parents were staying a second tank missile hit them.

Others killed/injured in same event: The patient's husband was injured (*see EJM5 below-Ed.*)

Evacuation and care inside Gaza: The patient reported there was 'firing' to stop ambulances from getting to them. After an unspecified delay she was taken by private car to Shuhada' Al Aqsa Hospital. At the hospital some Palestinian surgeons trained in Germany wanted to amputate her L leg; she refused and other surgeons at the hospital applied external fixation and discharged her after 5 days. Because her home had been destroyed the family was living in an UNRWA school. She stayed there for 5 days but began to feel very ill. She returned to Shuhada' Al Aqsa Hospital and was referred to Maqassad Hospital in East Jerusalem.

Evacuation out of Gaza: The patient was transferred

3.2 Bureij Refugee Camp

to Maqassad Hospital in East Jerusalem. No details about transfer or check points. At the hospital they removed her external fixation but she needs a bone graft from her pelvis to close the gap in her L leg (evidently considerable bone missing as a result of the initial injury). The patient awaits surgery for bone graft tomorrow (11 Sep 2014).

Comments on displacement: Family home destroyed, the last she heard her family was still living in an UNRWA school.

Comments on rehabilitation: The patient still has surgery ahead and then moderate rehabilitation and physical therapy needs for her L leg including mobility and weight bearing. No other significant injuries. Her mood seems resilient and longer-term prospects for physical recovery look good. However the displacement will be a major issue.



EJM5

Patient: Haidar Hassan Nabaheen (*not a patient but the husband of patient EJM4 above-Ed.*)

Gender: M

Age: 35

Witness: Haidar Hassan Nabaheen

Date of Interview: 10 Sep 2014

Location of Interview: Maqassad Hospital, East Jerusalem

Interviewer/s: Jennifer Leaning

Also present: Patient at EJM4 (the witness' wife), PHR-Israel staff.

Home address: Bureij Refugee Camp

Occupation: Policeman (on behalf of the Palestinian Authority in Ramallah, not Hamas)

Injuries: Shrapnel in chest and abdomen

Date/time of incident: 28 Jul 2014

Location of incident: At the witness' family home in Bureij Refugee Camp, central Gaza

Circumstances of injury: (*See also testimony EJM4 above, of wife injured in same incident-Ed.*) The witness was 'blown out' of the apartment and hit by shrapnel in his chest and abdomen, apparently from

3.3 Deir Al Balah

the same tank missile that hit his wife.

Others killed/injured in same event: The witness's wife was injured (*see EJM4 above-Ed.*)

Evacuation and care inside Gaza: No ambulances could reach them because of 'firing' in the area so the witness was taken by private car to Shuhada' Al Aqsa Hospital; there x-rays showed multiple shrapnel fragments in his R hilar lung and liver but required no further management. He was discharged and released.

Evacuation out of Gaza: None

Comments on displacement: Family home destroyed, the last the witness heard his family was still living in an UNRWA school. He has problems communicating with them as the phone has run out of credit and he was denied an access permit from the Israeli authorities to go to the West Bank to get more money.

Comments on rehabilitation: Still with shortness of breath on any kind of exertion, the patient is worried about his lung function and thinks he might feel the shrapnel in his liver. He needs reassurance about the benign nature of the shrapnel remaining in his lungs and liver and needs rehabilitation regarding breathing and exercise. These issues are straightforward and should be resolvable on an outpatient basis if he is put in touch with a good primary care physician or nurse.

J12

Patient: SK [Minor; name redacted and retained at the offices of PHR-Israel]

Gender: F

Age: 8

Witness: The patient's father, Hilmi Suleiman Al Karnawi

Date of Interview: 30 Aug 2014

Location of Interview: Medinat Hussein Al Tibbeya Hospital, Amman, Jordan

Interviewer/s: Alicia Vacas

Also present: The patient's father, Hilmi Suleiman Al Karnawi

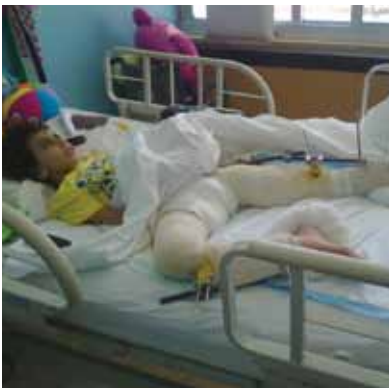

Image by Alicia Vacas, Medinat Hussein Al Tibbeya Hospital, Amman, Jordan, 30 Aug 2014

3.3 Deir Al Balah

Home address: Block 7, Bureij Refugee Camp, central Gaza

Occupation: N/A 2nd grade student. Patient's father is a policeman.

Injuries: Multiple fractures with necrosis and extensive loss of bone and tissues in both legs and left hip; external fixation to latter; multiple shrapnel injuries to head, chest and legs

Date/time of incident: 11 Jul 2014, 10:45

Location of incident: At the patient's home in Block 7, Bureij Refugee Camp, central Gaza

Circumstances of injury: The patient was born blind. She goes to a special school for visually impaired children and is a bright second grade student. On the day of the incident she was playing with her elder 9-year-old sister in one of the rooms of the house. The whole family was at home in another room. A missile hit a car in front of the house. The explosion destroyed the door of the house and the room where the two sisters were playing. No one in the family realized where the missile was coming from or had any notice or warning about the attack.

Others killed/injured in same event: The patient's sister was injured.

Evacuation and care inside Gaza: The patient's father took the two sisters to Shuhada' Al Aqsa Hospital himself, since there was destruction and confusion on the street and it was difficult for ambulances to reach the place. The patient's sister was admitted while the patient was transferred by ambulance to Shifa Hospital in Gaza City due to the severity of her wounds. Her sister is recovering from her wounds in Gaza, but will need plastic surgery to reconstruct the right side of her face, which has been badly damaged by the explosion.

Evacuation out of Gaza: On 13 Jul 2014 the patient was transferred to Medinat Hussein Al Tibbeya Hospital in Amman, Jordan, where, after a few days in ICU, she is now in the paediatric rehabilitation ward. She has undergone several operations in her legs, mainly for debridement. Reconstructive surgery will take place at a later stage.

Comments on displacement: The patient's home is

3.3 Deir Al Balah

damaged but habitable.

Comments on rehabilitation: The patient is aware, conscious and oriented. Responds to the questions and corrects her father's (the witness') account when she doesn't agree with it. Her father comments with pride that the patient is a fighter, she has always struggled to overcome her blindness and be independent. He gets very emotional when he mentions that her wounds are a blow, a new overwhelming obstacle to her daily life. He doesn't doubt that the girl will eventually 'make it', but is well aware of how much support, effort, money and rehabilitation she will need in the future.

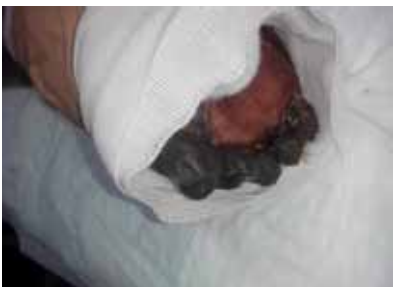
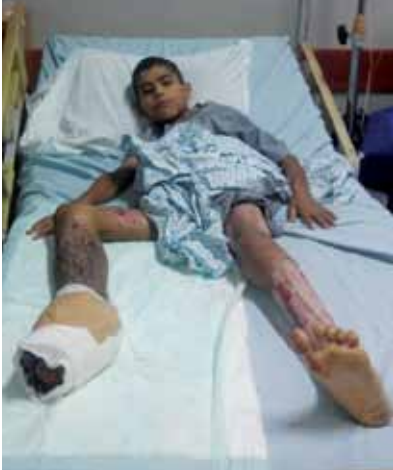
Image by PHR-Israel, Maqassad Hospital, East Jerusalem, 10 Sep 2014

EJM6

Patient: ON [Minor; name redacted and retained at the offices of PHR-Israel]

Gender: M

Age: 12

Witness: The patient's uncle, Zohair, who was not present at the incident

Date of Interview: 10 Sep 2014

Location of Interview: Maqassad Hospital, East Jerusalem

Interviewer/s: Jennifer Leaning

Also present: PHR-Israel staff, the patient's uncle, Zohair

Home address: A two-story compound in Deir Al Balah, central Gaza

Occupation: N/A (6th grade student)

Injuries: Extensive soft tissue damage to lower calf muscle belly of the R leg and R foot; deep vascular compromise of blood flow to R toes; relatively superficial concrete and metal soft tissue injuries to L leg.

Date/time of incident: No date

Location of incident: In the home of the next-door neighbours of the patient's family home in Deir Al Balah, central Gaza

Circumstances of injury: The patient was visiting neighbours who lived next door in a single story

3.3 Deir Al Balah

house with a zinc roof. There were about 10 members of this neighbouring family in that house. The patient was sleeping there, and everyone else in the single-story house and in the patient's 2-story family compound next door were awake. A missile from an F-16 aircraft suddenly struck a large 4-story housing complex situated immediately behind both the small zinc-roof house and the family 2-story compound. This large housing complex crumbled and fell forward onto the two dwellings in front of it, trapping people in the rubble.

Others killed/injured in same event: Everyone got out safely except for the patient, because he had been sleeping and did not move quickly enough.

Evacuation and care inside Gaza: It took half an hour to rescue the patient; his R leg was buried under rubble that included fragments from the zinc roof and metal from reinforced concrete, as well as concrete. Finally the patient's father and other family members had to drag the boy out of the rubble (because they could not lift it to free him completely), which resulted in extensive ripped muscle and soft tissue injuries to his R lower leg and foot. He was then taken by ambulance to Shuhada' Al Aqsa hospital; he was there for 3 days, and dressings were applied, and was then transferred to Shifa Hospital in Gaza City where he stayed 6 days. Physicians from Norway wanted to amputate his L leg but a family member refused. Doctors from Maqassad Hospital in East Jerusalem were visiting Shifa Hospital, saw the patient and his injury, and arranged for his referral out of Gaza.

Evacuation out of Gaza: No details were provided regarding crossing procedures. At Maqassad Hospital in East Jerusalem, there was extensive debridement of all soft tissue wounds, and skin grafts were applied to the entire L upper and lower leg and to R upper leg; with repair to muscle damage to R lower leg. He is being carefully monitored to assess the full extent of vascular compromise to the toes of the his R foot. The patient's uncle reports that when they reached Maqassad Hospital, the toes were still pink. Currently, the top superior aspect of the four toes that can be seen under the dressing

3.3 Deir Al Balah

are deep black. A small margin of pink skin on the plantar aspect of the toes can be seen. The head nurse at the hospital said an assessment is planned in a few days regarding blood flow. The plan will be to amputate the toes once the extent of the vascular injury is fully defined.

Comments on displacement: The house is extensively damaged and family prospects are unclear as they have no funds for repairs.

Comments on rehabilitation: Current surgical course is not clear, but probably will result in amputation of more than one toe. It has not been determined if the surgical demarcation line will extend onto the lower foot. There are no signs of infection, so rehabilitation should be relatively simple.'

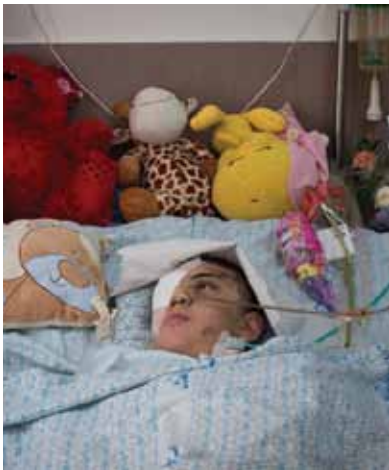

Image by PHR-Israel, Maqassad Hospital, East Jerusalem, 11 Sep 2014

EJM12 / EJM16

Patient: SM [Minor; name redacted and retained at the offices of PHR-Israel]

Gender: F

Age: 14

Witness: The patient's uncle, Abu Tareq (first interview); the patient's father (second interview)

Date of Interview: 29 Jul 2014 (first interview); 11 Sep 2014 (second interview)

Location of Interview: Maqassad Hospital, East Jerusalem

Interviewer/s: PHR-Israel staff (first interview); Jennifer Leaning (second interview)

Also present: The patient's uncle, Abu Tareq (first interview); the patient's father (second interview)

Home address: Deir Al Balah, central Gaza

Occupation: N/A 10th grade student

Injuries: First interview observation: head injury with direct damage to brain, Hemorrhage in brain, tracheostomy to enable breathing, unconscious state. Second interview observation: experienced serious head injury; now conscious but cannot speak or move her lower legs; also R arm injury or paralysis. Requires tracheostomy and gastric tube feeding.

3.3 Deir Al Balah

Date/time of incident: 11 Jul 2014, 06:00

Location of incident: At the home of the patient in Deir Al Balah, central Gaza

Circumstances of injury: 11.7, 6 am. The patient was asleep at home in her bedroom. A drone missile came in through the window and exploded.

Others killed/injured in same event: None. The other family members (grandmother, siblings and parents) were in the other room and were not injured.

Evacuation and care inside Gaza: Neighbours arrived and rescued the patient from the rubble and called an ambulance. Initially she was taken to Shuhada' Al Aqsa Hospital in Deir al-Balah, where she received first aid. Soon after she was transferred to Shifa Hospital in Gaza City. On arrival she was in cardiac arrest and was presumed dead, but successful Cardio-Pulmonary Resuscitation (CPR) was performed. From Shifa Hospital she was transferred to the intensive care unit at the Red Cross hospital. Representatives from the local group Palestinian Centre for Human Rights (PCHR) in Gaza visited her and on seeing her condition, recommended that she be transferred to a hospital outside Gaza.

Evacuation out of Gaza: The patient was transferred to Maqassad Hospital in East Jerusalem on 17 Jul 2014. In the field hospital (*at Erez Crossing-Ed.*) they did the best that they could and the uncle thanks them.

Comments on displacement: Home damaged, extent unclear.

Comments on rehabilitation: Needs skilled long-term nursing care; has been accepted by Abu Raya Rehabilitation Centre in Ramallah, West Bank, but the family has no funds to cover costs. In the first interview, the witness asked the interviewer to put pressure on the Israeli government to understand that the people of Gaza are not terrorists. They are ordinary people that love life and peace. The Palestinians are simple people who want to lead normal lives.

3.3 Deir Al Balah

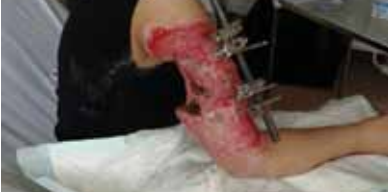

Image by Alicia Vacas, Medinat Hussein Al Tibbeya Hospital, Amman, Jordan, 30 Aug 2014

J6 (MED5)

Patient: Iman Hassan Hashem Al Katrawi

Gender: F

Age: 32

Witness: Iman Hassan Hashem Al Katrawi

Date of Interview: 30 Aug 2014

Location of Interview: Medinat Hussein al Tibbeya Hospital, Amman, Jordan

Interviewer/s: Alicia Vacas

Also present: The patient's sister-in-law

Home address: Ard Mufti, Nusseirat, central Gaza. During the attacks she was displaced and staying with her family in Nusseirat Refugee Camp, where her relatives live.

Occupation: Nurse at Shuhada' Al Aqsa Hospital, Deir al Balah in central Gaza

Injuries: Wound of R arm with transaction of artery, humerus fracture, nerve damage, skin burns and loss of muscle tissue; fractured ribs.

Date/time of incident: 21 Jul 2014, 14:00

Location of incident: Shuhada' Al Aqsa Hospital, Deir al Balah in central Gaza

Circumstances of injury: The patient's injuries occurred during the attack on Shuhada' al Aqsa Hospital, where she was working on her regular shift as a nurse. On the day of the incident, the patient went to work as usual by public transport to Shuhada' Al Aqsa Hospital. Shortly after her arrival, heavy shooting started around the hospital. From the balcony she saw some cars belonging to the ___ family¹², who were carrying a 'martyr' [*description given to anyone killed in attacks by Israel-Ed.*] to the hospital. Two cars were shelled just in front of the hospital and four people were killed in this incident. Following this, in a short period of time, the hospital was hit 15 times by tanks. The first missile hit the male surgery ward. Staff and visitors started immediately evacuating the patients, as the shooting (sic) continued. Four more people were killed: two patients and two visitors. The patient felt a sharp pain in her R arm and saw fire coming out of

¹² Name redacted and retained at PHR-Israel offices: consent not given for publication.

3.3 Deir Al Balah

it. She supported this arm with her left hand and ran for her life. Some colleagues helped her down the stairs and a doctor put out the fire. Only then did she see a large piece of shrapnel stuck to her arm.

Others killed/injured in same event: At least eight others were killed according to this testimony. According to the patient, local TV reported that 40 people were injured in the hospital during the attack, but she couldn't confirm the figure.

Evacuation and care inside Gaza: The patient was initially taken to the Emergency Room (ER). Due to the attacks, all the patients in the hospital, together with their families and staff members took refuge in ER, on the ground floor. The injured from the attacks, including the patient, were then referred to Nasser Hospital in Khan Younis. There was heavy shooting on the street around them, so the trip to Nasser Hospital was difficult and dangerous. She arrived in shock at ER at Nasser Hospital, where there happened to be a foreign doctor from the European Hospital (she can't remember his name), who performed an arterioplasty (arterial reconstruction) using the saphenous vein from her right leg. The operation was successful and managed to save her arm from amputation, but a good amount of bone, nerve and muscle tissue was missing, so she was put in external fixation and sent back to Shuhada' Al Aqsa hospital on 22 Jul 2014. During the return trip the ambulance, carrying 7 patients, came under fire twice, while passing by a biscuit factory, which was completely destroyed in the course of the attack. Back in Shuhada' Al Aqsa hospital, she suffered necrosis in the muscle tissue and underwent debridement surgery. According to the patient, the piece of shrapnel extracted from her wound at Shuhada' Al Aqsa Hospital weighed almost 1kg.¹³

Evacuation out of Gaza: On 6 Aug 2014 the patient was referred to Medinat Hussein Al Tibbeya Hospital in Amman, Jordan. She was taken from the hospital to Erez Crossing in a convoy of 6 ambulances. She was very sick, in severe pain, and fainted several times during the trip. They left the hospital at 1400

¹³ See photograph of shrapnel shown to the interviewer at the hospital.

3.3 Deir Al Balah

and arrived in Amman at 2300. One of the most difficult moments of the journey was when the Israeli soldier checked her at the border (*unclear whether this is Erez Crossing or Allenby Crossing from the West Bank into Jordan -Ed.*). The soldier insisted on moving her arm and checking her bandage, and took samples from the dressing. It was extremely painful and she fainted during this process. The patient says that, like all the other patients who travelled with her, her wounds were infected by pseudomonas when she arrived at the hospital.

Comments on displacement: None

Comments on rehabilitation: The patient, whose husband was killed in the attack on the Police Academy in the attack on Gaza in 2008, is a widow with three children. She is fully responsible for them and lives independently from her relatives. It is unclear whether she will be able to work to support her children and care for them after her injury.

J8

Patient: Mousab Rafat Abd El Rahman Taher

Gender: M

Age: 22

Witness: Mousab Rafat Abd El Rahman Taher

Date of Interview: 30 Aug 2014

Location of Interview: Medinat Hussein al Tibbeya Hospital, Amman, Jordan

Interviewer/s: Alicia Vacas

Also present:

Home address: Deir Al Balah, central Gaza

Occupation: Student of Education, Al Aqsa University

Injuries: Bilateral lower limbs amputations; explosion wound of left arm with bone loss requiring external fixation; amputation of right thumb and middle finger; burns over the back and several parts of the body. Mental health: insomnia, depression, nightmares, lability.

Date/time of incident: 10 Jul 2014, 21:00

Location of incident: In the street on the way to the

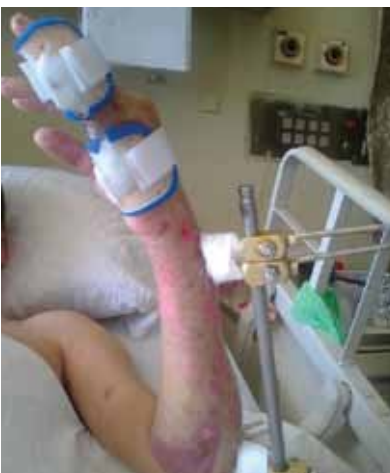
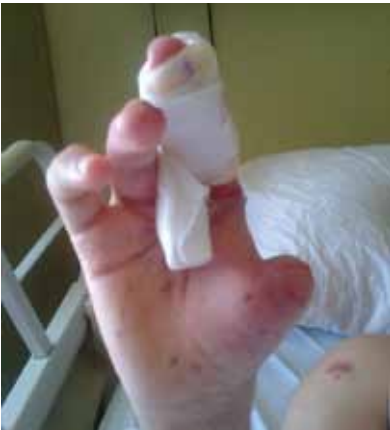
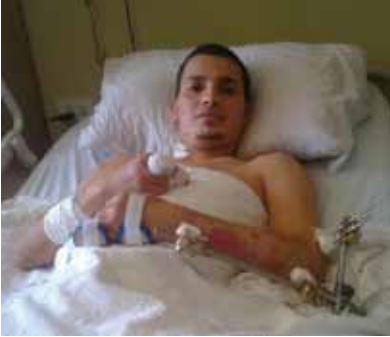Image by Alicia Vacas, Medinat Hussein Al Tibbeya Hospital, Amman, Jordan, 30 Aug 2014

3.3 Deir Al Balah

patient's local mosque in Deir Al Balah, central Gaza

Circumstances of injury: The patient was on his way to pray in the mosque after Iftar (*the daily breaking of the fast at sunset during the month of Ramadan-Ed.*), and was about 50m from his home when the incident occurred. He had decided it was safe to leave his house as the area was calm and there was no shelling. Several men were on the same street heading to the mosque when they were hit by two drone missiles. He didn't feel any danger, see any warning or suspected movement in the area; he just felt the explosion and felt his body going into pieces. Others killed/injured in same event: Others injured, details unclear.

Evacuation and care inside Gaza: The patient was found by his relatives. He was evacuated by ambulance to Shuhada' Al Aqsa Hospital in Deir Al Balah and from there was taken directly to Shifa Hospital in Gaza City due to the severity of his wounds. There was a barrage of shelling en route to [Shifa] Hospital and the transferring ambulance came under fire. It took a long time to get to the hospital. The patient was in the ICU for 3 days in Shifa Hospital and on the ward for 10 more additional days. The patient's L arm injuries required external fixation. According to the patient, doctors in Al Aqsa hospital had wanted to amputate his left arm, but the family refused because he had already suffered the amputation of both legs and two fingers of the right hand. Had the L arm been amputated, he would have remained only with three functional fingers on a single extremity.

Evacuation out of Gaza: The patient was transferred to Medinat Hussein al Tibbeya Hospital in Amman, Jordan on 23 Jul 2014, as part of a convoy of 6 ambulances, one of them an ICU ambulance. The convoy was attacked on the way and the drivers were afraid, to the point that the patient's brother, who was accompanying him, was asked by the driver to sit at the back, with the patient, in order not to be shot at from the front window. When they arrived at Erez Checkpoint the ICU car was sent back; the patient doesn't know the reason. They were still at Erez when he heard from the paramedics that the

3.3 Deir Al Balah

patient who was sent back had died in the hospital. The examination of the patients in Erez took around 2 hours. The patient was lying down on a stretcher. He couldn't turn over because of his wounds and the external fixation. He could only lie on his back, which was 'one big scar', with 2nd degree burns, and the pain became almost unbearable. The security check at Erez was difficult. Soldiers checked him for 17 minutes. The patient said that, after the amputation of his legs, his body became very small and he was naked, covered only with a bed sheet. He couldn't understand why the soldiers put him through such a long and humiliating examination. The patient was then transferred 'back-to-back' to another ambulance to take him to Jordan and during this procedure he was trembling and almost fainted due to the pain. The trip was very long. When he arrived at Medinat Hussein Al Tibbeya Hospital, it was almost midnight. He was taken to ER and his back had to be medicated.

Comments on displacement: None

Comments on rehabilitation: The patient is extremely distressed about his future. He was about to conclude his studies as a primary school teacher. He is aware that his disabilities are permanent and will not allow him to perform his profession. He said he wanted to finish his exams and graduate, in any case, but wonders what the purpose of his life would be after that, and how he will be able to support himself and build up a life on his own.

4.1 Khan Younis



EJJ5

Patient: YA [Minor; name redacted and retained at the offices of PHR-Israel]

Gender: M

Age: 16

Witness: YA

Date of Interview: 12 Aug 2014

Location of Interview: St Joseph Hospital, East Jerusalem

Interviewer/s: Alicia Vacas

Also present: The patient's uncle, Ibrahim Mustafa Al Asta

Home address: Khan Younis, southern Gaza

Occupation: N/A 10th grade student

Injuries: Multiple pieces of shrapnel in the abdomen, liver abscess; lacerations above L foot and on both arms above elbow.

Date/time of incident: 30 Jul 2014, about 06:00

Location of incident: In the back yard of the patient's home in Khan Younis, southern Gaza

Circumstances of injury: The patient went to the back yard of his home to give some food to the chickens, heard a noise like the engine of a plane, and ran inside the house. Through the window of the kitchen he saw the neighbours in the back yard of their home, thought that the situation was now safe and went out again. When he reached the door of the house, a missile hit the yard, at the entrance. He thinks that he was targeted on purpose, since there was no one else around. He thinks his life was saved by a water tank that fell upon him, acting as a cushion.

Two days later, the house was attacked again, together with his uncle's house, and both were partially destroyed.

Others killed/injured in same event: Only the patient was injured, since he was alone in the yard.

Evacuation and care inside Gaza: The patient was evacuated by his family in a private car to Nasser Hospital, where he had surgery to remove the shrapnel and close his abdominal wounds. There were complications and his situation deteriorated. He was in Nasser Hospital for 9 days, after which

4.1 Khan Younis

he was referred to East Jerusalem. Evacuation out of Gaza: The patient was transferred to St Joseph Hospital in East Jerusalem on 7 Aug 2014. He underwent 'normal procedures' at Erez Crossing. At St. Joseph Hospital, he underwent exploratory laparotomy for removal of shrapnel. He is currently receiving antibiotics and treatment according to post-surgical protocol.

Comments on displacement: The patient's house was partly destroyed.

Comments on rehabilitation: According to a medical report received subsequently the patient was discharged home in stable condition on 30 Sep 2014 with a recommendation to return in one month for re-evaluation.

The patient's father was killed in a separate incident during this conflict, on 27 July 2014, three days before the date on which the patient was injured, while going to visit his family: a drone missile hit a man walking around 30-50m away from him and the explosion killed him. The patient has relatives, but since he is the eldest of the siblings, he feels responsible for his family and to the question 'who is the care provider/responsible for the family?' he answered: 'Now, it is me, I am the eldest son, it is my duty.'



EJJ8

Patient: AR [Minor; name redacted and retained at the offices of PHR-Israel]

Gender: M

Age: 6

Witness: The patient's aunt, Iman Ahmad Najjar

Date of Interview: 12 Aug 2014

Location of Interview: St Joseph Hospital, East Jerusalem

Interviewer/s: Alicia Vacas

Also present: The patient's aunt, Iman Ahmad Najjar

Home address: Bani Suheila in Khan Younis, southern Gaza

Occupation: N/A 1st grade student

Injuries: Head trauma, shrapnel in the brain (could not be removed). Patient is conscious, eyes open, but is not

4.1 Khan Younis

responsive to verbal stimulus, not oriented. Chest tube for internal injury; diffuse shrapnel injuries; burns.

Date/time of incident: 29 Jul 2014, 22:00

Location of incident: Ali Yasser Mosque, near the patient's home in Khan Younis, southern Gaza

Circumstances of injury: The patient was injured on the first day of the Muslim holiday of 'Eid Al Fitr, in the attack on the Ali Yasser Mosque. A couple of hours before the incident in which the patient was injured, a missile hit a house near this mosque and a violent fire broke out. Firefighters went to put it out and many people gathered to watch from a distance. The group, mainly children, were standing in front of the mosque, when they were hit by a missile from an F-16 aircraft.

Others killed/injured in same event: Three people were killed, two of them the patient's cousins, and more than 50 were injured in this attack.

The patient's father and brother sustained minor injuries. The house of the patient's family is very close to the mosque so when his mother, in her 9th month of pregnancy, heard the explosion she ran towards the place. She saw the patient's body flying due to the explosion and fainted. She fell twice on her way to the incident. She started bleeding and her contractions began. She was taken to the hospital with the wounded and eventually the haemorrhage was controlled. Her baby was born next day.

Evacuation and care inside Gaza: After the dead and injured of this incident had been evacuated, and because of the chaos, the patient's family couldn't find him, either among the casualties or among the injured. They asked about him in the hospitals and eventually, at 02:00, he was found in the European Hospital in Khan Younis, registered under another name. No one in the family knows how he arrived there, who was responsible for his evacuation or how long it took to get first aid.

Evacuation out of Gaza: The patient was transferred to St Joseph Hospital in East Jerusalem on 10 Aug 2014. He left Khan Younis in a convoy of three ambulances at around 09:30. At the Beit Lahiya junction the convoy was attacked. The witness (the patient's aunt), who was with the patient, couldn't see where the attack came from, but the drivers, who were

4.1 Khan Younis

in touch via mobile phones, decided to go back to Beit Lahiya and wait there for PRCS ambulances. They waited for almost three hours until PRCS ambulances came and the group continued to Erez Crossing, where procedures were 'as usual'. At the hospital, the patient is in the ICU with chest tube and tracheotomy, undergoing wounds and burns management.

Comments on displacement: None.

Comments on rehabilitation: According to the hospital's ICU staff the patient is in a very delicate condition, his brain damage should be evaluated when he is out of danger, but he will in any case have permanent brain damage and severe disabilities after discharge. The patient's family was already very poor before the war; the father was a doorkeeper and labourer in the local municipality and they have seven children.



EJJ21

Patient: Atef Suleiman Darwish Abu Assi

Gender: M

Age: 37

Witness: The patient's brother, Muhammad Abu Assi, who was not at the incident but heard the story from the patient.

Date of Interview: 29 Jul 2014

Location of Interview: St Joseph Hospital, East Jerusalem

Interviewer/s: PHR-Israel staff

Also present: The patient's brother, Muhammad Abu Assi

Home address: Al Zanna neighbourhood, Bani Suheila, Khan Younis, southern Gaza

Occupation: Painter

Injuries: Paralysis to the left side of the body; shrapnel in chest; can't speak because of smoke in the lungs.

Date/time of incident: 24 Jul 2014

Location of incident: Outside the house of the patient's neighbour in Al Zanna, Bani Suheila, Khan Younis in southern Gaza

4.1 Khan Younis

Circumstances of injury: The patient's family had left their homes to shelter in UNRWA schools. The neighbourhood was almost empty, but the young men of the family visited their homes for two hours each day because they were afraid of burglaries/looting. The patient was on such a visit and was standing near the door to his home when a house 400m meters away from his home was hit by a missile from an F-16 aircraft. They went to this house to check if anyone had been injured when a second missile fell near them.

Others killed/injured in same event: The patient's brother and nephew (see below for detail) were killed. Others were also injured, details unclear.

Evacuation and care inside Gaza: An ambulance was called but while on its way to the area, it was forced to go back due to tank shelling. The patient waited for 15 minutes before being evacuated. The patient's brother and nephew came to the area to help with transferring the injured from the strike to the ambulance, and his brother was then also injured by shrapnel in the back. The patient's nephew transferred him and then was injured himself (fractures in the hand and the leg and shrapnel in the chest and back). The ambulance transferred the patient to the European Hospital in Khan Younis and he was immediately sent to the ICU because of cardiac arrest. He stayed in the ICU for 5 days and 2 more days on the wards before being referred to East Jerusalem.

Evacuation out of Gaza: The patient was transferred to St Joseph Hospital in East Jerusalem. The journey took one hour and 10 minutes from the hospital to Erez Crossing, 3 hours waiting before the Crossing (5 other ambulances were in front of them), and 10 minutes inside the Crossing, where the patient was checked using a scanner. After Erez Crossing, he was immediately transferred to an ambulance to take him to East Jerusalem.

Comments on displacement: Extent of damage to family home unclear.

Comments on rehabilitation: No further details provided.

4.1 Khan Younis

EJM13

Patient: Asma Abd Al Qader Muhammad Astal

Gender: F

Age: 37

Witness: The patient's aunt (uncle's wife) Fatina Al Sayed, who was not present at the incident but heard it from the patient (asleep at time of interview).

Date of Interview: 6 Aug 2014

Location of Interview: Maqassad Hospital, East Jerusalem

Interviewer/s: PHR-Israel staff, Alicia Vacas

Also present: The patient's aunt (uncle's wife) Fatina Al Sayed.

Home address: Alsater Al Gharbi, Khan Younis, southern Gaza

Occupation: Housewife. Husband is a driver

Injuries: L arm fixation; rib and hip fractures, spinal injury; abdominal bleeding; wounds in the back and R arm, larvae in the wounds to the back. Mental health: patient unable to sleep at night since the incident occurred while she was sleeping.

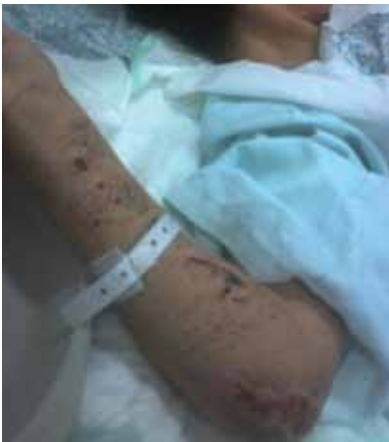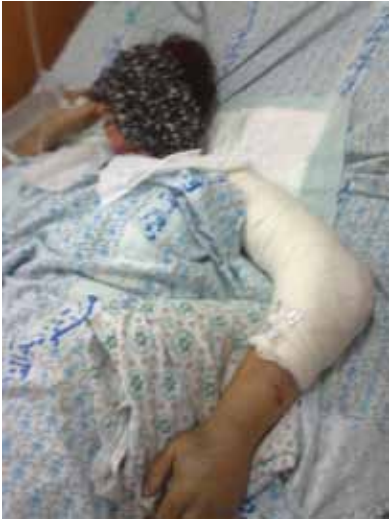Date/time of incident: 27 Jul 2014, 04:30

Location of incident: At the patient's home in Alsater Al Gharbi, Khan Younis, southern Gaza

Circumstances of injury: The patient's home is part of a three-house complex housing 1) herself, 2) her husband's second wife and 3) the son of the second wife and his own wife. All the inhabitants of the complex were together in the patient's home at the time of the incident. She was asleep when the house was hit by an airstrike. Altogether, three missiles hit the entire complex.

Others killed/injured in same event: The three others present at the complex at the time of the strike were killed; the patient is the sole survivor of the incident.

Evacuation and care inside Gaza: The patient was evacuated by ambulance, which arrived promptly and transferred her to Nasser Hospital in Khan Younis. Her abdominal injuries were repaired and she required fixation of her L arm. After these



Images by Alicia Vacas, Maqassad Hospital, East Jerusalem, 6 Aug 2014

4.1 Khan Younis

surgical procedures, she was in the ICU for four days.

Evacuation out of Gaza: On 31 Jul 2014 the patient was transferred to Augusta Victoria Hospital in East Jerusalem. She left Khan Younis in an ambulance at 09:00, arriving at Erez Crossing at 10:00. They waited for two and a half hours before being checked by the Israeli army. The patient was checked using a handheld body scanner under her clothes.

She was then transferred to an Israeli ambulance in Erez Crossing and only after that was transferred to a (Jerusalem) Palestinian ambulance to take her to East Jerusalem. During her transfer from the Israeli to the Palestinian ambulance, Israeli soldiers tried to take a photo of her but the Palestinian ambulance driver prevented it. In a place near Jerusalem she was transferred again to a different Palestinian ambulance that brought her to Augusta Victoria Hospital. She stayed there for 4 days and the wound in her back was cleaned. She was transferred to Maqassad Hospital on 4 Aug 2014 where her arm was placed in a cast.

Comments on displacement: After her release the patient will go to her parents' house as her own house is destroyed, until her husband finds a new place.

Comments on rehabilitation: According to her doctor her injury is severe and her treatment will be long, in addition to a recovery process. It is not known when she will be released from the hospital



EJM19

Patient: AS [Minor; name redacted and retained at the offices of PHR-Israel]

Gender:F

Age: 13

Witness: The patient's aunt, Sa'adia Ya'qoub, who was not present at the incident

Date of Interview: 29 Jul 2014

Location of Interview: Maqassad Hospital, East Jerusalem

Interviewer/s: PHR-Israel staff

4.1 Khan Younis

Also present: The patient's aunt, Sa'adia Ya'qoub, who was not present at the incident

Home address: Al Amal neighbourhood in Khan Younis, southern Gaza

Occupation: N/A 7th grade student

Injuries: Skull fracture; bleeding and blood clots in the brain; fractures to shoulder and hips; weakness of movement on the left side; patient was in coma until 2 days prior to interview.

Date/time of incident: 23 Jul 2014, 03:40

Location of incident: At the patient's home in Al Amal neighbourhood in Khan Younis, southern Gaza

Circumstances of injury: The patient was in the back yard of her home because there was no electricity in the house. The electricity came back on so she went inside and up the stairs to hear the news. While she was on the stairs the yard was hit by a missile from an F-16 aircraft. Immediately after that another missile hit the house itself killing her mother and brother and causing the whole building to collapse.

Others killed/injured in same event: The patient's mother and brother were killed. No details regarding injuries of others.

Evacuation and care inside Gaza: An ambulance arrived immediately but it took about one and half hours to find the patient because she was in a different place from where the rest of her family was found, it was dark, and there was a lot of dust and debris. Once found, the patient was transferred to the European Hospital in Khan Younis.

Evacuation out of Gaza: The patient was referred to Maqassad Hospital in East Jerusalem. The patient left the hospital in Gaza at 10:00 and arrived at the hospital in East Jerusalem at 16:00. The journey from the hospital to Erez Crossing, via two ambulances, was an hour long. They waited to enter Erez for a further two hours. In Erez Crossing the patient was checked using a scanner and waited for an hour to be given her permit. The soldiers asked her to go to the field hospital but they refused, and after an argument with the ambulance driver from East Jerusalem, they were released.

Comments on displacement: The home of the

4.1 Khan Younis

patient and her family was completely destroyed.

Comments on rehabilitation: Prognosis unclear but skilled rehabilitation will be necessary in any case.



EJM20

Patient: RS [Minor; name redacted and retained at the offices of PHR-Israel]

Gender: F

Age: 3

Witness: The patient's grandmother, Haniya Abd Al Rahman Shaer, who was not present at the incident.

Date of Interview: 29 Jul 2014

Location of Interview: Maqassad Hospital,
East Jerusalem

Interviewer/s: PHR-Israel staff

Also present: The patient's grandmother, Haniya Abd Al Rahman Shaer

Home address: Al Najjar, Khan Younis,
southern Gaza

Occupation: N/A

Injuries: Burns

Date/time of incident: 21 Jul 2014, during the day

Location of incident: At the home of the patient in Al Najjar, Khan Younis, southern Gaza

Circumstances of injury: During the war the patient's family were usually sleeping in another home but during the day they were in their own home. On the day of the incident, while they were at home, eight flats in their building were destroyed by an F-16 airstrike, injuring the patient and killing many. There was no warning.

Others killed/injured in same event: The patient's mother, grandfather, uncle, and a 5-year-old brother were killed. No details regarding other injuries.

Evacuation and care inside Gaza: The patient was transferred promptly by ambulance to Nasser Hospital in Khan Younis and stayed there until the evening of 28 Jul 2014

Evacuation out of Gaza: The patient was referred to Maqassad Hospital in East Jerusalem. The journey

4.1 Khan Younis

from the hospital to Erez Crossing via 2 ambulances took one hour. They waited 30 minutes to get into Erez Crossing. At Erez the patient was checked using a scanner and a body search. The procedure was 15 minutes long.

Comments on displacement: The family home is destroyed.

Comments on rehabilitation: None



WBR2

Patient: AQ [Minor; name redacted and retained at the offices of PHR-Israel]

Gender: M

Age: 17

Witness: AQ [Minor; name redacted and retained at the offices of PHR-Israel]

Date of Interview: 26 Aug 2014

Location of Interview: Abu Raya Rehabilitation Center, Ramallah, West Bank

Interviewer/s: PHR-Israel staff

Also present: The patient's brother, Amjad

Home address: Al Zanna, Beni Suheila, Khan Younis, southern Gaza

Occupation: N/A 10th grade student

Injuries: Fracture to L thigh; shrapnel in L leg, jaw and chest; burns on L hand. Mental health: flashbacks, insomnia

Date/time of incident: 29 Jul 2014, 10:30

Location of incident: In the home of the patient's uncle in Tala'at Bani Suheila near Khan Younis in southern Gaza

Circumstances of injury: The patient's family and his sister's family were living in his uncle's building and had moved from the first floor to the second floor there. He had left the building to buy a mobile phone. When he returned, on entry into the apartment, the corner of the room was hit by a drone. Before he could take another step the ceiling collapsed on top of him. His brothers were on the balcony at the time and people rescued them, but they didn't see him because he was under the rubble.

Others killed/injured in same event: Details unclear.

4.1 Khan Younis

Evacuation and care inside Gaza: The patient's family thought that someone had already taken him to the hospital and when they didn't find him in the hospital they searched for him again. He was at the site for about 30 minutes, bleeding from his side and from the mouth. He couldn't talk so when his relatives came he didn't shout but instead gripped the leg of one of them as he passed. He was then rescued and evacuated by ambulance, where he lost consciousness. When he woke up he was still in the ambulance and found his leg still raised up to his shoulders. The ambulance took another 30 minutes to get to hospital as the area came under fire and the driver had to take smaller back streets. The patient arrived at Nasser Hospital in Khan Younis and stayed there for 12 days, receiving an external fixation and wound dressings. He was then transferred to the Palestine Red Crescent Hospital for 3 more days for supervision; there, shrapnel was removed from his jaw. **Evacuation out of Gaza:** The patient was transferred to Maqassad Hospital. The ambulance waited 30 minutes before entering Erez Crossing, where he underwent a manual body search and a scanner check for 15 minutes. He was then transferred to another ambulance that took him to East Jerusalem. While at Maqassad Hospital, his external fixation was revised to internal fixation. He was hospitalized there for 10 days before being transferred to Abu Rayya Rehabilitation Centre in Ramallah, West Bank for rehabilitation. He has been here for 6 days.

Comments on displacement: The patient's home and his uncle's home are both destroyed. His brothers are now living in his married sister's homes. He may return to his sister's home after discharge. Other relatives were killed in a previous war.

Comments on rehabilitation: None available.

4.1 Khan Younis

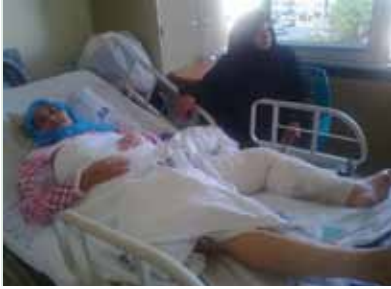

Image by Alicia Vacas, Medinat Hussein Al Tibbeya Hospital, Amman, Jordan, 30 Aug 2014

J9

Patient: Najwa Ahmad Muhammad Al Ghalban

Gender: F

Age: 39

Witness: Najwa Ahmad Muhammad Al Ghalban

Date of Interview: 30 Aug 2014

Location of Interview: Medinat Hussein Al Tibbeya Hospital, Amman, Jordan

Interviewer/s: Alicia Vacas

Home address: Al Awida Street, Khan Younis, southern Gaza

Occupation: Housewife, husband is a paramedic and ambulance driver who has not received any salary for the last 4 months

Injuries: Fracture of L tibia and fibula, with bone destruction. External fixation, several graft operations done; multiple shrapnel injuries

Date/time of incident: 23 Jul 2014

Location of incident: Outside the home of Abu Hijaza Al Ghalban, Ma'an Diwan, Khan Younis.

Circumstances of injury: The patient decided that her own house was not a safe place for the family, as there had been many attacks in the area, so she went with her children to Ma'an Diwan, the house of Abu Hijaza Al Galban. She spent a few days there and at a certain point she decided that it was time to go back to their house. Her son was supposed to take her and the family's belongings in his tok-tok (*3 wheel motor-Ed*). When they were on the street getting ready to go, an 'explosive barrel' was dropped by an F-16 aircraft. Many buildings in the street were destroyed.

Others killed/injured in same event: Seven people were killed in the attack and many others were wounded. The patient knew some of these neighbours and said they were elderly; one family had an adult disabled daughter.

Evacuation and care inside Gaza: The patient's son took her to the European Hospital in Khan Younis in the same tok-tok they had been loading with their belongings. There were many soldiers around in the streets but they 'ran away' when they saw people running to help the injured after the huge explosion. She

4.1 Khan Younis

remained in the European Hospital around 10 days. She says that the hospital was short of dressings and her leg got infected to the point that maggots started coming out of the dressing and going all around her bed. The patient's husband, a paramedic, complained about this and offered to dress her wound himself, but the answer he received was that dressings were to be changed every 5 days. Her husband then brought some materials and dressed her wound himself. A visiting medical committee from Turkey chose her to be transferred there for treatment, but for some reason the papers didn't arrive on time and her leg progressively became more swollen, painful and malodorous. She was referred to Amman, Jordan.

Evacuation out of Gaza: The patient was transferred to Medinat Hussein Al Tibbeya Hospital, Amman, Jordan, on 3 Aug 2014. She left the hospital at 14:00 in a convoy of 3 ambulances and arrived in the Jordanian hospital around midnight. She spent about one hour at the Erez Crossing. The security check was very difficult and painful. Photos were taken of her by the soldiers against her will.

Comments on displacement: The patient is supposed to return to her home in Gaza but she is extremely concerned about her family and children. Her house was hit by rockets during the attacks and has been severely damaged. All the doors have torn off their hinges and the windows are broken, but her large family doesn't have anywhere else to go. The family are now back in their home trying to make do, despite the damage.

Comments on rehabilitation: The patient faces disability in the future. She has adolescent daughters, and she is tormented by the idea of preventing her daughters from studying by asking that they assist her with the running of household matters..

4.1 Khan Younis

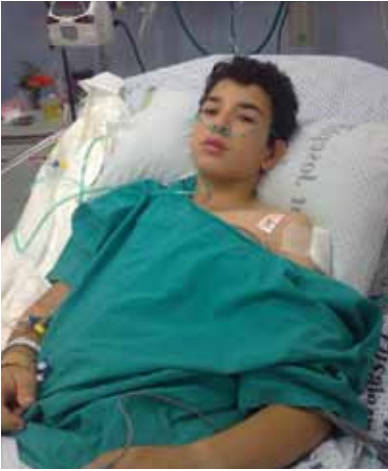

Image by Alicia Vacas, St Joseph Hospital, East Jerusalem, 2 Aug 2014

EJJ22

Patient: AA [Minor; name redacted and retained at the offices of PHR-Israel]

Gender: M

Age: 13

Witness: The patient's mother

Date of Interview: 2 Aug 2014

Location of Interview: St Joseph Hospital, East Jerusalem

Interviewer/s: PHR-Israel staff

Also present: The patient's mother and sister

Home address: Khan Younis, southern Gaza

Occupation: N/A 7th grade student

Injuries: Shrapnel in abdomen, chest, both upper extremities, left thigh and right foot. Injuries to liver, kidney and lung (hemothorax). Later developed renal failure requiring dialysis. Suffered a stroke without permanent paralysis. Had fluid drained from one lung.

Date/time of incident: 23 Jul 2014, 11:00

Location of incident: In the yard of the patient's home in Khan Younis, southern Gaza.

Circumstances of injury: The patient left his house with his father to fetch water. As they were leaving their home a missile struck the vicinity of the house, and his mother called them to leave the water and come back quickly. A second missile struck the house's yard as they were running towards the door, injuring the patient. A third missile hit the neighbours' house.

Others killed/injured in same event: The patient's father and two of his cousins were injured.

Evacuation and care inside Gaza: The patient was taken immediately to Nasser Hospital by ambulance. He was hospitalized for two days undergoing an exploratory laparotomy for removal of shrapnel fragments from his liver and insertion of chest tubes before being referred to St Joseph Hospital in East Jerusalem.

Evacuation out of Gaza: The patient was transferred to East Jerusalem on 25 Jul 2014. They were delayed at the checkpoint for an hour because the ICRC escort was delayed.

4.2 Khuza'a

Comments on displacement: None

Comments on rehabilitation: The patient is in danger of suffering long term disability stemming from his internal injuries.

Update: According to medical report received subsequently patient was discharged home on 18 Aug 2014 with request for follow up regarding kidney function and surgical follow up in Gaza.



Image by PHR-Israel, St Joseph Hospital, East Jerusalem, 2 Aug 2014

EJJ25

Patient: Tawfiq Abd Al Karim Abu Sabt

Gender: M

Age: 41

Witness:

Date of Interview: 2 Aug 2014

Location of Interview: St Joseph Hospital, East Jerusalem

Interviewer/s: PHR-Israel staff

Also present: The patient's father, Abd Al Karim Abu Sabt

Home address: Khan Younis, southern Gaza

Occupation: Computer programmer

Injuries: Loss of sight in right eye, internal bleeding in the brain, bruised right shoulder.

Date/time of incident: 24 Jul 2014, 02:00

Location of incident: In the home of the patient's relatives in Khan Younis, southern Gaza.

Circumstances of injury: The patient was staying in the home of his relatives, on the third floor of a 3-story building. The first floor was hit by an airstrike and the roof of the building, which was part-built, part zinc, collapsed and injured the patient.

Others killed/injured in same event: Two of the patient's brothers were injured.

Evacuation and care inside Gaza: The patient was evacuated promptly by ambulance to Nasser hospital. Due to the severity of his condition he was referred to St Joseph Hospital in East Jerusalem but his permit was delayed and he remained in ICU in Gaza for 4 days.

4.2 Khuza'a

Evacuation out of Gaza: The patient was transferred to East Jerusalem on 28 Jul 2014. They left Nasser Hospital at 10:30 and were held up for 4 hours at Erez Crossing. There were 9 ambulances ahead of them. They reached St Joseph Hospital at 16:00. The procedure at the Crossing itself was smooth.

Comments on displacement: None

Comments on rehabilitation: Unclear.

EJJ15

Patient: Samia Abu Daka

Gender: F

Age: 50

Witness: Samia Abu Daka and the patient's husband, Safwat Muhammad Abu Daka (both took part in the first interview as the patient was very weak and in pain).

Date of Interview: 1 Sep 2014 (first interview), 12 Nov 2014 (second interview)

Location of Interview: St Joseph Hospital, East Jerusalem (first interview); patient's home (second interview)

Interviewer/s: Alicia Vacas

Also present: The patient's husband, Safwat Muhammad Abu Daka

Home address: Abasan Al Kabir, Khan Younis, southern Gaza

Occupation: Housewife. Husband formerly a Palestinian Authority police employee. Unemployed since Hamas took power.

Injuries: Abdominal trauma from shrapnel; liver injury right lobe. Underwent two surgeries to stop liver haemorrhage and internal bleeding. At first interview, waiting for additional surgery.

Date/time of incident: 20-24 Jul 2014

Location of incident: In the home of the patient's brother in Khuza'a, Khan Younis, southern Gaza

Circumstances of injury: During the last week of Ramadan the patient went to stay with her family in Khuza'a, who were already hosting her only son (aged 9), because they felt it was safer, since her home in Abasan is very close to the border. Her



Image by Alicia Vacas, patient's home, 12 Nov 2014.'

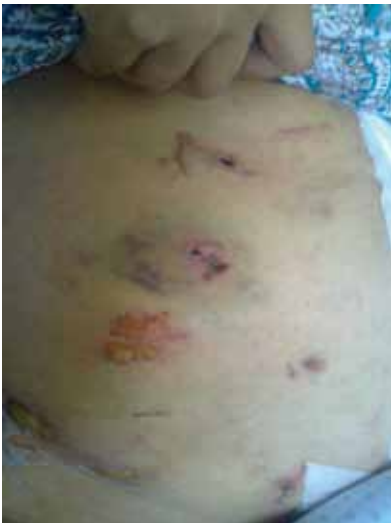

Image by Alicia Vacas, St Joseph Hospital, East Jerusalem, 1 Sep 2014

4.1 Khan Younis

husband went to Khan Younis to stay with his family. While she was in Khuza'a a rocket barrage started and the family spent three full days gathered in the kitchen, which was seen as safest place in the house. These included her elderly parents, her brother and sister-in-law with their six young children and her own son. On Tuesday 22 Jul 2014,¹⁴ young men from the neighbourhood told them that they could leave the area and walk towards Khan Younis. According to the patient around 500 people from Khuza'a set off on foot together, most of them families, women and children, holding improvised white flags made of bed sheets, clothes or even white plastic bags. There were Israeli soldiers and tanks all over the place. At a certain moment a tank gun turned towards them and the crowd stopped, terrified. Suddenly a rain of bullets fell over them. The patient said these were neither tank shells or missiles nor big explosions, just gunfire and total chaos among the people. The shooting didn't come from the tank. She couldn't see where the bullets were coming from but she thinks there were snipers in the houses around them.

Samia felt something hot in her abdomen and felt blood flowing. Her son was also wounded (three bullets scratched his shoulder) and cried at the sight of the blood. Trying to calm him, she hastened back with most of the people, holding her child with one arm and her abdomen with the other. She couldn't reach her family's house, so was taken to the primary healthcare clinic of her cousin, a private doctor¹⁵ called Kamal Qdeih Abu Rijala, for first aid. The small clinic was crowded with 60-70 people, all lying on the floor in the inner yard and at the entrance. The doctor could only clean the wound and dress it, and she was accommodated in the inner yard, on the floor, until she felt very sick and couldn't breathe. After a while she was moved to the clinic again. At that very moment some missiles hit the

¹⁴ For further descriptions of the same events see Part C. Khuza'a - focus and site visit. Based on other evidence it seems the patient remembered the date of the event and some other details inaccurately. The date of the attempted mass exodus from Khuza'a was 23, not 22 Jul 2014.

¹⁵ See Part C. 'Khuza'a - focus and site visit' for the doctor's description of the same event.

entrance and the inner yard. The patient was not injured in this attack, since she had just entered the clinic, but many of the wounded who had taken shelter in the clinic lost their lives, including the brother of the doctor, who was helping him as a volunteer. Some people said that the missile came from a drone. The clinic was clearly identified as such, with a big sign outside.

The patient was then taken by her cousins, the Abu Rijala family (*the uncle of Dr. Kamal Qdeih-Ed*), to their home, where many members of the extended family had gathered. There she remained, bleeding and with no medical assistance, for two and a half days¹⁶. Evacuation was impossible due to the heavy barrage on the area. The family took refuge in the basement. On Thursday, 24 Jul 2014 at about 10:30, the house in which the patient was sheltering was hit by a drone strike and collapsed¹⁷. About 50 members of the family, mainly women and children, were buried under the rubble. Some of the young people managed to open a way out from the basement and opened a hole to the street. The area was full of tanks and soldiers. They thought they would be attacked once again but the tanks let the people come out of the neighbourhood. As they reached the end of the street, they saw a large crowd coming towards them from the adjacent neighbourhood of Abu Reda. The two groups merged and they continued trying to reach Abasan Al Kabir. The patient described the fields on both sides of the road as full of holes, with big mountains of dirt and soil behind which many tanks were hidden. She said they took a narrow path between the fields and some chicken farms to avoid the tanks, because they were terrified of a new attack. The patient walked for 3 kilometres, helped by relatives, until they reached a point where ambulances, private cars, minibuses and even tok-toks (3-wheel motors) were waiting for them at a place behind a military

¹⁶ See note 1 above. Here too what is remembered by the patient as two and a half days was probably only one day

¹⁷ According to other testimonies the house was struck but not completely destroyed. Rather the gateway was blown up, causing damage and rubble. This could easily be perceived as destruction when experienced from inside the basement.

4.2 Khuza'a

checkpoint. According to the patient, they knew about this meeting point because some of the people in the group had been in touch with their families in Abasan by phone and had heard that ambulances were waiting.

The patient narrates with great emotion that, on their way through the tanks towards the ambulances, a small boy, aged 9 or 10, approached them crying, while holding his intestines with his hands, pleading 'take me with you, take me with you', but she was so weak and terrified herself, that they ran for their lives leaving the child behind. This scene now tortures her, and makes her feel guilty. Quote: 'He was like my son, the same age. He could have been my own son, and I left him there to die'.

Others killed/injured in same event: Multiple deaths and injuries throughout the incident, details as narrated above and in Part C. 'Khuza'a - focus and site visit'.

Evacuation and care inside Gaza: Once she reached the ambulance, the patient was evacuated to Nasser Hospital in Khan Younis, where her husband met her. The husband of the patient (the witness) provides the following details with confirmation from the patient:

At Nasser Hospital the patient underwent surgery and a CT scan was done. The doctor said that there was internal bleeding, mainly from the liver, and that they had responded with gauze for compression to stop the haemorrhage. He also said that, if coordination to refer her out of Gaza was not arranged within three days, she should have surgery again to remove the gauze. Coordination could not be facilitated in the space of time given, so surgery was performed again on 27 Jul 2014 to remove the compression material. The doctor said that further surgery would be needed due to shrapnel and extensive internal damage.

Evacuation out of Gaza: Referral to St Joseph Hospital was facilitated by the Palestinian Ministry of Health and the permits to enter East Jerusalem through Israel were provided through the intervention of the patient's former employer, the Palestinian Authority. At the hospital the patient was treated for post

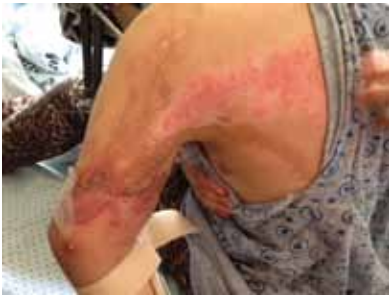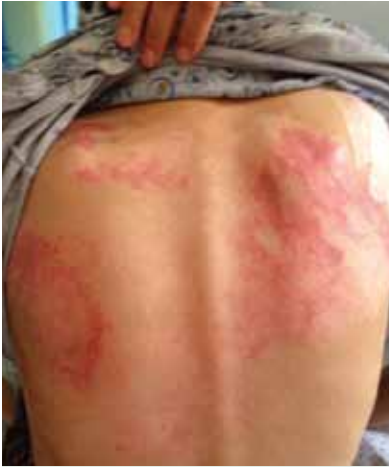4.2 Khuza'a

laparotomy status and wound infection.

Comments on displacement: The patient's family is now displaced at UN schools. The son is with his father's family at Khan Younis.

Comments on rehabilitation: None. According to a medical report received in October, the was discharged home in good condition on 5 Aug 2014.

5.1 Rafah



Images by Karen Kelly, St Joseph Hospital, East Jerusalem, 8 Sep 2014

EJJ1a/EJJ10

Patient: Iman Ayman Mahrus Siam (*cousin of patient at EJJ3/EJJ3a, see below-Ed.*)

Gender: F

Age: 19

Witness: The patient's aunt (first interview); Iman Ayman Marhus Siam (second interview)

Date of Interview: 29 Jul 2014 (first interview), 8 Sep 2014 (second interview)

Location of Interview: St Joseph Hospital, East Jerusalem

Interviewer/s: PHR-Israel staff (first interview), Jennifer Leaning, Karen Kelly (second interview)

Also present: PHR-Israel staff

Home address: Northern Rafah, southern Gaza

Occupation: N/A, 12th grade student

Injuries:

- Chest trauma requiring bilateral chest tubes
- Bilateral deep shoulder wounds
- External fixation to L upper arm with about 5cm of bone missing from humerus. Comment at second interview: issue is what type of graft or material will be provided to close the gap? Orthopaedist told patient that her L arm would, in any case, be shorter than her R.
- Right hip deep wound from shrapnel.
- R shoulder fixation with decreased ROM, deformed, and burn/skin graft. Comment at second interview: healing but will leave marked scars.
- 2nd and 3rd degree burns of her upper back. Comment at second interview: healing, disfiguring marked fresh pink keloids on L
- Mental health: PTSD

Date/time of incident: 21 July 2014, 06:30

Location of incident: Out of doors, near the home of the patient in the north of Rafah, southern Gaza

Circumstances of injury: (*Note: there is some unclarity and disparity of focus between the two interviews, but no apparent contradiction. See also testimonies regarding the patient's cousin at EJJ3/EJJ3a-Ed.*) According to the witness at the first interview (the patient's aunt), a house near the

5.1 Rafah

patient's home was struck by a missile. One man was in the house and was injured in his leg. He started walking away from the house, an ambulance arrived and people gathered around. All the people present were then hit by 2 missiles from an aircraft. According to the patient at second interview, a 'roof-knock' (warning) missile first hit the roof of her home. Glass shattered, killing the patient's cousin outright. All the inhabitants ran out of the house and a second missile from an F-16 aircraft struck the ground near the house and shrapnel hit the patient. According to the patient, an ambulance was already there because of a wounded man (*possibly the same person described as having injured his leg in an attack on his home in the first interview-Ed.*).

Others killed/injured in same event: According to the witness at first interview, 10 people were killed including 2 of the patient's brothers, 2 uncles, her uncle's wife and her uncle, leaving behind a 2-year-old orphan (*cf. testimony of patient's cousin at EJJ3a/EJJ3-Ed.*).

Evacuation and care inside Gaza: An ambulance (*additional to the one already there-Ed.*) was called for the patient but was delayed, so neighbours carried the patient to the entrance of the neighbourhood and transferred her to the ambulance. Evacuation was about 15-20 minutes after the incident. The patient was taken to Abu Yousef Al Najjar Hospital but there was no suitable equipment and she was transferred to the European Hospital in Khan Younis, where she spent 4 days. External fixation was provided as well as blood transfusions. It took 4 additional days to coordinate referral from the European Hospital to East Jerusalem.

Evacuation out of Gaza: The patient was transferred to St Joseph Hospital in East Jerusalem on 29 Jul 2014 (*the day of the first interview-Ed.*), where, according to the second interview, the external fixation was revised. She also received several additional blood transfusions. Comment at second interview: Good function of both legs, including R thigh; bends at hip and knees bilaterally.

5.1 Rafah

Comments on displacement: None

Comments on rehabilitation: At second interview: the patient will require cosmetic/plastic surgery on upper back, R shoulder and R thigh due to extensive burns and soft tissue injuries. She also needs further orthopaedic assessment to resolve difficult decisions regarding repair of her L humerus as there is insufficient bone in the area of the injury. Whether to shorten her arm considerably without bone grafting or to find some kind of material for a graft will need to be decided. She will need long-term physical therapy to recover good range of motion of both shoulders and to regain strength in both upper arms.

Update: According to a medical report received subsequently the patient was discharged home in stable condition on 19 Sep 2014 with recommendations for follow up with psychotherapy, orthopaedic management and plastic reconstructive surgery.

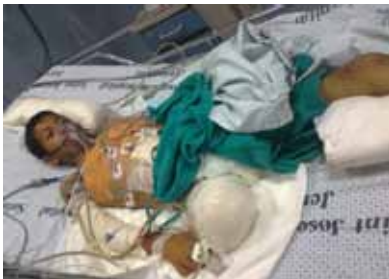

Image by Alicia Vacas, St Joseph Hospital, East Jerusalem, 2 Aug, 2014

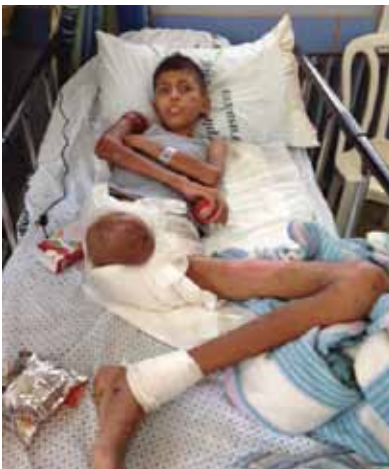

Image by Karen Kelly, St Joseph Hospital, East Jerusalem, 8 Sep 2014

EJJ3/EJJ3a

Patient: MS [Minor; name redacted and retained at the offices of PHR-Israel] (*cousin of patient at EJJ1a/EJJ10, above. Now deceased. -Ed.*)

Gender: M

Age: 14

Witness: The patient's grandfather, Suleiman (both interviews)

Date of Interview: 2 Aug 2014 (first interview), 8 Sep 2014 (second interview)

Location of Interview: St Joseph Hospital, East Jerusalem

Interviewer/s: PHR-Israel staff and Alicia Vacas (first interview), Jennifer Leaning and Karen Kelly (second interview)

Also present: The patient's grandfather, Suleiman

Home address: Rafah, southern Gaza

Occupation: N/A

Injuries:

-Bilateral hemothorax and bilateral chest drain due to shrapnel in abdomen and lung. At second

interview heavy breathing, almost stridor by sound, flaring of nostrils.

-R leg amputation very high near the hip.

-L leg fracture.

-R shoulder deep wound, deformed with skin graft, R humerus fracture; comment at second interview: healing but will require plastics repair later or will leave significant scar.

-Head trauma. At second interview: burns, scattered and small, healing, on back of head.

-Malnutrition. At second interview very thin and depressed

-Diagnosed with PTSD by hospital psychiatrist

Date/time of incident: 21 Jul 2014, 06:30

Location of incident: At the home of the patient's grandfather in Rafah, southern Gaza.

Circumstances of injury: The family was at the grandfather's house. A small house next to theirs was bombed by the army and the shockwave broke their windows. Some of them left the house when it happened, and then a bomb landed 2.5 meters from them. (*cf. testimonies at EJJ1a/EJJ10. This description is not incompatible; the difference may be in the interpretation of the first blast as either a 'roof-knock' warning strike or a shockwave from the strike on the neighbouring house-Ed.*)

Others killed/injured in same event: According to the first interview, 11 family members were killed (*cf. the testimony in EJJ1a and EJJ10 above-Ed.*), and 6 were injured - 2 are at the European Hospital in Gaza, 2 (*this patient and his cousin in testimony EJJ1a/EJJ10 above*) in St. Joseph, and 2 in Egypt.¹⁸

Evacuation and care inside Gaza: An ambulance arrived within 5 minutes, and the patient was taken to Abu Yousef al-Najjar hospital in Rafah. He was there for 30 minutes and then transferred to the European Hospital in Khan Younis, where he stayed for 3 days receiving endotracheal intubation, chest drains on both sides, laparotomy and fasciotomy of R leg.

Evacuation out of Gaza: The patient was transferred to St Joseph Hospital in East Jerusalem on 24 Jul 2014 with no delays or problems reported.

¹⁸ According to a separate forthcoming survey of Gaza injured who were referred to Egypt, a patient named Badr Siam was hospitalized at the Palestine Hospital in Cairo.

5.1 Rafah

Comments on displacement: None provided

Comments on rehabilitation: At second interview: the patient will need fitting of high prosthesis and extensive physio training in function, walking for R amputation. He lost weight between the two interviews and not taking in sufficient nutrition for good healing; definitely a problem. Breathing issues, risk of respiratory collapse. Mood is depressed and will impair recovery.

According to a medical report received subsequently the patient was discharged on 23 Sep 2014 with recommendation for psychotherapy, rehabilitation and nutritional support.

Update November 2014: Patient was later referred for chest surgery to a Turkish hospital but died there on 20 Nov 2014.



EJ6

Patient: YS [Minor; name redacted and retained at the offices of PHR-Israel] (in coma)

Gender: M

Age: 11

Witness: The patient's aunt, Hurriya Jum'a Shaluf

Date of Interview: 12 Aug 2014

Location of Interview: ICU, St Joseph Hospital, East Jerusalem

Interviewer/s: Alicia Vacas

Also present: The patient's aunt, Hurriya Jum'a Shaluf, who was not present at the incident but was in the neighbourhood at the time.

Home address: Al Baher area, Rafah, southern Gaza

Occupation: N/A

Injuries: Severe head trauma due to explosion; left frontal temporal SDH; intracerebral haemorrhage; coma; intubated, sedated and ventilated

Date/time of incident: 3 Aug 2014 about 08:30

Location of incident: At the home of the patient in Al Baher area, Rafah, southern Gaza

Circumstances of injury: The patient's 9 family members (parents and seven children) were watching TV that morning. They were having some tea and breakfast and watching the news to know what had happened during the night. There was no barrage on the area at the moment of the attack. Unexpectedly, the house was hit by a drone missile. The patient was severely wounded in the head. The witness, the patient's aunt, said that the neighbourhood was well known to the Israeli army, since there had been settlers near there in the past and many families used to work for them and have some kind of relationship with them. She thinks that the attack was not an accident, since the house was hit twice till its complete demolition (*see comments on displacement, below-Ed*).

Others killed/injured in same event: The patient's father and mother (aged 40 and 37 respectively) were killed and his 6 siblings were wounded.

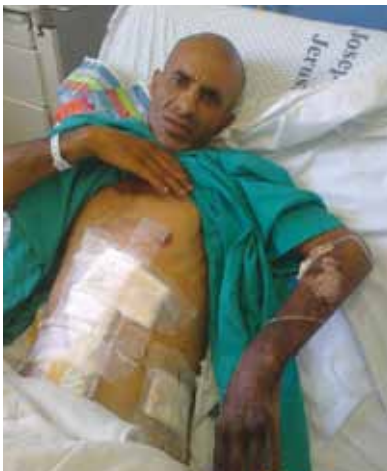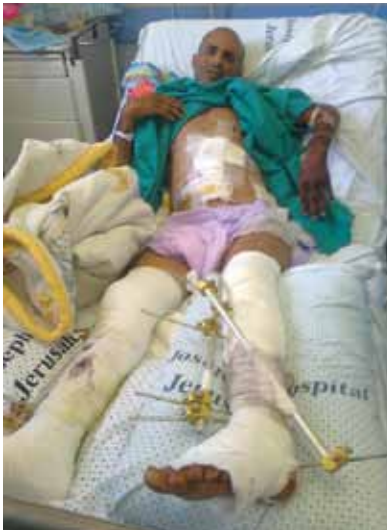Evacuation and care inside Gaza: After the strike, some neighbours gathered the bodies in blankets and fled, fearing new attacks from the drone, which was still flying over the house. About ten minutes later ambulances came and took the injured and the dead (badly mutilated) to the Emirati Hospital, where most patients were evacuated after the attack on Yousef Al Najjar Hospital¹⁹. In Emirati Hospital the staff realized immediately the gravity of his injuries and referred him to the European Hospital in Khan Younis where he remained until he was sent to St Joseph Hospital in East Jerusalem.

Evacuation out of Gaza: The patient was transferred on 10 Aug 2014 to St Joseph Hospital in East Jerusalem, passing through Erez Crossing without any issues regarding procedure. The patient remains in ICU, unconscious and ventilated.

Comments on displacement: Two days after the incident the house was shelled again and completely destroyed, so that the children, who were orphaned, are now also homeless.

¹⁹ Abu Youssef Al Najjar Hospital was attacked and damaged on 1 August 2014, evacuated on 2 Aug and re-opened on Aug 6. See <http://unispal.un.org/UNISPAL.NSF/0/61E3465681FA01A385257D2D000502615>. Patients and staff were referred to the Kuwait Specialised / Field Hospital in Rafah, or to the Hilal Emirati Maternity Hospital in Rafah.

5.1 Rafah



Images by Alicia Vacas, St Joseph Hospital, East Jerusalem, 12 Aug 2014

Comments on rehabilitation: If the patient survives he will have permanent severe brain damage with need for constant care. The patient and his siblings are orphaned and will be in care of their uncle. According to medical report provided subsequently, he was transferred in the same condition by ambulance to Shifa Hospital in Gaza City on 17 Aug 2014.

Note from interviewer: the witness, the patient's aunt, had taken refuge in the same neighbourhood with some relatives at the time. She lives in Rafah City, but there was heavy shelling in Rafah at that time, and on 1 Aug 2014 her son, who was helping as a volunteer, told her that he had buried 110 bodies with his own hands. She had thought that the Al Baher area would be safer, since the inhabitants were well known by Israel and it is a rural area. She is very emotional and traumatized, suffers from flashbacks and insomnia.

EJJ9

Patient: Akram Ahmad Awad Abu Adra

Gender: M

Age: 44

Witness: The patient's brother, Ali Ahmad Awad Abu Adra. The patient is alert but very weak. He takes part in the conversation and corrects some details while his brother relates them.

Date of Interview: 12 Aug 2014

Location of Interview: St Joseph Hospital, East Jerusalem

Interviewer/s: Alicia Vacas

Also present: The patient's brother, Ali Ahmad Awad Abu Adra

Home address: Al Shabura area, Rafah, southern Gaza

Occupation: Agricultural labourer

Injuries: Multiple, exposed fractures in both legs; shrapnel in abdomen and chest; burns

Date/time of incident: 1 Aug 2014

5.1 Rafah

Location of incident: Site of an attack in Rafah, while evacuating injured

Circumstances of injury: On the day of the incident there was heavy shelling on Rafah and ambulances couldn't enter safely to evacuate the injured and dead. The patient used his brother's tok-tok (*3 wheel motor-Ed.*) to take an old couple who had been injured mildly during the attacks to the hospital. Coming back alone in the tok-tok, he was hit by a drone missile

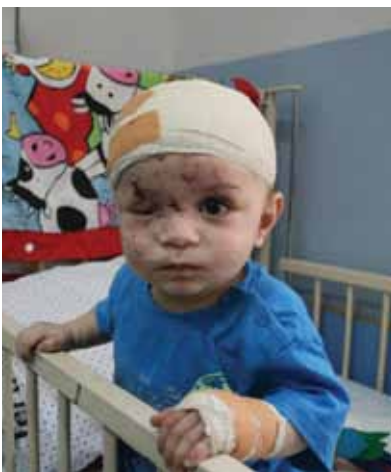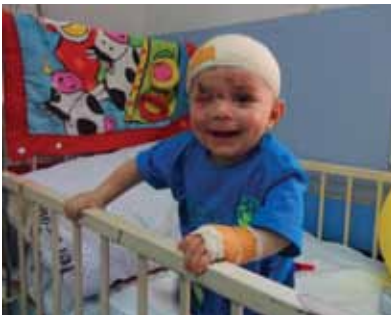Others killed/injured in same event: None

Evacuation and care inside Gaza: An ambulance arrived within 10 minutes but it was attacked by a missile from the same drone and the driver fled, leaving the vehicle. He returned after 15 minutes and evacuated the patient to the European Hospital in Khan Younis where he remained for 10 days, undergoing surgery twice.

Evacuation out of Gaza: The patient was transferred to St Joseph Hospital, East Jerusalem on 10 Aug 2014. The procedure at Erez Crossing was as usual but the security check was extremely painful as the soldiers insisted on checking him thoroughly, despite his multiple fractures.

Comments on displacement: None

Comments on rehabilitation: Extensive rehabilitation required. The patient will need nursing or nursing aid care post discharge.



'Images by Jutta Bachmann and Önder Özkalipci, St Joseph Hospital, East Jerusalem, 22 Aug 2014'

EJJ16

Patient: AD [Minor; name redacted and retained at the offices of PHR-Israel]

Gender: M

Age: 10 months old

Witness: The patient's grandmother, Sahar Abd Al Rahman Abu Taha

Date of Interview: 22 Aug 2014

Location of Interview: St Joseph Hospital, East Jerusalem

Interviewer/s: Alicia Vacas, Jutta Bachmann, Önder Özkalipci

5.1 Rafah

Also present:

Home address: A refugee camp near the Egyptian border in a densely populated area in Rafah. The area has suffered extensive destruction

Occupation: N/A

Injuries: Head trauma, maxillofacial trauma (palate reconstruction), loss of R eye, burns and shrapnel injuries of several parts of the body. Visible healing injuries on head, face, hand and legs.

Date/time of incident: 8 or 9 Aug 2014 (*testimony of witness is not clear -Ed.*)

Location of incident: In the house of the patient's relative in the patient's neighbourhood in a refugee camp in Rafah, near the Egyptian border.

Circumstances of injury: The day before the incident, on 7 Aug 2014 there were 4 explosions in the area. The patient's mother took him to seek shelter in the house of her mother-in-law (the witness, who is the patient's grandmother) a few houses away, where all members of her family and also around 20 other women and children, neighbours whose houses had been destroyed, had gathered together. From there they continued to an uncle's house in the same street. The uncle was in Jordan, but some family members were present. At the time of the attack, of the patient's family, one aunt, 2 cousins and one of the children of the cousins were present in the [uncle's] house.

A missile from an F-16 aircraft struck from above and hit the centre of their 3-story building, causing a hole going through all floors. There was no warning of the attack. The witness states that the family has no connection with 'the resistance.'

Others killed/injured in same event: Three (3) children and one woman were killed and 10 were injured. The body of the patient's sister was found with a neighbour. The patient's mother has multiple fractures and a sister was admitted to the European Hospital in Khan Younis with burns on the hands and head, and shrapnel in the head.

Evacuation and care inside Gaza: Since Abu Yousef Al Najjar Hospital had been attacked²⁰ and was

²⁰ See note 19 above

5.1 Rafah

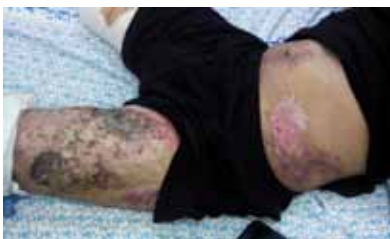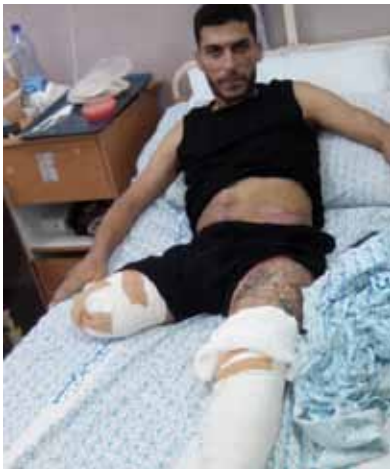evacuated, and the family thought the nearby Kuweiti Hospital not to be safe, they went to the European Hospital in Khan Younis. Form of transport not noted.

The patient stayed for 6 days in ICU, then for 2 days on the ward before his referral to East Jerusalem.

Evacuation out of Gaza: The patient was transferred to St Joseph Hospital in East Jerusalem. In total around 9 patients were referred to Jerusalem in a convoy of 8 ambulances. One other patient from the European Hospital was transferred with this patient in the same ambulance.

The transfer at Erez Crossing was by back-to-back to the other ambulance for the patients and babies, but the accompanying persons had to walk some distance to reach the ambulance on the other side. They were all checked according to 'normal' procedures. The whole transfer took about 30 minutes for this patient. There were paramedics in the ambulances on either side.

Comments on displacement: Details unclear
Comments on rehabilitation: The patient will have permanent disabilities and will need constant care after discharge.



Images by PHR-Israel, Maqassad Hospital, East Jerusalem, 10 Sep 2014

EJM3

Patient: Wael Al Namla

Gender: M

Age: 26

Witness: Wael Al Namla

Date of Interview: 10 Sep 2014

Location of Interview: Maqassad Hospital, East Jerusalem

Interviewer/s: Jennifer Leaning

Also present: PHR-Israel staff

Home address: An apartment in Rafah, southern Gaza

Occupation: Unemployed (younger brother was chief wage earner as he had a pharmacy degree)

Injuries: R leg above-the-knee traumatic

5.1 Rafah

amputation; burns on inner L and outer R arms and on abdomen; extensive burns on L leg; prior loss of consciousness for 5 days. **Comment from interviewer:** two incisions healing with pink keloids on L side and LLQ; burns healing now on his L inner arm and R outer arm and on abdomen; has significant phantom pain in his R amputated leg.

Date/time of incident: 1 Aug 2014 08:00

Location of incident: At the patient's home in Rafah, southern Gaza

Circumstances of injury: While the patients and all his family members were at home a missile hit the stairs of their building. The family's apartment remained intact. They left the building and then were hit by a drone missile.

Others killed/injured in same event: The patient's brother, sister and brother's wife were killed in the strike; his wife, son, daughter, brother and another sister were injured. His wife is currently hospitalised in Hebron in the West Bank with a bilateral amputation; his son was at Maqassad Hospital in East Jerusalem until last Sunday (7 Sep 2014-Ed.) due to a L foot amputation.

Evacuation and care inside Gaza: An ambulance arrived within 15 minutes and evacuated the children; another ambulance arrived 10 minutes later and took the patient and his wife; a third took his brother and his brother's wife (who were still alive at the time); a fourth evacuated the dead. The patient was unconscious for 5 days and has no further details regarding his time in the hospital. He did not know of the other deaths or injuries until he returned to consciousness. He was told that he had been initially evacuated to Abu Yousef Al Najjar Hospital until that hospital came under attack²¹; the ICRC then evacuated him to the European Hospital in Khan Younis where he was in ICU for 5 days receiving 16 units of blood. Someone had taken his leg and his son's foot to the hospital but these could not be re-attached. Someone retrieved his wife's two legs a week later. He was then transferred to Nasser Hospital, and from there, referred to East Jerusalem.

²¹ See note 19 above

5.1 Rafah

Evacuation out of Gaza: The patient was transferred to Maqassad Hospital in East Jerusalem. No details provided regarding procedures. In sum, he has had 5 surgeries on his R leg amputation (one in Gaza, the others at Maqassad), and is scheduled to have another next week. His L leg has had many skin grafts, and he has also undergone abdominal surgeries. He has lost at least 10kg.

Comments on displacement: None

Comments on rehabilitation: Patient's mood is sombre; he is just beginning to struggle with the situation; he and his wife are now significantly disabled and they also have one child with L leg amputation; patient is not thinking very far ahead. Short-term rehabilitation and physical therapy needs for his wife, himself, and his child are very serious, will take months if not years (for his wife), and are crucial to any kind of recovery. Two longer-term issues will pose significant hurdles to recovery:

- The patient faces heavy challenges to his mental health-grief and loss but also he was reportedly unconscious for five days and may later show signs of TBI. At time of interview there were no obvious signs of cognitive impairment or emotional instability.
- The loss of his brother, who was head of household and provider for the family, along with the greatly diminished work potential of the patient and his wife, now put them in desperate economic straits. The absence of alternative livelihood prospects will undoubtedly negatively interact with his mental health issues.



WBN2

Patient: IZ [Minor; name redacted and retained at the offices of PHR-Israel]

Gender: F

Age: 6

Witness: The patient's grandmother

Date of Interview: 13 Aug 2014

Location of Interview: Al Najah Hospital, Nablus, West Bank

5.1 Rafah

Interviewer/s: PHR-Israel staff

Also present: The patient's grandmother, who was not present at the incident

Home address: Rafah village, southern Gaza

Occupation: N/A

Injuries: Tendons of L foot cut

Date/time of incident: 28 Jul 2014, 12:00

Location of incident: In the patient's home in Rafah, southern Gaza.

Circumstances of injury: The entrance to the building where the patient's family lives was hit by a missile. The family fled to the ground floor; a second missile hit the first floor of the building, injuring the patient.

Others killed/injured in same event: Eight members of the patient's family were killed including her younger brother, uncles, cousins, and an uncle's wife. The patient's mother and four other relatives were injured and are hospitalised, some in Egypt (mother and other grandmother) and others in St Joseph Hospital, East Jerusalem.

Evacuation and care inside Gaza: No details regarding evacuation. The patient was at Nasser Hospital for one day and at the European Hospital in Khan Younis for 5 days after which she was referred to Nablus.

Evacuation out of Gaza: The patient was transferred to Al Najah Hospital in Nablus, West Bank on 2 Aug 2014. On the day of transfer the route came under fire, interrupting and delaying the journey to Erez Crossing. At Erez Crossing the ambulance waited for 1.5 hours before entering the Crossing. At the Crossing the grandmother also underwent a security check. Further details are not clear as the interview was interrupted when the grandmother had to go to tend to the patient, who was in isolation and calling for her.

Comments on displacement: Home of patient partially or completely destroyed, details unclear.

Comments on rehabilitation: Multiple members of the family were seriously injured or killed, making the patient's prospects precarious.

5.1 Rafah

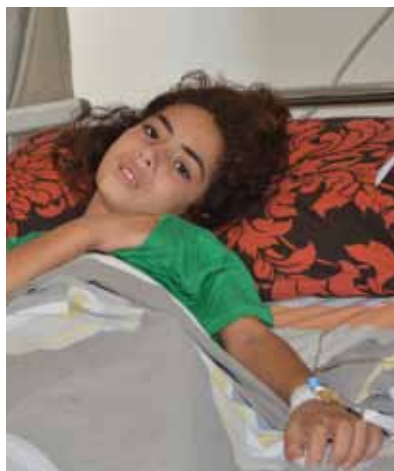

Image by PHR-Israel, Al Najah Hospital, Nablus, West Bank, 14 Aug 2014

WBN7

Patient: SB [Minor; name redacted and retained at the offices of PHR-Israel]

Gender: F

Age: 9

Witness: The patient's aunt, Maryam, 52 years old

Date of Interview: 14 Aug 2014

Location of Interview: Al Najah Hospital, Nablus, West Bank

Interviewer/s: PHR-Israel staff

Also present: The patient's aunt, Maryam

Home address: Jarash Street, Rafah, southern Gaza

Occupation: N/A

Injuries: Multiple comminuted femur fractures (from pelvis to knee) and shrapnel in tissue. The patient suffers from severe emotional symptoms, keeps crying and screaming for her mother ('ya mama'). Her crying intensified as her aunt (the witness) related the story of her injury. The witness says she screams and has nightmares when asleep.

Date/time of incident: Unknown (the witness can't remember).

Location of incident: Outside the home of the patient's uncle in Rafah, southern Gaza

Circumstances of injury: The patient was sitting outside the house of her uncle with his family, when a neighbour's house was hit. Shrapnel hit her uncle's house and caused its partial destruction. The patient was hit worst of all due to her proximity to the strike.

Others killed/injured in same event: Unclear

Evacuation and care inside Gaza: The patient was evacuated to the hospital within 30 minutes. She remained in Gaza for 8 days.

Evacuation out of Gaza: The patient was transferred to Al Najah Hospital in Nablus, West Bank, 15 days ago (31 Jul 2014-Ed.). They left the hospital in Gaza at 10:00 and arrived in Nablus at 15:00. They waited for 30 minutes before entering Erez Crossing.

Comments on displacement: The patient's home was bombed and destroyed; the entire family are sheltering in an UNRWA school.

Comments on rehabilitation: The patient will need

5.1 Rafah

care post hospital phase, mostly physical therapy. No permanent disability prediction. Regarding mental health, the patient has been receiving intensive mental healthcare but her supervisor reported she was not improving as predicted.

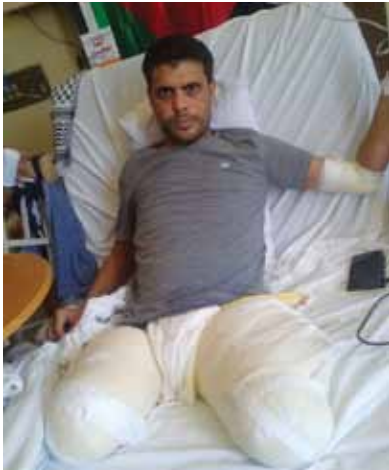

Image by Alicia Vacas, Medinat Hussein Al Tibbeya Hospital, Amman, Jordan, 30 Aug 2014

J7

Patient: Muhammad Abd El Hadi Atakkah Al Masri

Gender: M

Age: 27

Witness: Muhammad Abd El Hadi Atakkah Al Masri

Date of Interview: 30 Aug 2014

Location of Interview: Medinat Hussein Al Tibbeya Hospital, Amman, Jordan

Interviewer/s: Alicia Vacas

Also present:

Home address: A rural area in north Rafah, southern Gaza

Occupation: Nurse (unemployed)

Injuries: Bilateral above-the-knee amputation of lower limbs; left hip fracture with external fixation; 2nd degree burns over entire body. Mental health: Anxiety, insomnia, flashbacks, episodes of intense homesickness and distress.

Date/time of incident: 16 Jul 2014, 20:30

Location of incident: In the street near the patient's home in north Rafah, southern Gaza

Circumstances of injury: The patient was on his way to buy some food for his family. He was walking on the street, which was relatively calm, when he was targeted by a drone missile. According to the patient it was a single, targeted strike.

Others killed/injured in same event: None

Evacuation and care inside Gaza: The patient was helped by neighbours and evacuated promptly to Abu Yousef Al Najjar Hospital by ambulance. From there he was sent immediately to the European Hospital in Khan Younis, where he remained for 7 days. After receiving a referral to Amman, he was taken to Shifa Hospital in Gaza city for one night,

5.1 Rafah

since the convoy to Erez Crossing was due to depart from there.

Evacuation out of Gaza: On 24 Jul 2014 the patient was transferred to Medinat Hussein Al Tibbeya Hospital in Amman, Jordan. He left Shifa Hospital in a convoy of 6 ambulances. They had to wait almost 3 hours at Erez Crossing, until all the patients, companions and belongings were checked. One of the ambulances was sent back. They were still there at the Crossing when the driver of his ambulance received news from his colleague that the rejected ambulance was already back at Shifa Hospital, but the patient who had been refused at Erez had passed away shortly after their arrival.²²

Comments on displacement: None

Comments on rehabilitation: The patient is very worried and depressed about his inability to work and support his family in the future. He has a wife who can care for him but they also have a small child and his wife is due to give birth to a second in the coming days.



EJJ7

Patient: SL [Minor; name redacted and retained at the offices of PHR-Israel]

Gender: M

Age: 15

Witness: SL

Date of Interview: 12 Aug 2014

Location of Interview: St Joseph Hospital, East Jerusalem

Interviewer/s: Alicia Vacas

Also present: The patient's father

Home address: Rafah, southern Gaza

Occupation: N/A 9th grade student

Injuries: Paraplegia (intradural shrapnel at T4-T5 with complete spinal cord transection), right hemothorax, large necrotic bedsore.

Date/time of incident: 1 Aug 2014

²² Another patient interviewed by the FFM team in the same hospital recounted the same event at Erez Crossing. See JB.

5.1 Rafah

Location of incident: At the patient's home in Rafah, southern Gaza

Circumstances of injury: The patient was at home with 6 other family members when the house was hit by a single drone missile and was partially destroyed. There had been heavy shelling on Rafah, but at the moment of this attack the situation was calm.

Note from interviewer: Both the patient and his father, present during the interview, spoke in low voices and very briefly, as if they were uneasy or unwilling to cooperate.

Others killed/injured in same event: No details

Evacuation and care inside Gaza: Evacuation was delayed and took around 30 minutes, because there were many attacks on the route. The patient was taken to Nasser Hospital and remained there until 4 Aug 2014. He was then transferred to the European Hospital in Khan Younis where he remained until 10 Aug 2014, before being referred to East Jerusalem. Another patient interviewed by the FFM team in the same hospital recounted the same event at Erez Crossing. See J8.

Evacuation out of Gaza: On 10 Aug 2014 the patient was transferred to St Joseph Hospital in East Jerusalem, a process that took about 1.5 hours in total. 'Normal' security checks reported at Erez Crossing. At the hospital he underwent a CT scan and then T4-T5 laminectomy and removal of intradural shrapnel, to relieve compression of the spinal cord; right mini thoracoscopy and drainage; debridement of bedsore.

Comments on displacement: The patient's home was destroyed; the family has taken refuge with neighbours for the meantime.

Comments on rehabilitation: The patient is permanently paraplegic.

Update: Subsequent medical report stated he was discharged on 21 Aug 2014 with recommendation for referral to a rehabilitation centre, and a skin graft for the bedsore.

Testimony of injured from Gaza

All information on this form is kept confidential under medical confidentiality

Interview Setting:

Date of visit:

Name of Interviewer:

Name of Translator (if applicable):

Hospital/Place of interview:

Agreement for: publishing story photography publishing photo

Photo by:

photo name/number:

Signature affirming this agreement: Signed Waiver of Confidentiality?

YES (attach form), NO

Background on Patient

Name of patient:

Name of person that is interviewed (if the patient was unable to speak):

ID

Gender (F/M)

Age

Married (Y/N)

Contact telephone number

Residence: (location and whether that is a refugee camp, urban, or rural setting)

Occupation:

Any other sources of income besides work:

Level of education:

Number of family members (defined as those living in the same household and eating under one roof):

Was the interviewee head of a household prior to his injury?

Injury type and circumstances

Injuries (type and whether the injury will cause a permanent disability)

Any symptoms of psychosocial stress/ PTSD?

Circumstances of injury

(including dates, times, place)

Was any warning given to evacuate the building?

If so, what time interval between warning and bomb/shell/attack?

Medical evacuation

- By who, stages including time table, delays, problems, where to, to what hospital in GS and then through Erez to X, Time between injury until reached hospital in GS (indicate name of hospital):
- Problems in Erez (did they go through the field hospital, where they pressured there, signed a paper? Any of their accompanying relatives not allowed escorting them? Any other comments):
- Medical Documents (if received):

At the hospital

Current medical treatment (indicate surgeries, disabilities etc.):

Medical Documentation (reports, images):

Any fragments, bullets, etc. taken out during surgery operation?

Name of Treating Doctor:

Presence of any family members with the patient?

How are they supported?

Where is the financial support? Does he have medical insurance?

When is the patient expected to leave?

Does the patient have relatives outside Gaza?

Where will the patient go after leaving, and how will he get there?

Are there proper facilities at home

(water, sanitation accessibility to those):

Will the patient need constant healthcare for his injury post discharge?

Will the final destination of the patient have health/ mental health facilities the patient may need to access?

Will the patient have shelter/ relatives in the final destination?

Does the patient have a guaranteed family member to care for him post discharge?

If disabled, are there any special facilities

(bed, ramps, adaptation at home)?

Will the patient be able to resume his original occupation given his injury?



0599-641784

مستشفى
لدى الصبح
مستشفى لطيف زهرة
0599-463317



Appendix 2

Forensic pathology

Three forensic pathologists on the FFM teams¹ analysed 370 photographs of decedent bodies, belonging to a minimum of 75 cases. These photos were copied from Gaza's Forensics Department photo archive. The photographic samples were copied randomly and it was the conclusion of the team that they are authentic. Within the limitations of evaluating the injuries described above,² the general impression received from these photographs regarding types of injuries causing death can be described as follows:

The bodies, belonging to men, women and children, have multiple lacerations of various sizes, some have limb amputations and others have severe crush injuries. Some bodies also have severe burn injuries. The majority of the cases examined show a combination of all injury types. In some cases, the gender and age of the decedents were not identifiable (e.g., only piled separated body parts). Although the total body surfaces are not shown in any of the cases, all photos sufficient for diagnosis show wounds characteristic of explosion injuries. The patterns of the injuries do not give indications of any specific type of explosive ammunition. Among the injuries that we have seen, there were no obvious gunshot wounds³.

Conclusions:

1. The information provided by the photographs was somewhat limited by technique of examination.
2. The majority of the injuries were characteristic of explosion injuries.
3. The majority of the decedents suffered multiple injuries of various types of trauma (e.g., burns, blunt trauma and perforation injuries in a single decedent). This finding confirms the similar situation described in patients treated in hospital.
4. Several photographs demonstrated the presence of a white-gray powder material over body surfaces. It was not possible to determine whether this was detritus from collapsed buildings or some other material connected with the explosion. Therefore, the tissue samples collected and retained by the Forensics Department require further scientific evaluation.

1 Prof. Hans Petter Hougen, Dr. Karen Kelly and Dr. Önder Özkalipci

2 See Part A, 4. 'Limitations'.

3 With the exception of one possible gunshot wound, see below at DSC 02880.

Below is a selection of 6 representative cases demonstrated by specifically selected images and accompanying notes from the forensic pathologists on the FFM teams.⁴ Following these is a table summarising notes from all the images.

I. DSC 03279 (Associated images DSC 03278 - DSC 03279)

Date on sheet of paper attached to body: 22 07 2014

Gender, age unidentifiable. Piled body parts with part of right leg and torso with cloth and scalp visible.

II. DSC 03026 (Associated images DSC 03025 - DSC 03029)

Woman with long brown hair, brown eyes, approximately 35 years of age.

Extensive body damage beginning over the lateral right arm and extending onto the posterior right lower back; internal organs and intestines are visible, with very large abdominal skin flap.

Large tissue defect on middle part of left crus, almost amputated from mid-part with very extensive tissue and muscle loss; fracture of tibia and fibula visible

III. DSC 02880 (Associated images DSC 02877 - DSC 2880)

Young man, approximately in his 20s.

Large perforation injury to medial right lower leg; round defect; some small abrasions to left upper arm

IV. DSC 02821 (Associated images DSC 02812 - DSC 02821)

Date on sheet of paper attached to body: 19 07 2014

Male child, approximately 1 year old.

Possible laceration in the left temporo-frontal area (the quality of the photos impedes certain diagnosis). Blood on the left side of the face. The back and pelvic area are not shown on the photos.

V. DSC 02915 (Associated images DSC 02909 - 02917)

Man, approximately 20-30 years old.

Blood in the left ear (traumatic head injury with basilar skull fracture?). Possible abrasion/laceration of the left forehead. Marked number of shrapnel injuries of the left lower chest, left abdomen and both lower extremities.

VI. DSC 02930 (Associated images DSC 02930 - DSC 02932)

Small, young child (probably female), possibly 3 years old.

Massive head trauma with destruction of the face and skull with loss of brain.

⁴ The images themselves are not published; access is advised by special request from the Gaza Forensics Department and the Gaza Ministry of Justice.

	Photos no.	Date	Gender/age	Notes
1	DSC 02736- 02743	17.07.2014	Male ~7yrs	A small laceration on the right cheek and left chin, blood in the right ear (fracture of base of the skull?). Small lacerations on the abdomen, on the right side of the back, on the anterior right thigh, on the posterior left calf and on the anterior right calf. The back is not shown on any of the photos. Paper sheet with name on photos no. 2736, 2737, and 2740.
2	DSC 02744- 02747	17.07.2014	Female ~10yrs	Hematoma of the right upper eyelid, blood in the nostrils and over the left side of the head, abrasion in the left flank? (only partly represented in the photos). Several puncture lacerations postero-medially on the distal left thigh. A larger, oval laceration over the medial surface of the upper left calf. Several small puncture lacerations on the dorsal right foot. The back is not shown on any of the photos. Paper sheet with name on photos no. 2744 - 2747.
3	DSC 02748- 02751	17.07.2014	Male ~7yrs	An approximately two by one cm laceration beneath the left earlobe, small abrasions on the nose, two puncture lacerations on the left cheek and upper left side of the neck, one puncture laceration in the midline of the upper abdomen, two puncture lacerations in the upper lateral and lower anterior left knee, one puncture laceration distally on the lateral part of the left calf. Paper sheet with name on photos no. 2748 and 2749.
4	DSC 02753- 02757	17.07.2014	Young male	Numerous lacerations of the face, lower abdomen, arms and legs. The lacerations are rounded with a diameter varying from few millimeters to three to four centimeters. Thorax, upper abdomen, pelvic area and back not shown on any of the photos Paper sheet with name on all the photos.
5	DSC 02759- 02762	17.07.2014	Child ~3yrs	Crushed head with the skull completely open, small amounts of brain matter left. Numerous lacerations of the face and on the anterior trunk with intestines protruding through the abdominal wall. The lacerations are circular to oval, the diameter varying from few millimeters to approximately two to three centimeters. Third degree burns on the posterior part of the right arm. Back, genitals and legs are not visible on any of the photos.

	Photos no.	Date	Gender/age	Notes
6	DSC 02763- 02772	17.07.2014	Young male	Large open fracture of the right temporal skull with brain matter protruding from the fractured area. Third degree burns of the face, mainly the left side, possible open fracture of the left upper side of the face (unclear, due to poor quality of the photos). The rest of the body is not visible. Name visible on paper sheets on photos 02763 - 02768.
7	DSC 02773- 02777	18.07.2014	Young male	The right arm and shoulder are amputated. Large laceration including the right side of the thorax and abdomen. A few puncture lacerations on the mid and left side of the thorax. The left side of the body, the back, genitalia and legs are not represented on any of the photos. Photos: Poor quality. Name on paper sheet on photos 02773 - 02777.
8	DSC 02778- 02792	18.07.2014	Young male	Sutured U-formed laceration with the upper leg of the laceration along the inferior margin of the left jaw and the lower leg of the laceration on the upper left side of the neck. The total length of the sutured line is approximately 25 centimeters. Sutured incision in the midline of the abdomen from the xiphoid process to few centimeters below the umbilicus. Round approximately four centimeters diameter laceration in the right part of the abdomen at the level of the umbilicus midway between the midline and the flank. Numerous lacerations on the back and a large triangular laceration (approximately 20 by 20 cm) at the lower left side. The rest of the lacerations are round to oval, the diameter varying between a few millimeters to few centimeters. Numerous round to oval lacerations posteriorly on both calves, the diameter varying from a few millimeters to a few centimeters. Only part of the arms are visible on the photo - no injuries. Paper sheet with name on all photos, except 02787.
9	DSC 02793- 02797	19.07.2014	Male ~4yrs	Laceration in the mid frontal area. The laceration is surrounded by a horizontal excoriation, covering most of the frontal area. Laceration behind the inferior part of the right ear. Brain matter on the postero-inferior part of the head. Right arm with fracture of the mid humerus and the mid forearm. (An open skull fracture, from where the brain matter on the back of the head should originate, is not visible on the photos). No other parts of the body are visible on the photos. Paper sheet with name on all photos.

	Photos no.	Date	Gender/age	Notes
10	DSC 02798- 02801	19.07.2014	Male ~5yrs	Blood over the face, foam in the left nostril. Round laceration externally on the right knee. The back and the pelvic area are not represented in the photos. Paper sheet with name on all photos.
11	DSC 02802- 02811	19.07.2014	Female ~15yrs	Left side of the face and head partly defleshed. Right upper central incisor (tooth) is missing. The right arm is amputated at the upper part of the humerus. Laceration of entire right side of the body from the top of the shoulder to the pelvic area with exposed ribs and abdominal viscera. Back, pelvic area and thighs not shown at the photos. Paper sheet with name on all photos, except 02807.
12	DSC 02812- 02821	19.07.2014	Male ~1yr	Possible laceration in the left temporo-frontal area (the quality of the photos impedes certain diagnosis). Blood on the left side of the face. The back and pelvic area are not shown on the photos. Paper Sheet with name on all photos, except the last three.
13	DSC 02822- 02829	19.07.2014	Young male	Small laceration immediately lateral to the lateral left eye. Small amount of sand and tiny pieces of wood covering eyes, mouth, thorax and abdomen. Round lacerations with a diameter varying from a few mm to three to four centimeters on the left side of the chest and abdomen. Oval laceration approximately three by two centimeters on the lower right flank. Several centimeter wide, horizontal, oval laceration posteriorly on the left thigh. Irregular lacerations a few mm to approximately three by two centimeters medially and posteriorly on the right foot and ankle. Paper sheet with name on all photos, except the last three.
14	DSC 02831- 02847	19.07.2014	Young male	Foam in nostrils and mouth. Small sutured wound over the medial part of the right clavicle. Bandages on both arms and legs and on the abdomen. External fixation of both the right and left femur. After removal of the bandages a sutured midline incision of the abdomen is visible and several large revised wounds without skin transplantations are visible on the chest and the abdomen, both arms and both legs, especially the femurs and dorsally on both feet. The back is not shown on any of the photos. Paper sheet with name on all photos, except DSC 02837, DSC 02842 and DSC 02846.

	Photos no.	Date	Gender/age	Notes
15	DSC 02848- 02852	19.07.2014	Male ~7yrs	Lacerated wound with open skull fracture of right frontal area. Brain matter and bone splinters visible in the skull defect. Small puncture lacerations over the left side of the face, anteriorly on the neck, on the upper thorax, anteriorly on the upper right thigh and laterally on the right knee. Larger round to oval lacerated wounds externally on the right arm, left inguinal area and medially on the left calf. The back is not shown on any of the photos.
16	DSC 02853- 02857	19.07.2014	Young male	Irregular laceration at the base of the nose with open skull fracture. Small semilunar shaped, laceration in the upper left part of the frontal area. No other parts of the body are shown on the photos. Paper sheet with name on all photos, except DSC 02857.
17	DSC 02858- 02865	19.07.2014	Young male	Irregular laceration on the left side of the jaw with open jaw fracture. Small laceration on the left cheek. Blood over the face. Numerous, round to oval lacerations on both shoulders, the thorax, the abdomen and both legs. The lacerations vary in diameter from a few millimeters to several centimeters. The lower part of the right calf and the right foot are crushed. Soot on the front of the face and neck, upper thorax and both legs. The back is not shown on any of the photos. Paper sheet with name on all photos except DSC 02861 and DSC 02865.
18	DSC 02987- 02991	20.07.2014	Female, ~18-25yrs	No visible wound on face and neck. Open wound between umbilicus and pubis. Intestines protruding through the abdominal wall, very large open wound between left hip and left knee. The wound is partly covered with a black coloured substance which is consistent with burning effect of explosives.
19	DSC02992- 02996		Female, ~18-20yrs	2cm lacerated wound on inner side of right thigh 5cm above the knee joint. ~8cm diameter laceration inner side of left leg close to the ankle. Additional 3x7cm laceration close to left ankle on lateral side. No visible wound on face and neck except blood in left nostril. Large open wound on right side of the body from pubic area to abdomen with approximate dimensions of 30 x20cm, intestines protruding through the abdominal wall. Generally no bleeding on the edges of the lacerations. Paper sheet with Arabic

	Photos no.	Date	Gender/age	Notes
20	DSC02997-03004; DSC3010; DSC3011		Male, ~10yrs	~1cm diameter laceration on left orbit just below left eyelid, additional 2x3cm laceration on right side of the neck 3cm below right ear. ~15cm diameter laceration on left side of the abdomen; intestines protruding through the abdominal wall. Large laceration at right lower back on dorsal side of the body extending from right hip to mid saggital line. Edges of the wound have black colored marks consistent with burn? ~8x12cm laceration with great tissue loss on right leg Great tissue loss at the medial side of the left foot between the calcaneus and metatarsal bones. Black colour change on the wound consistent with burn. Paper sheet with Arabic
21	DSC03005-03007		?Female, ~6-7yrs	No damage on face, very large laceration covering back side of both upper thighs and left hip, extending to ventral sides of both thighs in frontal view. The skin covering the left hip and left upper thigh is avulsed from the body. On ventral side of left thigh there is a black coloured marking consistent with burn on the edges of the wound. Paper sheet with Arabic
22	DSC03008-03009	20.7.2014	?Female, ~14yrs	Large laceration on head, the skull divided into two, scalp almost totally detached from skull, brain matter protruding. Paper sheet with information in Arabic on all photos.
23	DSC03012-03014		Female, ~16-18yrs	No visible trauma on face, A large laceration starting at right side of the neck extending back and up and covering all occipital part of the head. Posterior scalp is avulsed (detached from skull). A small 0.5x2cm wound on the abdomen close to the left hip. Paper sheet with information in Arabic on all photos.
24	DSC03015-03017		Female, ~18-20yrs	Scalp avulsed from skull, parietal bones and part of brain are missing in image and part of brain is visible in the skull. Paper sheet with information in Arabic on all photos.
25	DSC03018-03024		Male, ~18yrs	Large, 8-10cm laceration at left side of the abdomen, additional 4x4cm laceration at ventral side of left knee, ~7cm long laceration on left forearm ventral side. Paper sheet with information in Arabic on all photos.

	Photos no.	Date	Gender/age	Notes
26	DSC03025-03029		Female, ~35yrs	Extensively significant body damage starting from lateral side of right arm covering entire dorsal surface to right lower back, internal organs and intestines are visible, with huge skin flap. Large tissue defect on middle part of left leg early amputated from mid part with massive tissue and muscle loss, broken tibia and fibula visible Paper sheet with information in Arabic on all photos.
27	DSC03030-03034		Female, ~30	Large laceration around the left elbow joint. On left side of the neck 3x4cm laceration and another 2x3cm laceration on back of left ankle. Paper sheet with information in Arabic on all photos. Number 184 in Latin.
28	DSC03035-03039		Female, ~30yrs	Laceration on right side of the face extending from right mandible to right zygoma with several bone fractures visible. Paper sheet with information in Arabic on all photos. Number 157 in Latin.
29	DSC03040-03041		Female, ~35yrs	Nothing identifiable in terms of any wound on the images. There is blood in the nostrils. Paper sheet with information in Arabic on all photos.
30	DSC03042-03043	20.07.2014	?Female, ~8yrs	Large laceration of left parietal scalp; L parietal bone and part of the scalp missing with nearly all of left parietal lobe of brain visible. Paper sheet with information in Arabic on all photos.
31	DSC03044-03047		Male, ~30yrs	Crush injuries of right frontal and fronto-temporal regions of the head including right zygomatic region with multiple bone fractures visible. Several abrasions on left side of the chest and abdomen. Paper sheet with information in Arabic on all photos.
32	DSC03048-03049		Female, ~35yrs	Very large wound in which abdominal wall is totally damaged, intestines are protruding through the abdominal wall. Paper sheet with information in Arabic on all photos.
33	DSC03050-03055		Male	2cm lacerations on right side of the neck just below the mandible, and lateral side of right elbow and right side of the chest in axillary line. 4cm laceration on left leg on mid tibial area. Paper sheet with information in Arabic in last three images.

	Photos no.	Date	Gender/age	Notes
34	DSC03056-03057	20.07.2014	Female, ~2yrs	Several lacerations on right hand, right side of hip. Dried substance on nostrils and mouth. Image is not clear enough to identify whether there are lacerations on face or not. Paper sheet with information in Arabic on all photos.
35	DSC03058	20.07.2014	Female, ~50yrs	No visible wound on the body; a tear on right side of her dress and color change on her undershirts. Paper sheet with information in Arabic on the photo.
36	DSC03059-03062		Female, ~7yrs	Two lacerations on right side of chest. Both legs covered with gauze dressing; amputation of right leg [above knee?] Very large 3rd degree burns on right side of face, neck and shoulders. Paper sheet with information in Arabic on all photos.
37	DSC03063-03066		Female ~8yrs	Large 5x4cm laceration on right side of the head in occipito-temporal area with brain material visible. Large ~8cm laceration on right side of the abdomen with intestines protruding through the abdominal wall. Paper sheet with information in Arabic on all photos.
38	DSC03067-03068	21.07.2014	Woman, ~20yrs	~15cm laceration on right side of abdomen with intestines protruding through the abdominal wall. Paper sheet with information in Arabic on all photos.
39	DSC03069-03070		Male, ~7yrs	Large carbonized burn on right leg, left lower leg is amputated with left thigh covered by gauze dressing. There are large 3rd degree burns on face, left side of the chest and shoulders. Information in Arabic on the body bag on the first image.
40	DSC03071-03074		Female, ~30yrs	Large laceration on left side of face extending from nose to the mandible. Several lacerations on right side of the chest and right arm and right hand. The dimensions of the lacerations range from a few mm to 2cm. Right forearm is broken. Both legs show multiple lacerations ranging from a few mm to 4 cm in length. Paper sheet with information in Arabic on all photos.

	Photos no.	Date	Gender/age	Notes
41	DSC03075-03077		Male, ~45yrs	~4m lacerations of right side of mouth and mandible. Lacerations of both sides of right forearm extending from elbow to wrist and hand, with black colored burns There are several tears on the trousers but possible wounds under these are not visible. Paper sheet with information in Arabic on all photos.
42	DSC03078-03080		Female, ~50yrs	A minimum of four small lacerations on face ranging from a few mm to 1cm in dimensions. One ~4cm laceration on left side of abdomen. Paper sheet with information in Arabic on all photos.
43	DSC03081-03083		Male	Several small lacerations on both sides of his face ranging from a few mm to 1cm in size. 10cm long laceration on left foot. Paper sheet with information in Arabic on all photos.
44	DSC03084-03086		Male	No visible wound on the body. The dark color on face and abdomen may be post mortem changes. Paper sheet with information in Arabic on all photos.
45	DSC03143	21.07.2014	Male, ~25yrs	No wound can be identified on the body, which is covered with dust and sand. Possible cause of death: asphyxia due to collapse of a building. Paper sheet with information in Arabic on the photo.
46	DSC03181	21.07.2014	Male, age unidentifiable	Large laceration on head with skull divided into two between parietal regions. Entire face is burned. There is a laceration extending from right side of the chest to left shoulder. A second, 25cm laceration on abdomen. The arms and lower extremities are not visible in the image. Paper sheet with information in Arabic.
47	DSC03184-03187	21.07.2014	Female, ~50yrs	Two 3x2cm lacerations on face over right eyebrow and over right cheek. On right arm and forearm there is large tissue loss with exposure of humerus. Upper arm attached to the forearm only by the skin. Several 1x5cm lacerations on right hip and right thigh 3rd degree burns in addition to above described lacerated wounds. Paper sheet with information in Arabic on all photos.

	Photos no.	Date	Gender/age	Notes
48	DSC03240-03243	22.07.2014	Male	Unidentifiable. Head is missing and left arm amputated, Entire abdomen is open with internal organs protruding through the abdominal wall. Paper sheet with information in Arabic on all photos.
49	DSC03261-03264		Unidentifiable	Unidentifiable. Head, both arms and parts of body missing. Only legs, abdomen and part of torso are visible. Black color change, possibly due to effect of explosion. Paper sheet with information in Arabic on all photos.
50	DSC03278-03279	22.07.2014	Unidentifiable	Unidentifiable. Pile of body parts with part of right leg and torso with cloth and scalp visible. Paper sheet with information in Arabic on all photos.
51	DSC03289		Child, 6-7yrs, gender unidentifiable	No wound visible on the image.
52	DSC02876		Male, middle age	Massive blunt force injuries (lacerations) of the face and both shoulders Possible periorbital hemorrhage
53	DSC02877-02880		Male, ~20s	Large perforation injury to medial right lower leg Round defect Also some small injuries of left upper arm
54	DSC02881-02885		Male, middle age	Amputation of right upper extremity (above the elbow) Large round perforation defect middle-upper chest Multiple large lacerations of the chest, abdomen and both lower extremities
55	DSC02886-02893		Male, middle age to slightly older	Right periorbital hemorrhage with laceration of the right forehead Large laceration of right chest Sutured incision of the mid abdomen Dressed Injuries to both lower extremities (never undressed in photos) Large, multiple lacerations of the left buttocks/hip
56	DSC02894-02895		Male, 25-30	Perforation defect/laceration of the left neck
57	DSC02896		Male	Blood over trousers; injuries not exposed by removal of clothing.

	Photos no.	Date	Gender/age	Notes
58	DSC02896-02904		Male, middle age	Covered with black, soot-like material Severe injury (burn vs blunt trauma) to the right foot Large lacerations of the lateral left thigh Burn injury of the lateral left forearm with black material Large laceration of lateral right chest Right forearm covered with black soot-like material
59	DSC02905-02908		Male, elderly	Massive trauma to the left chest and abdomen with evisceration of bowel and possible left lung
60	DSC02909-02917		Male, 20-30s	Blood in the left ear (traumatic head injury with basilar skull fracture?) Possible abrasion/laceration of the left forehead Marked number of large lacerations of the left lower chest, left abdomen, both lower extremities,
61	DSC02918-02923		Male, ~20-25	Blunt force of the right face (?burn versus abrasions/lacerations)
62	DSC02924-02929		?Male, ~30-40s	Large lacerations of the mid-chest Possible laceration below the left ear Large laceration of the posterior right forearm Hemorrhage of clothing over chest and both lower legs (not undressed)
63	DSC02930-02932		?Female, ?3yrs	Massive head trauma with destruction of the skull, including the base with loss of brain.
64	DSC02933-02934, DSC02937		Female, late 20s/ early 30s	Lacerations and abrasions of the face Possible brain matter in hair
65	DSC02935-02936		Adult, gender unidentifiable	Massive head injuries with destruction of skull and loss of brain.
66	DSC02943-02952, DSC02957-02961		Female, ~12-15 yrs and Male, ~7-10 yrs These children were on the same table	She is covered with mud-like material over her face. Complete destruction of the top of her head and skull. Collapse of her face. Possible loss of brain. Also massive disruption of the right hand and forearm. Also possible laceration of the medial right lower extremity. Covered by gray powder/dust and on clothing. He has massive destruction of his skull and face with loss of brain. Possible fracture of the right tibia/fibula. Also gray powder/dust on clothing
67	DSC02953-02954		Male, 23yrs	Possible small punctate lesions of the left face. No obvious cause of death seen in photos.

	Photos no.	Date	Gender/age	Notes
68	DSC02955-02956		Male, 29yrs	No obvious injuries, ?possible blood in right ear, ?possible horizontal bruise over the right neck
69	DSC02962-2969		Female, 39yrs	Lacerations and abrasions of the face. Large laceration of the right ear and right occipital scalp. Large lacerations/perforation injuries lateral right thigh Bruises and parchment-like abrasions of the left chest. Large laceration below the left breast Multiple smaller perforation injuries/lacerations of the right chest and arm.
70	DSC02970-02975		Male, middle age	Covered by black soot-like material and gray powder. Severe, near complete amputation of the right lower extremity at the knee. Perforations and lacerations of the left lower leg Blood in the right ear Abrasions and contusions of the right shoulder
71	DSC02976-02986		Female, ~20-30s	Massive lacerations with multiple near amputations of the right lower extremity from hip to ankle. Multiple lacerations/perforations of the left lower leg Bilateral periorbital hemorrhage Lacerations and abrasions of the face Large laceration with depressed skull defect of right skull Near-complete avulsion of the right upper extremity from the body
72	DSC 2938-2942		Male 30-40s	Man with black beard, moustache White T-shirt, black trousers and belt Abrasions of the forehead Lacerations of the posterior right forearm and possible thermal injuries (burns) Covered by dust/dirt Lower body not photographed No obvious cause of death; possible asphyxia due to building collapse.

DSC 02578; DSC 02830 invalid